This is a digital copy of a book that was preserved for generations on library shelves before it was carefully scanned by Google as part of a project to make the world's books discoverable online.

It has survived long enough for the copyright to expire and the book to enter the public domain. A public domain book is one that was never subject to copyright or whose legal copyright term has expired. Whether a book is in the public domain may vary country to country. Public domain books are our gateways to the past, representing a wealth of history, culture and knowledge that's often difficult to discover.

Marks, notations and other marginalia present in the original volume will appear in this file - a reminder of this book's long journey from the publisher to a library and finally to you.

Usage guidelines

Google is proud to partner with libraries to digitize public domain materials and make them widely accessible. Public domain books belong to the public and we are merely their custodians. Nevertheless, this work is expensive, so in order to keep providing this resource, we have taken steps to prevent abuse by commercial parties, including placing technical restrictions on automated querying.

We also ask that you:

+ *Make non-commercial use of the files* We designed Google Book Search for use by individuals, and we request that you use these files for personal, non-commercial purposes.

+ *Refrain from automated querying* Do not send automated queries of any sort to Google's system: If you are conducting research on machine translation, optical character recognition or other areas where access to a large amount of text is helpful, please contact us. We encourage the use of public domain materials for these purposes and may be able to help.

+ *Maintain attribution* The Google "watermark" you see on each file is essential for informing people about this project and helping them find additional materials through Google Book Search. Please do not remove it.

+ *Keep it legal* Whatever your use, remember that you are responsible for ensuring that what you are doing is legal. Do not assume that just because we believe a book is in the public domain for users in the United States, that the work is also in the public domain for users in other countries. Whether a book is still in copyright varies from country to country, and we can't offer guidance on whether any specific use of any specific book is allowed. Please do not assume that a book's appearance in Google Book Search means it can be used in any manner anywhere in the world. Copyright infringement liability can be quite severe.

About Google Book Search

Google's mission is to organize the world's information and to make it universally accessible and useful. Google Book Search helps readers discover the world's books while helping authors and publishers reach new audiences. You can search through the full text of this book on the web at `http://books.google.com/`

BIOLOGY
LIBRARY
G



TEXT-BOOK

OF

NORMAL HISTOLOGY:

INCLUDING

AN ACCOUNT OF THE DEVELOPMENT OF THE TISSUES AND OF THE ORGANS.

BY

GEORGE A. PIERSOL, M.D.,

PROFESSOR OF ANATOMY IN THE UNIVERSITY OF PENNSYLVANIA.

WITH FOUR HUNDRED AND NINE ILLUSTRATIONS, OF WHICH THREE HUNDRED AND FIFTY-EIGHT ARE FROM ORIGINAL DRAWINGS BY THE AUTHOR.

SEVENTH EDITION.

PHILADELPHIA AND LONDON:

J. B. LIPPINCOTT COMPANY.

1904.

QM551
P6
1904
BIOLOGY
LIBRARY
G

Copyright, 1893, by J. B. LIPPINCOTT COMPANY.

Copyright, 1899, by J. B. LIPPINCOTT COMPANY.

UNIV. OF
CALIFORNIA

ELECTROTYPED AND PRINTED BY J. B. LIPPINCOTT COMPANY, PHILADELPHIA, U.S.A.

PREFACE.

In the preparation of these pages the aim of the author has been to present descriptions which should include the salient features of the various structures with sufficient fulness to impress important details without wearying minutiæ: many years of teaching have convincingly shown that too great conciseness of statement, on the one hand, and too great elaboration of detail, on the other, are alike unsatisfactory to the student in his efforts to gain an adequate and lasting knowledge of minute anatomy.

The recognition of the underlying morphological relations of the tissues alone can bring the appreciation of the broad principles requisite for the elevation of histology from a maze of barren details to a study full of interest and suggestion. In order that these wider bearings may become apparent, a brief account of the embryological processes and the histological differentiation concerned in the development of the tissues and the organs has been added to the descriptions of the adult structures. The desirability of keeping the size and scope of the volume within the limits adapted to its primary purpose of text-book has forbidden the systematic consideration of embryological data, and much of interest relating to the earlier stages of development has been necessarily omitted.

In adopting the character of the illustrations choice has been influenced by the reflection that the mission of such drawings is instruction, and that the illustrations best accomplishing that end are of most value for the object at hand. With the exception of those taken from other, duly acknowledged sources, the drawings have been made by the author in nearly all cases with the aid of the camera lucida or from photo-micrographs. While sufficiently diagrammatic to be efficient aids in the comprehension of the text, the drawings are faithful likenesses of the original preparations; the latter as far as possible have been taken from human tissues.

258238

For manifest reasons, references and bibliography have been omitted, except in connection with statements where mention of the name of the authority has seemed desirable. The author wishes to express his obligation to the writings of Kölliker, Ranvier, Schwalbe, Waldeyer, Retzius, Stöhr, Flemming, O. Hertwig, Schaefer, Golgi, Ramón y Cajal, and others, as well as to many papers found in the *Archiv für mikroskopische Anatomie* and other journals.

G. A. P.

UNIVERSITY OF PENNSYLVANIA,
PHILADELPHIA, September 30, 1893.

CONTENTS.

CHAPTER I.

PAGES

THE CELL AND THE TISSUES 11–25

The elementary tissues;
The typical cell;
Protoplasm—arrangement and structure;
The nucleus and the nucleolus;
The paranucleus;
The centrosome and the attraction-spheres;
Vital manifestations of the cell;
Direct cell-division;
Indirect cell-division—karyokinesis;
Maturation and fecundation of the ovum;
Segmentation of the ovum;
The tissues—cellular and intercellular constituents;
The blastodermic layers and their derivatives.

CHAPTER II.

THE EPITHELIAL TISSUES 26–34

Varieties of epithelium;
Squamous epithelium;
Columnar epithelium;
Modified epithelium;
Glandular epithelium;
Neuro-epithelium;
Endothelium;
Development of epithelium;
Development of endothelium.

CHAPTER III.

THE CONNECTIVE TISSUES 35–57

Forms of connective tissue;
Cellular elements;
Intercellular constituents—white fibrous and yellow elastic tissue;
Mucoid tissue;
Tendon;
Elastic tissue;
Development of fibrous and elastic tissue;
Adipose tissue;
Hyaline cartilage;
Elastic cartilage;
Fibro-cartilage;
Development of cartilage;
Bone—spongy and compact;
Structure of compact bone;

PAGES

The periosteum;
The marrow of bone;
Development of bone;
Endochondral bone;
Periosteal bone;
Summary of bone-development.

CHAPTER IV.

THE MUSCULAR TISSUES 58-68
Non-striated muscle—distribution and structure;
Striated muscle-structure;
Arrangement of muscle-fibres;
Cardiac muscle;
Development of muscular tissue.

CHAPTER V.

THE NERVOUS TISSUES 69-82
Nerve-cells;
Nerve-fibres—structure;
Medullated nerve-fibres;
Non-medullated nerve-fibres;
Nerve-trunks—structure;
Supporting tissues of nerve-centres;
Ganglia—structure;
Development of nervous tissues.

CHAPTER VI.

THE PERIPHERAL NERVE-ENDINGS 83-93
Terminations of sensory nerves;
Special sensory nerve-endings;
Tactile cells;
Tactile corpuscles;
End-bulbs;
Nerve-endings in non-striated muscle;
Nerve-endings in striated muscle;
Nerve-endings in tendon;
Nerve-endings in blood-vessels;
Nerve-endings in glands;
Neuro-epithelium of the sense-organs.

CHAPTER VII.

THE CIRCULATORY SYSTEM 94-114
The arteries;
The veins;
The capillary blood-vessels;
The heart;
Development of the blood-vessels;
Development of the heart;
The blood;
The colorless blood-cells;
The colored blood-cells;
Effect of reagents on human blood;
Blood-crystals;
Development of the blood-corpuscles.

CHAPTER VIII.

PAGES

THE LYMPHATIC SYSTEM 115-135

The lymphatic spaces;
The lymphatic vessels;
The lymphatic tissues;
Simple lymph-follicles;
Compound lymph-glands;
The spleen;
The thymus body;
The serous membranes;
The synovial membranes;
Development of the lymphatic system;
Development of the spleen;
Development of the thymus body.

CHAPTER IX.

MUCOUS MEMBRANES AND GLANDS 136-143

Mucous membranes—structure;
Glands—varieties;
Tubular glands;
Saccular glands;
Glandular epithelium;
Glandular ducts;
Mucous glands;
Serous glands;
Changes due to functional activity;
Development of glands.

CHAPTER X.

THE DIGESTIVE TRACT 144-190

The oral cavity;
The teeth;
Development of the teeth;
The tongue;
The papillæ of the tongue;
The salivary corpuscles;
The tonsils;
The pharynx;
The œsophagus;
The stomach;
The glands of the stomach;
The intestines;
The intestinal villi;
The intestinal glands;
The glands of Lieberkühn;
The glands of Brunner;
The solitary glands;
The agminated glands, or Peyer's patches;
The liver;
The gall-bladder;
The accessory digestive glands;
The parotid gland;

PAGES

The submaxillary gland;
The sublingual gland;
The pancreas;
Development of the digestive tract;
Development of the accessory digestive glands.

CHAPTER XI.

THE URINARY ORGANS 191–206
The kidney;
The renal sinus and the ureter;
The urinary bladder;
The urethra;
Development of the urinary organs.

CHAPTER XII.

THE MALE REPRODUCTIVE ORGANS 207–223
The testicle;
Spermatogenesis;
The epididymis;
The semen;
The penis;
The prostate gland;
The glands of Cowper.

CHAPTER XIII.

THE FEMALE REPRODUCTIVE ORGANS 224–245
The ovary;
The ovum;
The escape of the ovum;
The parovarium;
The paroöphoron;
The oviduct;
The uterus;
The vagina;
The genitalia;
The glands of Bartholin;
The mammary glands;
Milk;
Development of the reproductive organs.

CHAPTER XIV.

THE RESPIRATORY ORGANS 246–260
The larynx;
The trachea;
The bronchi;
The lungs;
The pleura;
The thyroid body;
Development of the respiratory organs;
Development of the thyroid body.

CHAPTER XV.

PAGES
THE SKIN AND ITS APPENDAGES 261–281
The skin;
The nails;
The hair;
The sebaceous glands;
The sweat-glands;
Development of the skin and its appendages.

CHAPTER XVI.

THE CENTRAL NERVOUS SYSTEM 282–335
The membranes of brain and cord;
The spinal cord;
The medulla;
The pons;
The crura cerebri;
The cerebellum;
The cerebral cortex;
The hippocampus major;
The fascia dentata;
The fimbria;
The septum lucidum;
The corpus striatum;
The optic thalamus;
The corpora quadrigemina;
The olfactory lobe;
The white matter of the cerebrum;
The pituitary body;
The pineal body;
The suprarenal body;
Development of the nervous tissues.

CHAPTER XVII.

THE EYE AND ITS APPENDAGES 336–376
The cornea;
The sclera;
The choroid;
The ciliary body;
The iris;
The irido-corneal angle;
The retina;
The optic nerve and entrance;
The crystalline lens;
The vitreous body;
The blood-vessels of the eye;
The lymphatics of the eye;
The nerves of the eye;
The eyelids;
The Meibomian glands;
The conjunctiva;
The lachrymal apparatus;
The capsule of Tenon;
Development of the eye.

CHAPTER XVIII.

PAGES

THE ORGAN OF HEARING 377-401

The external ear;
The tympanic membrane;
The middle ear;
The ear-ossicles;
The Eustachian tube;
The internal ear;
The saccule and the utricle;
The semicircular canals;
The cochlea;
The ductus cochlearis;
The scala vestibuli;
The scala tympani;
The ductus endolymphaticus;
The development of the ear.

CHAPTER XIX.

THE NASAL MUCOUS MEMBRANE 402-406

The respiratory region;
The olfactory region;
Development of the nasal fossæ.

APPENDIX.

THE MOST USEFUL HISTOLOGICAL METHODS 407-429

Fixation of the tissue
Fixation reagents;
Preservation of the tissue;
Staining;
Staining solutions;
Embedding;
Interstitial embedding;
Paraffin method;
Celloidin method;
Section-cutting;
Cutting ribbon-series;
Fixing sections to the slide;
Mounting sections;
Finishing, labelling, and storing slides;
Outline of standard method;
Weigert's staining method;
Golgi's silver method;
Golgi's gold method;
Silver staining;
Staining chromatin filaments;
Injecting capillary blood-vessels.

INDEX 431

LIST OF ILLUSTRATIONS.

FIG.		PAGE
1.	Colorless blood-cell	11
2.	Typical cell—ovum of cat	12
3.	Structure of the cell	13
4.	Cells exhibiting the paranucleus (*Platner*)	14
5.	Segmenting ova of *ascaris megalocephala* (*Boveri*)	14
6.	Direct cell-division of colorless blood-corpuscle	15
7.	Karyokinesis—diagram of close skein (*Rabl-Schiefferdecker*)	16
8.	Karyokinesis—diagram of loose skein (*Rabl-Schiefferdecker*)	16
9.	Karyokinesis—diagram of polar field (*Rabl-Schiefferdecker*)	17
10.	Karyokinesis—diagram of migration of segments (*Rabl*)	18
11.	Karyokinesis—epidermal cells from larva of newt	19
12.	Segmenting ova, showing centrosomes and attraction-spheres (*Boveri*)	20
13.	Large marrow-cell with multiple nuclei	20
14.	Maturation and fecundation of ovum (*O. Hertwig*)	22
15.	Blastodermic layers of rabbit embryo	24
16.	Squamous epithelium	28
17.	Stratified squamous epithelium in section	28
18.	Isolated cells of stratified squamous epithelium	28
19.	Prickle-cells from epidermis	29
20.	Simple columnar epithelium	29
21.	Stratified columnar epithelium	29
22.	Ciliated epithelium	30
23.	Isolated elements of ciliated epithelium	30
24.	Goblet-cells	31
25.	Pigmented epithelium	31
26.	Glandular epithelium	32
27.	Rod-epithelium (*Heidenhain* and *Schiefferdecker*)	32
28.	Isolated neuro-epithelium	32
29.	Endothelium	33
30.	Endothelium showing stomata	34
31.	Young connective-tissue cell	36
32.	Embryonal connective tissue	36
33.	Subcutaneous areolar tissue	37
34.	Special connective-tissue elements	37
35.	Pigmented connective-tissue cells	37
36.	Pigment-cell	38
37.	Plate-like connective-tissue cells	38
38.	Cell-spaces of dense connective tissue	38
39.	Branched connective-tissue cells	38
40.	White fibrous tissue	39
41.	Elastic fibres isolated (*Schiefferdecker*)	39
42.	Young connective-tissue cells	40
43.	Tendon in transverse section	41

FIG.		PAGE
44.	Primary bundles of tendon	41
45.	Primary tendon-bundles in section	42
46.	Elastic fibres in transverse section	42
47.	Elastic fibres forming fenestrated membrane	42
48.	Subcutaneous tissue with fat-cells	43
49.	Hyaline (costal) cartilage	44
50.	Hyaline cartilage with perichondrium	45
51.	Elastic cartilage	46
52.	Fibro-cartilage	46
53.	Transverse section of dried bone	47
54.	Longitudinal section of dried bone	48
55.	Lacunæ and canaliculi of dried bone	48
56.	Bone-cell within lacuna	49
57.	Fragments of bone, showing Sharpey's fibres	49
58.	Cells of bone-marrow	50
59.	Primary embryonal cartilage	51
60.	Developing bone—centre of ossification	52
61.	Developing bone—zone of calcification	53
62.	Developing bone—trabeculæ of endochondral bone	54
63.	Developing bone—conversion of osteoblasts into bone-cells	54
64.	Developing bone—periosteal and endochondral bone	55
65.	Developing bone—longitudinal section of embryonal phalanx	55
66.	Developing bone—showing Howship's lacuna	56
67.	Isolated involuntary-muscle cells	59
68.	Involuntary-muscle cells	59
69.	Involuntary muscle in transverse section	60
70.	Involuntary muscle in longitudinal section	60
71.	Voluntary-muscle fibres	61
72.	Voluntary-muscle fibres in section	62
73.	Voluntary-muscle fibres	62
74.	Diagram of arrangement of contractile substance	64
75.	Muscle-fibres, showing Cohnheim's fields	65
76.	Voluntary muscle in transverse section	65
77.	Branched fibres of voluntary muscle	65
78.	Heart-muscle, showing branched fibres	66
79.	Heart-muscle fibres in section	67
80.	Injected voluntary muscle	67
81.	Developing voluntary muscle	68
82.	Nerve-cell from cerebral cortex	70
83.	Nerve-cell isolated from spinal cord	71
84.	Nerve-cell of first type	72
85.	Nerve-cell of second type	72
86.	Basket-work around Purkinje's cell	72
87.	Nerve-cell from sympathetic (*Retzius*)	73
88.	Medullated nerve-fibres	74
89.	Ultimate fibrillæ of axis-cylinder	74
90.	Medullated nerve-fibres treated with osmic acid	75
91.	Silvered nerve-fibres	75
92.	Non-medullated nerve-fibres	76
93.	Section of nerve-trunk	77
94.	Section of single funiculus of nerve	78
95.	Supporting tissues of nerve-centres	79
96.	Longitudinal section of spinal ganglion	80
97.	Section of portion of spinal ganglion	80
98.	Ganglion nerve-cell, showing spiral fibre (*Schiefferdecker*)	81

FIG.		PAGE
99.	Termination of sensory nerve fibres	83
100.	Termination of sensory nerve fibres within the epidermis	84
101.	Special nerve-endings within the epidermis (*Ranvier*)	84
102.	Tactile corpuscles—simple and compound	85
103.	Tactile corpuscle of Meissner (*Schiefferdecker*)	85
104.	Simple spherical end-bulb (*Krause*)	86
105.	Genital corpuscle (*Krause*)	86
106.	Simple cylindrical end-bulbs (*Schiefferdecker*)	86
107.	Corpuscle of Vater, or Pacinian body (*Ranvier*)	87
108.	Herbst's corpuscle	87
109.	Nerves of involuntary muscle	89
110.	Nerves of voluntary muscle	90
111.	Motor end-plate of voluntary muscle	90
112.	Golgi's corpuscle, or tendon-spindle (*Ciaccio*)	91
113.	Nerve-fibres accompanying a small artery	92
114.	Nerves ending in glands	93
115.	Section of human artery	94
116.	Endothelium of artery of frog	94
117.	Cell-spaces of intima of human aorta	95
118.	Fenestrated membrane of intima of human aorta	95
119.	Muscle-cells from human artery	96
120.	Section of aorta of child	96
121.	Small arteries and capillary	97
122.	Section of human vein	98
123.	Capillary blood-vessels	99
124.	Section of human heart, showing endocardium	100
125.	Section of human heart, including valve	101
126.	Section of human heart, including pericardium	102
127.	Developing capillary blood-vessels	103
128.	Section of developing heart	104
129.	Human colorless blood-cells	105
130.	Human blood-cells	107
131.	Red blood-cells of man and of amphiuma	109
132.	Human blood-cells, showing effects of reagents	109
133.	Human blood, showing blood-platelets, fibrin, etc.	110
134.	Hæmin crystals from human blood	111
135.	Lymph-spaces within fibrous tissue in profile	115
136.	Lymph-spaces in surface view	116
137.	Lymph-capillary	116
138.	Lymphatics of silvered diaphragm	116
139.	Perivascular lymphatic enclosing an artery	117
140.	Section of human thoracic duct	117
141.	Elements of adenoid tissue	118
142.	Diffuse adenoid tissue	119
143.	Simple lymph-follicle	119
144.	Section of lymph-gland	120
145.	Section of lymphatic gland, including cortex	120
146.	Section of lymphatic gland, including medulla	121
147.	Section of lymphatic gland, showing details of structure	121
148.	Section of spleen	123
149.	Section of spleen, showing trabeculæ and reticulum	123
150.	Section of large trabecula of spleen	123
151.	Section of human spleen cutting a Malpighian corpuscle	124
152.	Portion of channel within splenic pulp	125
153.	Diagram of relations of splenic vessels to pulp-tissue	126

FIG. PAGE
154. Section of human thymus body 127
155. Portion of periphery of follicle of thymus body 127
156. Portion of same follicle, showing Hassall's corpuscles 127
157. Peritoneal endothelium 129
158. Section of peritoneum 130
159. Section of synovial membrane 131
160. Section of ten-day rabbit embryo 133
161. Diagram of typical mucous membrane 136
162. Cells of basement-membrane 137
163. Diagram illustrating form of glands 137
164. Tubular glands 138
165. Section of racemose gland 139
166. Section of human parotid gland 139
167. Serous acini of parotid gland 140
168. Mucous acini of sublingual gland 140
169. Section of lingual glands 141
170. Serous and mucous acini of glands 141
171. Developing salivary gland 142
172. Section of human oral mucous membrane 144
173. Longitudinal section of molar tooth 146
174. Section of dried tooth, including enamel and dentine 146
175. Interglobular spaces of dentine 147
176. Section of enamel 147
177. Section of dried tooth, including cementum and dentine 148
178. Section of young tooth and pulp 149
179. Section of jaw of rabbit embryo with early dental ridge 149
180. Model of embryonal jaw (*Röse*) 150
181. Section of jaw of rabbit embryo—dental ridge 150
182. Section of jaw of rabbit embryo—enamel organ 150
183. Section of jaw of cat embryo—dental papilla 151
184. Section of jaw of cat embryo with four developing teeth 151
185. Section of enamel organ of cat embryo 152
186. Section of developing tooth of cat embryo 153
187. Section of human tongue, showing conical papillæ 154
188. Section of human tongue with fungiform papilla 154
189. Section of circumvallate papilla from child's tongue 155
190. Section of taste-bud from circumvallate papilla 155
191. Salivary corpuscles from human saliva 156
192. Section of tonsil of dog 157
193. Section of tonsil of child 157
194. Section of tonsil of child, showing structural details 158
195. Section of human œsophagus 161
196. Section of human stomach 163
197. Peptic gland from stomach of dog 163
198. Transverse sections of gastric glands of dog 164
199. Portion of peptic gland of dog 164
200. Pyloric glands from human stomach 165
201. Section of pyloric region of human stomach 165
202. Section through pylorus of child's stomach 165
203. Section of injected stomach of cat 166
204. Nervous plexuses of human stomach (*Stöhr*) 167
205. Longitudinal section of human small intestine 168
206. Tubular glands of large intestine of dog 169
207. Transverse section of follicles of large intestine 169
208. Longitudinal section of villus of dog's intestine 170

FIG. PAGE
209. Transverse section of villus of dog's intestine . . . 170
210. Longitudinal section of large intestine of child . . . 171
211. Section of duodenum of cat . . . 171
212. Section of human large intestine . . . 172
213. Peyer's patch from small intestine of cat . . . 172
214. Section of small intestine of child . . . 173
215. Section of injected small intestine of cat . . . 174
216. Section of liver of hog . . . 176
217. Section of human liver . . . 177
218. Diagram of structure of liver . . . 177
219. Section of injected human liver . . . 178
220. Hepatic cells from human liver . . . 178
221. Section of uninjected human liver . . . 178
222. Section of centre of lobule of human liver . . . 179
223. Section of liver of frog . . . 179
224. Section of rabbit's liver, showing bile-capillaries . . . 180
225. Section of dog's liver, showing interlobular vessels . . . 180
226. Transverse section of large bile-duct . . . 181
227. Section of human parotid gland . . . 183
228. Acini of human parotid gland . . . 183
229. Section of human sublingual gland . . . 184
230. Section of human pancreas . . . 185
231. Human pancreas, showing area of immature cells . . . 186
232. Section of developing gut of rabbit embryo . . . 187
233. Sagittal section of nine-day rabbit embryo . . . 188
234. Longitudinal section of human kidney (*Henle*) . . . 191
235. Section of human kidney, showing general arrangement . . . 192
236. Section of partially-injected human kidney . . . 193
237. Diagram of the kidney . . . 194
238. Uriniferous tubules of human kidney . . . 196
239. Section of kidney of amphiuma . . . 197
240. Constituents of medulla of human kidney . . . 197
241. Section of medulla of human kidney . . . 198
242. Section across papilla of human kidney . . . 199
243. Section of injected kidney of dog . . . 200
244. Transverse section of human ureter . . . 201
245. Section of human bladder . . . 202
246. Developing kidney of rabbit embryo . . . 204
247. Developing kidney of rabbit embryo . . . 205
248. Developing kidney of cow embryo . . . 205
249. Diagram illustrating structure of testicle . . . 207
250. Section of human testicle . . . 208
251. Section of human seminiferous tubule . . . 209
252. Spermatogenesis in testicle of dog . . . 209
253. Spermatogenesis in testicle of musk-rat . . . 210
254. Spermatogenesis in testicle of musk-rat . . . 210
255. Spermatogenesis in testicle of musk-rat . . . 211
256. Human testicle, showing interstitial cells . . . 211
257. Section of tubule of human epididymis . . . 212
258. Section through epididymis of child . . . 213
259. Human spermatozoa . . . 215
260. Human spermatozoa, highly magnified . . . 215
261. Section of penis of child . . . 217
262. Erectile tissue of human penis . . . 217
263. Section of human prostate gland . . . 220

FIG. PAGE
264. Human prostate gland, showing muscle . . . 221
265. Section of ovary of cat . . . 224
266. Human ovary with Graafian follicle . . . 225
267. Section of cortex of cat's ovary . . . 226
268. Ovum from ovary of cat . . . 227
269. Section of medulla of human ovary . . . 228
270. Section of corpus luteum of rabbit . . . 229
271. Portion of tubules of parovarium . . . 230
272. Transverse section of human oviduct . . . 231
273. Section of human uterus . . . 232
274. Section of uterine cervix of child . . . 233
275. Active human mammary gland . . . 238
276. Acini of active human mammary gland . . . 239
277. Afrophic human mammary gland . . . 240
278. Human milk and colostrum-corpuscles . . . 242
279. Wolffian bodies and sexual glands of rabbit embryo . . . 242
280. Indifierent sexual gland of rabbit embryo . . . 243
281. Section of developing ovary of kitten . . . 244
282. Diagram illustrating development of sexual organs . . . 245
283. Longitudinal section of larynx of child . . . 247
284. Longitudinal section of epiglottis of child . . . 248
285. Section of trachea and œsophagus of child . . . 249
286. Section of human bronchus . . . 251
287. Diagram of air-passages of lung . . . 251
288. Section of human lung . . . 252
289. Section of silvered lung of kitten . . . 253
290. Section of injected and inflated lung of cat . . . 254
291. Section of human pleura . . . 256
292. Section of thyroid body of child . . . 257
293. Acini of human thyroid body . . . 258
294. Developing pulmonary tube of rabbit embryo . . . 259
295. Developing lungs of rabbit embryo . . . 259
296. Developing thyroid body of rabbit embryo . . . 260
297. Developing lateral thyroid area of rabbit embryo . . . 260
298. Section of human skin . . . 261
299. Epidermis of human skin . . . 262
300. Section of epidermis of human skin . . . 262
301. Section of negro's skin . . . 264
302. Section of child's finger, including nail . . . 266
303. Section of human scalp . . . 267
304. Human hair . . . 268
305. Hair-follicle from human scalp . . . 269
306. Transverse sections of hair-follicles . . . 270
307. Section of hair-follicle near its mouth . . . 270
308. Section of hair-follicle, highly magnified . . . 271
309. Section of sebaceous gland from human scalp . . . 273
310. Section of human sweat-gland . . . 275
311. Developing skin from human fœtus . . . 277
312. Developing skin from fœtal kitten . . . 279
313. Developing hair from fœtal kitten . . . 279
314. Section of skin of fœtal kitten . . . 279
315. Degenerating hair-follicle from human scalp . . . 280
316. Section of skin of human fœtus . . . 281
317. Brain-membranes of child . . . 282
318. Section of human spinal cord from cervical region . . . 285

FIG. PAGE
319. Diagram of fibre-tracts of spinal cord 286
320. White matter of spinal cord 287
321. Section of human spinal cord from thoracic region 288
322. Section of human spinal cord from lumbar region 289
323. Central canal and commissures of spinal cord of calf 289
324. Anterior horn of gray matter of spinal cord of man 290
325. Anterior horn of gray matter of spinal cord of calf 291
326. Diagram of cells and fibres of spinal cord (*Lenhossék*) 292
327. Neuroglia cells of embryonal spinal cord (*Lenhossék*) 294
328. Section of injected human spinal cord 295
329. Diagram of decussations of medulla (*Testut*) 296
330. Diagram of decussating tracts of medulla (*Testut-Duval*) 297
331. Diagram of medulla through olivary bodies (*Testut-Duval*) 297
332. Diagram of sensory decussation of medulla (*Testut-Duval*) 298
333. Diagram of medulla through olivary bodies (*Testut-Duval*) 298
334. Section of medulla of child 299
335. Section through human pons (*Testut-Stilling*) 302
336. Section through human cerebral peduncle (*Krause*) 303
337. Section of human cerebellum 305
338. Diagram of nerve-cells of cerebellum 306
339. Section of human cerebellum 307
340. Section of cerebellar cortex of dog (*Retzius*) 309
341. Section of human cerebral cortex 312
342. Section of silvered human cerebral cortex 313
343. Nerve-fibres of human cerebral cortex 314
344. Section across cornu Ammonis (*Henle*) 316
345. Diagram of constituents of cornu Ammonis (*K. Schaffer*) 317
346. Section across optic thalamus (*Schwalbe-Meynert*) 320
347. Section across corpora quadrigemina (*Quain-Meynert*) 322
348. Section of human olfactory bulb (*Henle*) 324
349. Section of olfactory bulb of rabbit (*Retzius*) 325
350. Diagram of cerebral association fibres (*Schaefer-Meynert*) 326
351. Section of human pituitary body 328
352. Section of pineal sense-organ of lizard embryo 329
353. Section of human pineal body 330
354. Corpora amylacea from human brain 330
355. Section of human suprarenal body 331
356. Section of rabbit embryo, showing open neural tube 332
357. Section of rabbit embryo, showing closed neural tube 333
358. Primary wall of neural tube (*His*) 333
359. Germ-cells and neuroblasts (*His*) 333
360. Germ-cells and spongioblasts (*His*) 334
361. Spongioblasts from neural tube (*His*) 334
362. Section of human cornea 337
363. Fibrous tissue of cornea of ox 338
364. Corneal corpuscles of calf 338
365. Corneal spaces of calf 339
366. Corneal spaces of calf 339
367. Plexus of corneal nerves 340
368. Section of walls of human eyeball 341
369. Section of human choroid 342
370. Human choroid from surface 343
371. Section of human ciliary processes 344
372. Section through ciliary region of human eye 345
373. Section of iris and lens of human eye 347

FIG. PAGE
374. Injected iris from eye of dog 348
375. Irido-corneal angle of human eye 350
376. Diagram of retinal elements (Kallius after *Ramón y Cajal*) 352
377. Section of human retina 353
378. Human retina at macula lutea (*Max Schultze*) 357
379. Human retina at ora serrata 358
380. Transverse section of human optic nerve 359
381. Section of part of human optic nerve 359
382. Longitudinal section of human optic entrance 360
383. Portions of human crystalline lens 362
384. Fibres of human crystalline lens 362
385. Section through anterior segment of human eye 363
386. Section of human eyelid 368
387. Section of human lachrymal gland 371
388. Primary optic vesicle of rabbit embryo 373
389. Developing lens and optic cup of rabbit embryo 373
390. Choroidal fissure in developing eye of rabbit embryo 373
391. Developing eye of rabbit embryo 375
392. Section through developing eye of rabbit embryo 376
393. Section of human external auditory canal (*Rüdinger*) 378
394. Human tympanic membrane and malleolus (*Rüdinger*) 379
395. Section of human Eustachian tube (*Testut*) 382
396. Section of membranous labyrinth of cat 384
397. Section of utricle of rabbit, showing otoliths 385
398. Section of semicircular canal of cat 386
399. Membranous semicircular canal of cat 387
400. Longitudinal section of cochlea of guinea-pig 388
401. Section of cochlea of cat 390
402. Section of Corti's organ of guinea-pig 392
403. Diagrammatic view of Corti's organ (*Testut*) 393
404. Section through auditory pit of rabbit embryo 398
405. Section through otic vesicle of rabbit embryo 398
406. Section through developing ear of rabbit embryo 399
407. Section through developing cochlea of rabbit embryo 400
408. Section of human respiratory nasal mucous membrane 402
409. Section of olfactory mucous membrane of child 403

UNIV. OF CALIFORNIA

NORMAL HISTOLOGY.

CHAPTER I.

THE CELL AND THE TISSUES.

HISTOLOGY, literally, the science of tissues, represents that part of general morphology which treats of the structural elements of organisms, by the various arrangement of which the textures and organs of the body are formed. The term is, evidently, equally applicable to the structural components of plants as well as to those of animals; "histology," however, is usually accepted as relating especially to animal tissues, "vegetal histology" expressing the extension of the study to the tissues of plants.

At first sight apparently complex and numerous, the structures composing the animal economy are really made up of but few **elementary tissues**; these latter may be divided into four fundamental groups:

Epithelial tissues;
Connective tissues;
Muscular tissues;
Nervous tissues.

Each of these tissues may be further resolved into the component morphological constituents, the **cells** and the **intercellular substances.** All animal cells are the descendants of the embryonal elements derived from the division of the primary parent cell—the ovum; the intercellular substances, on the other hand, are formed through the more or less direct agency of the cells. The animal cell may exist in either the embryonal, matured, or metamorphosed condition.

The embryonal cell, as represented by the early generations of the direct offspring of the ovum, or by the lymphoid or colorless blood-cells of the adult, is a small irregularly round or oval mass of finely granular gelatinous substance—the **protoplasm** or cell-contents —in some part of which a smaller and often indistinct spherical body—the **nucleus**—lies embedded. In the embryonal condition,

FIG. 1.

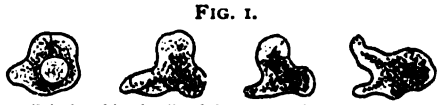

Colorless blood-cell exhibiting amœboid movement.

when the cell is without a limiting membrane and composed almost entirely of active living substance, the outlines are frequently changing, these variations in shape being known as **amœboid movements,** from their similarity to the changes observed in the outline of an active amœba, one of the simplest forms of animal life.

As the embryonal cell advances in its life-history, the surrounding conditions to which it is subjected induce, with few exceptions, further specialization. Among the earliest of such effects is the condensation of the peripheral zone of the cell, whereby the retention of a definite form is greatly favored; such peripheral condensation may progress to the production of a distinct limiting membrane —the **cell-wall.** This structure is very frequently wanting; when present, however, it is usually so thin that its optical expression is a single delicate line. The cell-wall is to be regarded as a product of the specialization of a portion of the protoplasm, rather than as an essential part of the cell.

The adult cell consists of the protoplasm, or cell-contents, possibly limited by a cell-wall, enclosing a nucleus, which latter, in turn, often contains one or more minute spherical bodies, the nucleoli. The more or less definite and characteristic forms which the elements of the various tissues possess on reaching their full development, depend largely upon the changes effected by growth and differentiation in the protoplasm during the younger condition of the cells.

FIG. 2.

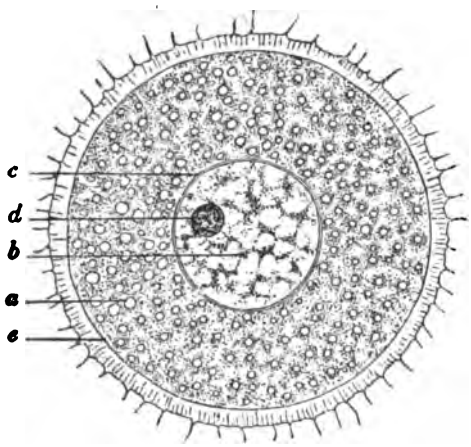

Typical cell,—ovum of cat: *a*, protoplasm; *b*, nucleus; *c*, nuclear membrane; *d*, nucleolus; *e*, true cell-wall, closely applied to the surrounding secondary envelope, the zona pellucida.

The **protoplasm** throughout the greater part of the cell usually appears as a finely granular semi-fluid or gelatinous substance, in which minute granules, the **microsomes,** as well as other particles of extraneous matters, lie embedded. The most superficial zone of the protoplasm—known as the **exoplasm**—is devoid of microsomes. The structure of protoplasm is now recognized as far more complicated than was formerly supposed, comprising a highly elastic and extensible portion—the **spongioplasm**—and an

interstitial, seemingly less active substance—the **hyaloplasm.** The active contractility which has been generally credited to the spongioplasm has been questioned (Schaefer), since the characteristic amœboid movements of living cells are by some attributed to the changes taking place within the hyaloplasm.

The arrangement of these constituents of the protoplasm is variable. When they exist closely and uniformly intermingled, the customary finely granular appearance of the cell-contents is produced; not infrequently, however, the spongioplasm is disposed as a more or less well-defined reticulum. In living cells this reticulation is transient, and, to a certain degree, accidental, since it often depends upon an unequal distribution of the hyaloplasm induced by the presence of vacuoles or of particles of foreign substance, as secretion within glandular epithelium.

FIG. 3.

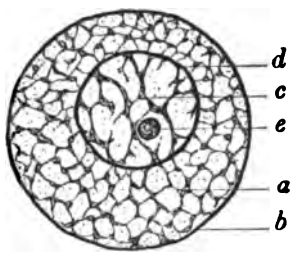

Structure of the cell: *a*, spongioplasm, arranged as reticulum, hyaloplasm lies within the latter; *b*, cell-wall; *c*, chromatin filaments, between which lies nuclear matrix; *d*, nuclear membrane; *e*, nucleolus.

Chemically, protoplasm consists of various albuminous substances in combination with a special nitrogenous proteid, **plastin,** together with water and salts. It is probable that in the albuminous substances alone the property of contractility resides; the plastin, on the other hand, offers great resistance to those reagents, as acids, gastric juices, or trypsin, which dissolve the albuminates. The amount of plastin present within the fibrils forming the intercellular reticulum is not constant, but subject to considerable variation. In addition to the hyaloplasm, the meshes of the spongioplasm frequently contain particles of foreign substances; the latter may be fatty matters, pigment granules, particles of secretion elaborated within the cell itself, or extraneous material.

The **nucleus** is usually limited by a distinct wall, the **nuclear membrane,** and is traversed by a variably elaborate framework of **nuclear fibrils,** between which lies an interfibrillar, probably semi-fluid, substance, the **nuclear matrix.** The nuclear membrane is composed of **amphipyrenin.** The nuclear fibrils consist of particles of a deeply staining proteid substance, **chromatin,** supported by delicate achromatic threads of **linin,** along which the chromatin is arranged as irregular beads or thickenings.

Suspended within the nuclear net-work, lying often in close relation with the fibrils, one or more minute spherical bodies may be seen; these are the nucleoli, regarding whose true significance, at present, little is definitely established. The **nucleolus** is highly

refracting, and, when subjected to appropriate stains, takes on a color differing from both nuclear fibrils and protoplasm; it contains a substance known as **pyrenin.** The nucleolus lies closely approximated to, but separated from, the nuclear fibrils, being especially evident in such elements as ganglionic nerve-cells, or ova, where the nucleolus appears with exceptional distinctness. Its disappearance during the division of the nucleus, and its subsequent reappearance within the newly-formed nuclei, lend weight to the supposition that the nucleolus plays but a subordinate *rôle* in the life-history of the cell; its true value, however, has yet to be determined.

In addition to the parts of the cell readily recognized, the presence of a very small, constant, round, highly-refracting body—the **centrosome**—has been established within the cytoplasm. This body is so minute and inconspicuous that it is not easily distinguished; the fact that the centrosome is itself surrounded by a clear area,

FIG. 4.

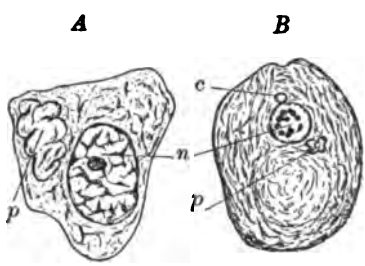

A, cell from pancreas of salamander: *n*, nucleus; *p*, paranucleus. *B*, sexual cell of leech: *n*, nucleus; *p*, paranucleus; *c*, centrosome. (After *Platner*.)

FIG. 5.

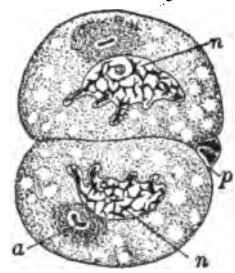

Segmenting ova of *ascaris megalocephala*: *n*, nucleus; *a*, centrosome, surrounded by attraction-sphere; *p*, polar body. (After *Boveri*.)

named the **attraction-sphere,** will often aid in its detection. While the centrosome has been shown to exist during the condition of rest, it is especially in connection with the changes incident to the division of the nucleus that it becomes most conspicuous, since its division and subsequent migration often inaugurate the complex cycle of nuclear changes.

Certain investigators have described the occasional presence of an irregularly spherical body, lying within the protoplasm in the vicinity of the nucleus, to which the name accessory nucleus, or **paranucleus** (*Nebenkern* of the Germans), has been applied. According to Platner, the paranucleus is an extrusion of the nucleus, and is subject to great variation in size and appearance; the existence, nature, and function of this body are at present still uncertain, and need further investigation.

THE VITAL MANIFESTATIONS OF THE CELL.

The characteristics which distinguish the structural units of living organisms from those of the inorganic world, may be conveniently grouped as—*Vegetative*, Metabolism, Growth, Reproduction; *Animal*, Irritability, Motion.

Metabolism is that process by which the cell selects and assimilates, from the surrounding food-materials, those substances adapted to the particular needs for its nutrition and function, so changing and incorporating into its own substance the materials so acquired that they become an integral part of the cell. By a still further exercise of this process the assimilated materials are converted into new substances, which may be retained within the cell, or, as is frequently the case, given up as the various secretions of the body.

Growth, the natural sequence of assimilation, may affect the cell equally in all parts, thereby producing a uniformly enlarged element; such normal or typical increase is, as a rule, hindered by the impression of neighboring elements, such limitations resulting in many local alterations of form, as conspicuously seen in epithelial tissues. It is, however, the principle of unequal growth that exerts the greatest influence in producing specializations of form, as examples of which the cells of muscle, the crystalline lens, or connective tissue are familiar.

Reproduction, the culminating phenomenon of the life-history of the cell, occurs by two modes:

a. By direct division—without karyokinesis.

b. By indirect division—with karyokinesis.

Direct division, by which a cell rich in protoplasm, as the white blood-corpuscle, constricts, cuts off, and sets free a portion of itself, while undoubtedly taking place in the multiplication of the simplest organisms, or of the least differentiated elements of higher types, is no longer regarded, as formerly, as the most important and usual mode of cell reproduction; the observations of the last decade have shown that its occurrence must be accepted rather as exceptional than as customary.

FIG. 6.

Direct cell-division of colorless blood-corpuscle.

Indirect division, preceded by the complicated cycle of nuclear changes collectively termed **karyokinesis,** is now recognized as being the usual mode of the reproduction of cells of all kinds, in pathological as well as in normal conditions. The recognition and elucidation of these important phenomena have been largely due to

the brilliant investigations of Flemming, Strasburger, v. Beneden, Schleicher, Rabl, and others have added much to the accurate knowledge of the life-history of the cell.

The entire process of indirect cell-division may be divided conveniently into three stages, which, however, gradually follow one another without sharp demarcation. These stages are: (1) the **Prophases,** embracing the preparatory changes of the nuclear constituents; (2) the **Metaphase,** during which the accurate division of the chromatin is effected; (3) the **Anaphases,** in which distribution and rearrangement of the newly apportioned chromatin takes place. Coincidently with the completion of the new nuclei, the cell-protoplasm undergoes division, so that each daughter-cell consists of the new nucleus surrounded by a definite area of protoplasm. These final changes constitute the **Telophases.**

FIG. 7.

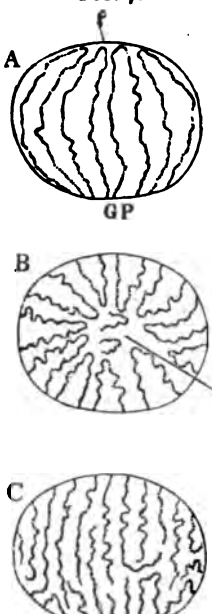

Close skein,—diagram of nuclear fibrils: *A*, seen from the side; *B*, from the polar field, *P*; *C*, from anti-pole, *GP*. (After *Rabl-Schiefferdecker*.)

FIG. 8.

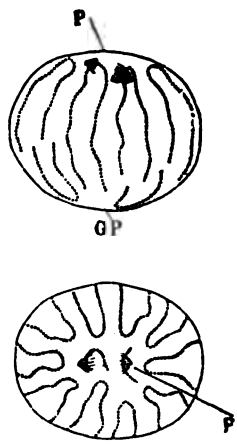

Loose skein: nuclear spindle has appeared in polar field, *P*. (After *Rabl-Schiefferdecker*.)

When the cell undergoes a complete and typical mitotic division, the following changes occur:

(1) The centrosome increases in size and, if not already existing double, divides into two; the nucleus enlarges, while the chromatin greatly increases, the fibrils becoming contorted to form a dense convolution, whose twisted threads run generally transverse to the long axis of the nucleus and parallel to the plane of the future cleavage; these fibrils constitute the

(2) **Close skein,** or spirem. The chromatin fibrils further thicken, becoming less convoluted, and forming irregularly-arranged loops, known as the

(3) **Loose skein.** The skeins, sometimes composed of the contortions of one long fibre, at others of several shorter ones, separate at their peripheral turns, so that a definite number of distinct loops, or **chromosomes,** are formed; the closed ends of these are directed

towards a common centre, around which, but removed some little distance, they become arranged. The enclosed clear space is the **polar field.**

The centrosome early undergoes division, when not already double within the cytoplasm, and lies close to the nuclear membrane. The new centrosomes, enclosed within the attraction spheres, soon begin to separate, each receding from its original position through an arc of 90° towards the opposite poles of the cell.

During the formation of the skeins and the division of the centrosomes the nuclear membrane disappears and the chromosomes lie free within the cell-protoplasm. Coincidently with the foregoing changes delicate striæ make their appearance around each centrosome, the radiating figure thus produced constituting the **amphiaster.** The rays bridging the space separating the centrosomes are so disposed that together they present a double cone, whose apices are directed towards the poles of the future new nuclei, as determined by the new centrosomes; these achromatin figures constitute the **nuclear spindle,** and occupy the polar field. The cromatin fibrils, now staining intensely, grow thicker and shorter, and arrange themselves so that the closed ends of the loops encircle the polar field, giving rise, when seen from the surface, to the wreath; seen from the side, however, the loops or V's appear as radiating fibrils, and constitute the

FIG. 9.



Rearrangement and cleavage of V-segments: *A*, from the side; *B*, from the polar field, *P*; *GP*, anti-pole. (After *Rabl-Schiefferaecker.*)

(4) **Mother-star,** or aster: the apparent differences, therefore, between the wreath and the aster depend upon the point of view, and not upon variations in the arrangement of the fibres. The completion of these preparatory changes marks the termination of the prophases; the succeeding metaphase is initiated by an important change leading to the reapportionment of the chromatin.

(5) Each of the loops, or chromosomes, undergoes **longitudinal cleavage,** splitting up into double the number of segments: these are now entirely rearranged during the anaphases, the first step being

(6) A rapid separation into two groups, passing towards the poles of the future new nuclei, as indicated by the foci of the nuclear spindle. Around these points as centres, a delicate radial marking—the **polar striation**—appears. The halves of the longitudinally cleft fibrils are so disposed that one of each pair of sister-segments passes along the guiding lines of the

achromatin spindle to each of the groups, thus insuring an accurate and equal division of the original chromatin between the new nuclei. The chromatic segments, becoming further aggregated about the equator of the nuclear spindle in their migration, form a compressed mass, known as the

(7) **Equatorial plate.*** As the newly-grouped fibrils pass outward towards their respective poles, the free ends of the receding segments become united by delicate threads of achromatin—the **connecting filaments**—which stretch between the corresponding limbs of the separating segments. With the completion of migration the cardinal features of the division of the nucleus have been established, since the anaphases are but repetitions, in inverse order, of the changes already instituted. Following the stage of the equatorial plate, the fibrils group themselves about the poles of the spindle and form

FIG. 10.

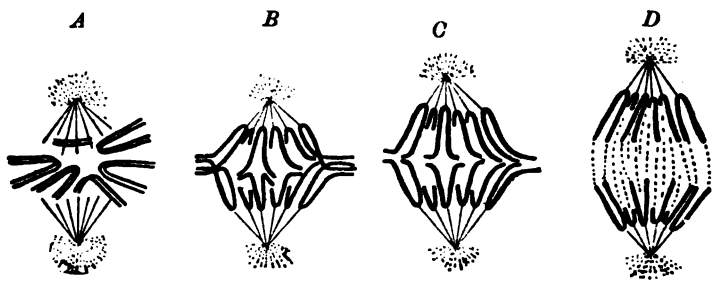

Diagram illustrating the migration and redisposition of the segments of chromatin, guided by the achromatic lines: *A*, mother-star; *B* and *C*, stage of equatorial plate; *D*, daughter-stars. (After *Rabl.*)

(8) The **daughter-stars,** or diaster, each of these corresponding to a new nucleus. About this time the cell-protoplasm, which until now has been almost passive, begins to exhibit a constriction of its body, which impression now steadily progresses until the protoplasm of the cell completely separates into the portions destined to become the bodies of the cells, enveloping the new nuclei. The karyokinetic cycle is completed by each

(9) Daughter-wreath or star in turn assuming

(10) The stage of the daughter-skeins, at first loose and afterwards close; on obtaining nuclear membranes and the nucleoli reappearing, the new nuclei finally pass into the stage of rest.

* The term "equatorial plate" has been employed by some authors to indicate the later phases of the aster stage.

In recapitulation, the above changes may be tabulated as follows:

Resting Mother-Nucleus.

Prophases:

The inauguration of division is marked by migration and division of centrosome, increase of chromatin, resulting in the formation of

The Mother-Skein (*Spirem*):

a. Close skein,—

Disappearance of nucleoli.

Disappearance of nuclear membrane.

FIG. 11.

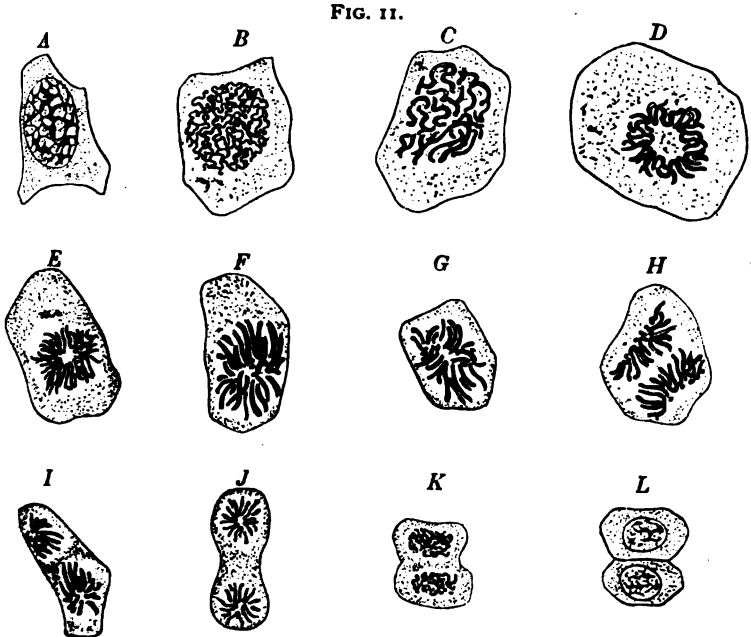

Cells from the epidermis of very young larva of newt: *A*, resting nucleus; *B*, close skein; *C*, loose skein; *D* and *E*, mother-stars, seen from the polar field and appearing as the wreath stage; *F*, mother-star from the side; *G*, migration of segments; *H*, daughter-stars; *I* and *J*, segments grouped about new polar fields (in *J* the protoplasm exhibits constriction); *K*, daughter-skeins,—division of nucleus complete with slight constriction of cell-body; *L*, completed division of nucleus and protoplasm.

b. Loose skein,—

Separation of skein into segments or chromosomes.

Appearance of polar field around the centrosomes.

Rearrangement of chromosomes around polar field.

The Mother-Wreath, or Aster:

Appearance of nuclear spindle.

Metaphase:

Longitudinal cleavage of chromatin segments.

Anaphases:

Migration of segments (*Metakinesis*).
Segments pass towards the poles of the new nuclei.
Equatorial plate produced by massing of migrating segments.
Separation of segments into polar groups.
Appearance of connecting filaments.

Daughter-Wreaths, or Asters.

Telophases:

Beginning division of cell-protoplasm.

Daughter-Skeins:

a. Loose skein.
b. Close skein.
Completion of new nuclei.
Acquisition of nuclear membranes.
Reappearance of nucleoli.
Completed separation of cell-protoplasm.

Resting Daughter-Nuclei.

Fission of the nucleus is ordinarily followed by cleavage of the protoplasm, the resulting new cells being entirely distinct elements. A deviation from this usual procedure is, however, sometimes encountered where the division of the nucleus has not been followed by cleavage of the cell-protoplasm, the latter remaining undivided even after the repeated division of the nuclei. Examples of such "endogenous" formation are seen in the multinucleated giant marrow-cells. Not infrequently under such conditions the nucleus undergoes repeated abortive division, resulting in the production of irregular lobulated or cleft forms embedded within the common protoplasmic mass.

FIG. 12.

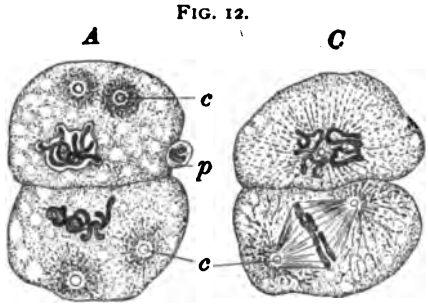

Segmenting ova of *ascaris megalocephala*: *A*, cell contains nucleus, two centrosomes (*c*), surrounded by attraction-spheres, and adherent polar body (*p*); *B*, beginning polar striation around the centrosomes and attraction-spheres; *C*, cell viewed from polar field, the striation proceeding from the centrosome; *D*, cell seen from the side, apices of nuclear spindle correspond with centrosomes. (After *Boveri*.)

FIG. 13.

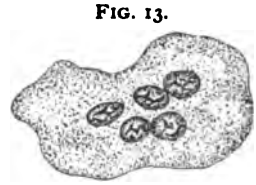

Large marrow-cell: the nucleus has undergone repeated division without cleavage of the protoplasm.

The foregoing vital manifestations, being chiefly concerned in the mere existence and perpetuation of the cell, are appropriately termed **vegetative**; irritability and motion, on the contrary, are the expressions of a higher and more individual existence, and hence are called **animal.** It is to be remarked that the term "animal," as here employed, must not be regarded as indicating distinctions between plants and animals; for this purpose such manifestations are inadequate, since the elements of certain plants (Mimoseæ, Dionæa) possess irritability, and the protoplasm of others (Myxomycetes, Volvocineæ) exhibits motion in a marked degree.

Irritability is that property of living matter by virtue of which external influences are responded to by changes within the cell; these changes may, in turn, induce secondary phenomena. Instances of such impressions are frequent among the lower forms, where surface elements, or, as among the still simpler unicellular protozoa, the peripheral zone of the protoplasm common to the entire animal, exhibit susceptibility to external stimuli. Among the higher animals irritability is manifested by nerve-cells, which, through their processes, influence other tissues. Concerning the exact nature of the intimate changes taking place within the cell, the sum of which we call nervous phenomena, little is known; it is probable, however, that the albuminous constituents of the protoplasm are the particular seat of these obscure molecular changes.

Motion, more or less pronounced, is a characteristic of all animal cells—and, likewise, of very many vegetal ones—during some portion of their existence. The development and specialization of the adult cell usually result in limitation of the activity of the protoplasm, by reason both of its decrease and of its intimate relations with the surrounding tissues; the cells exhibiting motion in the adult condition are those which retain, to a certain degree at least, their embryonic type: such are the lymphoid and connective-tissue cells.

Motion may be exhibited by elements devoid of, as well as by those provided with, special appendages. The lowest degree of this vital manifestation is encountered in the streaming of the protoplasm within cells, as in plants, enclosed within limiting membranes which do not permit such motion to affect the exterior of the cells. Conspicuous examples of the more marked effects of protoplasmic streaming are familiar in the changes readily observed in amœbæ or in the colorless blood-cells of higher types. In these latter elements, however, the motion is manifested rather in change of form than by marked variation in position.

The highest expression of motion is displayed by those cells whose protoplasm has undergone specialization, resulting either in the production of a peculiar tissue, as that of the voluntary muscle fibre, or

of external appendages, as the cilia of many unicellular organisms or of the epithelial elements of the higher animals.

Since every cell is derived from a pre-existing cell, it follows that all the cells of the organism are the descendants of the parent element—the ovum. The ripe mammalian egg, while small in comparison with many other ova, is among the largest histological elements, measuring about .2 millimetre in diameter, and, further, possessing all parts of the typical cell.

Before the ovum is capable of uniting with the male sexual element to carry out the changes attendant upon fecundation, it passes through a cycle of preparatory stages collectively known as **maturation.** These changes consist in the repeated very unequal division of the ovum, resulting in the formation of the **polar bodies**; of these latter, usually two are extruded. The nucleus which appears within the

FIG. 14.

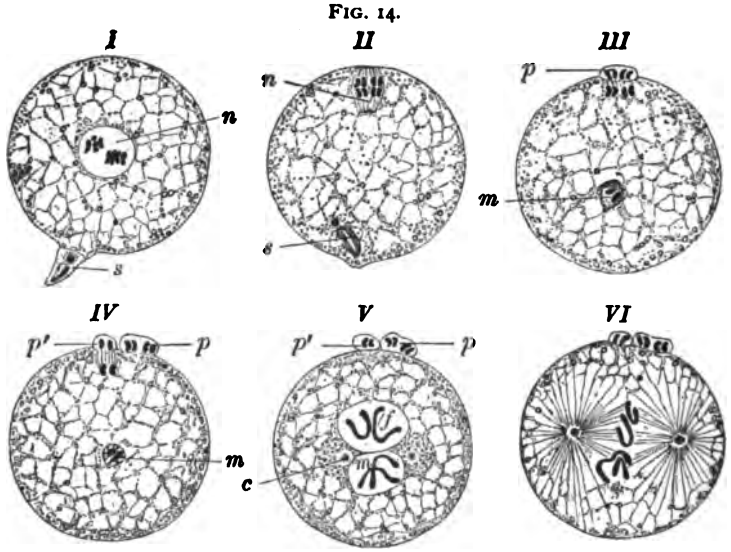

Maturation and fecundation in ova of *ascaris megalocephala*: *I*, *n*, nucleus of ovum before maturation; *s*, entering spermatozoon; *II*, nucleus (*n*) has passed to periphery of cell preparatory to dividing; *s*, spermatozoon now within the ovum; *III*, nucleus dividing into first polar body (*p*); *m*, male pronucleus resulting from spermatozoon; *IV*, *p*, *p'*, first and second polar bodies, the last still in process of formation; *m*, male pronucleus; *V*, *p*, *p'*, polar bodies; *f* and *m*, respectively female and male pronuclei, in contact but not yet fused; *c*, centrosomes, indicating poles of nuclear spindle; *VI*, pronuclei now fused; striation proceeds from centrosomes preparatory to division of ovum. (After *O. Hertwig.*)

ovum after the formation of the polar bodies is the **female pronucleus.** Upon the completion of these phenomena, maturation has taken place and the ovum is prepared for the reception of the male sexual element. Under favorable conditions the spermatozoa reach

the ovum, when a single element penetrates the envelopes of the egg and is received within the protoplasm of the female cell. The head of the spermatozoon, which alone passes within the ovum, becomes transformed into the **male pronucleus.** Subsequently the latter approaches the female pronucleus, the fusion of the two pronuclei being followed by the appearance of a new **nucleus of segmentation,** so called from the fact that within this body cleavage of the ovum is first inaugurated. The segmentation nucleus contains the chromatin contributed by the sexual elements of both parents—the fundamental fact in the consideration of heredity.

The process of segmentation following the fertilization of the ovum is essentially one of indirect cell-division, in which the stages, although modified in certain details, are essentially the same as those already described. The mammalian ovum undergoes a **total** segmentation; although the resulting segments are, strictly regarded, not quite equal in size, yet, as a matter of simplicity, they may be regarded as such, and the division characterized as **total equal segmentation.**

The repeated cleavage of the segmentation-spheres into which the ovum is divided soon produces a mass of innumerable cells constituting the **blastoderm**; the latter, by continued division and further differentiation, subsequently gives place to a cell-area, in which at first two layers, an outer and an inner, and later a third middle stratum, of cells appear. These more or less imperfectly defined tracts constitute the important **primary blastodermic layers,** the ectoderm, mesoderm, and entoderm, from which are derived all the tissues of the body. The reader must be referred to the various text-books of embryology for a detailed account of the complicated and often obscure processes of maturation, fertilization, segmentation, and blastulation, of which only the most salient points have been indicated above.

THE TISSUES.

Every tissue is composed of two parts,—the **cellular elements** and the **intercellular substance.** Upon the first of these depends the vitality of the tissue, while its physical properties are determined by the character of the second. The physical condition of the intercellular substances includes a wide latitude, varying from that of a fluid, as blood or lymph, through all degrees of density, until, by the additional impregnation of calcareous matters, the well-known hardness of bone or dentine is attained.

The proportion between the cellular elements and the intercellular substance of mesodermic tissues varies with age and development, the intercellular substance in the early stages being scanty and very

yielding, while with adolescence they may become tough and resistant. Accompanying the growth of the tissue, an increase of the intercellular substance usually takes place through the direct or indirect participation of the cells, these latter, in consequence, suffering marked reduction in number and size. The younger the mesodermic tissue, the richer is it in cells and the poorer in intercellular substances; conversely, the older the tissue, the more prominent the intercellular substance and less conspicuous the cellular elements. A marked example of this law is presented by tendon, where, in the embryonic condition, the cells constitute the greater bulk of the tissue, while in the adult the intercellular fibrous tissue so overwhelms the cellular elements that reagents are frequently necessary to satisfactorily demonstrate their existence.

While increase of the intercellular substance usually accompanies the growth of the mesodermic tissues, those derived from the ecto- and entoderm present a marked contrast. In these latter tissues the intercellular constituent is represented by the very scanty cement substance, increase in which occurs only as necessitated by the growth of the surrounding cells, the proportion between the two elements being practically constant throughout life. Instances of this constant relation are seen in the varieties and modifications of the epithelial tissues.

The primary blastodermic layers—**ectoderm, mesoderm,** and **entoderm**—early exhibit histological differences which suffice to distinguish the one from the other, and especially to indicate, at least in a general manner, the tendency of the outer and inner layers to

FIG. 15.

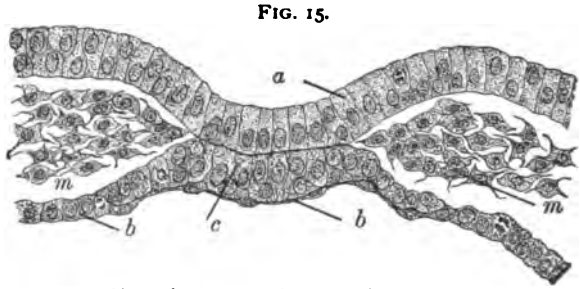

Blastodermic layers of rabbit embryo: *a*, ectoderm; *b*, entoderm; *c*, entodermal cells destined to form notochord; *m*, mesoderm.

form epithelial structures in contrast to the less compact and more reticular formations of the mesoderm. The epithelia of the genito-urinary tract, however, are marked exceptions in their origin, being derived, as well as the connective and muscular tissues, from the mesoderm, in this respect constituting conspicuous specializations.

Derivatives of the Primary Blastodermic Layers.

From the **ectoderm** are derived—

The epithelium of the outer surface of the body, including that of the conjunctiva and anterior surface of the cornea, the external auditory canal, together with the epithelial appendages of the skin, as hair, nails, sebaceous and sweat glands (including the involuntary muscle of the latter).

The epithelium of the nasal tract, with its glands, as well as of the cavities communicating therewith.

The epithelium of the mouth and of the salivary and other glands opening into the oral cavity.

The enamel of the teeth.

The tissues of the nervous system.

The retina; the crystalline lens.

The epithelium of the membranous labyrinth.

The epithelium of the pituitary and pineal bodies.

From the **mesoderm** are derived—

The connective tissues, including areolar tissue, tendon, cartilage, bone, dentine of the teeth.

The muscular tissues, with the exception of the muscle of the sweat-glands.

The tissues of the vascular and lymphatic systems, including their endothelium and circulating cells.

The sexual glands and their excretory passages, as far as the termination of the ejaculatory ducts and vagina.

The kidney and ureter (but not the bladder).

From the **entoderm** are derived—

The epithelium of the digestive tract, with that of all glandular appendages except those portions derived from ectodermic origin at the beginning (oral cavity) and termination of the tube.

The epithelium of the respiratory tract.

The epithelium of the urinary bladder and urethra.

The epithelium of the thyroid and thymus bodies, the atrophic primary epithelium of the latter being represented by Hassall's corpuscles.

CHAPTER II.

THE EPITHELIAL TISSUES.

THE free surface of the skin and of the various mucous membranes is covered by epithelium, which affords protection to the more delicate parts lying beneath. In this tissue the intercellular constituent is reduced to a minimum, being represented alone by the scanty cement-substance between the cells; the latter, in consequence of this relation, form practically an unbroken sheet.

The epithelia are best grouped under two chief heads—**squamous** and **columnar.** The designation as tessellated or pavement is not distinctive, since either variety may present a mosaic when viewed from the free surface. These tissues may be classified in several divisions as below indicated.

VARIETIES OF EPITHELIUM.

I. Squamous. *II. Columnar.*

a. Simple—consisting of a single layer—*a.* Simple.

b. Stratified—consisting of several layers—*b.* Stratified.

III. Modified.

a. Ciliated; *b.* Goblet; *c.* Pigmented.

IV. Specialized.

a. Glandular epithelium; *b.* Neuro-epithelium.

The epithelium contains no blood-vessels, the nutrition of the tissue being maintained by the absorption of the nutritive juices conveyed by means of the intercellular clefts within the cement-substance. The nervous supply of epithelium is likewise ordinarily very scanty, the existence of nerve-fibrils within the epithelium in many localities being doubtful; in certain regions possessed of high sensibility, as the corneal or tactile surfaces, the termination of nerve-fibres among the epithelial elements may be regarded as definitely established. The epithelial cells usually rest upon a basement-membrane, or **membrana propria,** a modification of the subjacent connective tissue of which it is part.

The principal distributions of the various forms of epithelium follow.

Simple squamous epithelium occurs in but few places:

Partially lining the tympanic cavity, including the mastoid cells; parts of the membranous labyrinth; the infundibula and alveoli of the lungs; the posterior surface of the anterior capsule of the crystalline lens; parts of ducts of glands; the capsule of the Malpighian body and the descending limb of Henle's loop in the kidney; choroid plexuses and parts of brain-ventricles.

Stratified squamous epithelium occurs widely distributed, covering—

The skin and its extensions, as the external auditory canal, conjunctival sac, and cornea; the mouth, lower part of pharynx, and œsophagus; the epiglottis and upper part of larynx, together with the false and true vocal cords; the pelvis of kidney, ureter, bladder, beginning and end of male and entire female urethra; the vagina.

Simple columnar epithelium occurs:

a. **Non-ciliated,** in—

The digestive tract, from the œsophageal opening of stomach to anus, as well as in the larger ducts of the glands communicating with this tube; ducts of mammary glands; ejaculatory ducts; membranous and penile portions of urethra.

b. **Ciliated,** in—

Oviduct, uterus, and part of canal of cervix; greater part of brain-ventricles and canal of spinal cord.

Stratified columnar epithelium occurs:

a. **Non-ciliated,** in—

Terminal part of the vas deferens; seminal vesicles; olfactory part of nasal fossæ.

b. **Ciliated,** in—

The Eustachian tube and parts of tympanic cavity; lachrymal passages; respiratory part of nasal fossæ, with communicating sinuses; ventricle of larynx, trachea, and bronchiæ; epididymis and first part of vas deferens.

Squamous Epithelium. When occurring as a **simple** layer, the flattened, polyhedral, nucleated plates form a regular mosaic; such epithelium is found but seldom in the human body, the lining of the air-sacs of the lung, the posterior surface of the anterior capsule of the crystalline lens, the membranous labyrinth, and a few other localities being its principal seats.

A far more usual arrangement is as several layers, constituting the **stratified** squamous variety. The isolated cells of such epithelium differ greatly in form, size, and appearance according to the layer from which they are taken. The cells composing the deepest stratum are not scaly, but irregularly columnar, resting, with slightly expanded bases, upon the subjacent membrana propria. The irregular borders of these cells join with neighboring elements in such a manner that minute intercellular clefts are formed; these are occupied by the yielding cement-substance, and allow the passage of the nutrient juices, as well as of the migratory leucocytes, or wandering cells. The nuclei of the columnar elements are oval, and often situated nearer the outer ends of the cells.

FIG. 16.

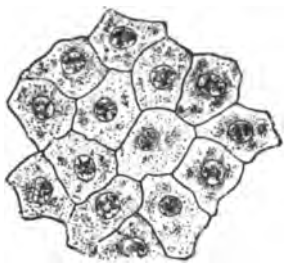

Squamous epithelium from frog's skin, viewed from the free surface.

Passing from the basement-membrane towards the free surface, the form of the cells undergoes a radical change. The pronounced columnar type belongs to the deepest layer alone; the cells next become irregularly polyhedral,

FIG. 17.

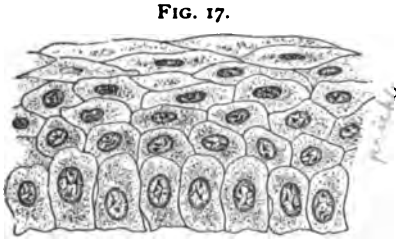

Stratified squamous epithelium in section, from the cornea: the deepest cells are columnar; the superficial are scaly plates.

FIG. 18.

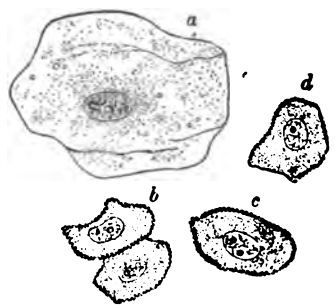

Isolated cells of stratified squamous epithelium: *a*, surface-cell; *b* and *c*, cells from middle layers; *d*, from deepest stratum.

then gradually expand in the direction parallel to the free surface, and become, finally, converted into the large thin scales so characteristic of the outer layers of stratified squamous epithelium.

The cells constituting the middle strata are irregularly polyhedral, and not infrequently seem to be mutually connected by means of delicate processes, which bridge the intervening intercellular clefts and establish a direct continuity between the neighboring cells; when such elements are isolated, the delicate threads are broken and the disassociated cells appear as if beset with minute spines: these con-

stitute the **prickle-cells.** During the journey to the free surface the character of the protoplasm also alters, the cells losing in vitality and becoming keratose or horny to a greater or less degree. The extent to which these changes occur depends upon the external conditions affecting the tissue: on mucous surfaces kept continually moist by secretions the cells retain their plasticity and nuclei; where, on the contrary, they are exposed to the desiccating influences of the atmosphere, they lose their nuclei and become dry and horny, as conspicuously seen in the superficial cells of the epidermis. Fatty granules and small oil-drops, sometimes, also, adherent masses of bacteria, are common in the superficial cells. As the young growing cells of the deeper layers increase in size and numbers, they push those of the superimposed strata towards the free surface, where the older superficial cells become loosened and gradually set free, constituting the physiological desquamation continually taking place.

FIG. 19.



Prickle-cells from middle strata of the epidermis.

In certain localities, as in the urinary bladder, the columnar cells of the deep layer rapidly assume the scaly character of the superficial strata; such epithelium possesses relatively few layers, and, from the facility with which the type of the cells changes, is often described as "transitional." It is to be remembered that such epithelium constitutes not a distinct variety, but only a modification of the stratified scaly group.

Columnar Epithelium. The columnar epithelium, when occurring as a single layer of cells, constitutes the **simple** columnar variety, which, however, enjoys a much wider distribution than the corresponding squamous group. The taller or shorted columnar cells rest upon the membrana propria with their bases, and join their neighbors with more or less accuracy. The free or outer ends of the cells in some localities, as, conspicuously, in the intestine, are characterized by the presence of a narrow **marginal zone,** or basal border: this exhibits a vertical striation, which, on the addition of a reagent, as water, often breaks up into a series of rods, resembling very robust cilia. When the single layer of these epithelial cells is replaced by several, as in the **stratified** columnar

FIG. 20.

Simple columnar epithelium from intestine: the free ends of the cells present a peculiar striated border-zone. Highly magnified.

FIG. 21.

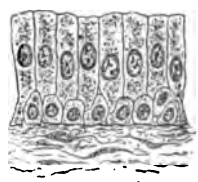

Stratified columnar epithelium from vas deferens: the deepest layer consists of small cells, between which the columnar cells extend.

variety, the outermost cells alone are distinctly columnar; these are usually modified at their outer ends, becoming pointed, forked, or club-shaped, in order to fit between the irregularly polyhedral and pyriform elements of the deeper strata. The nucleus is situated about the middle of the columnar surface cells, and somewhat eccentrically nearer the basement-membrane in the deeper cells. The protoplasm of columnar epithelium often contains particles of mucous secretion, indicating the beginning of those changes which result in the production of the goblet-cells.

Modified Epithelium. The free surfaces of the epithelium in particular localities, as noted in detail in the foregoing summary, are armed with minute hair-like processes, or **cilia**; these, by their constant active vibration, create a current, which serves to free the mucous membranes from accumulation of mucus and offending foreign or irritating substances. Cilia are specializations of the protoplasm, with which they are probably directly and intimately connected; widely distributed and attached to the various forms of epithelium in the lower animals, in man and the higher mammals cilia are limited to columnar cells.

FIG. 22.

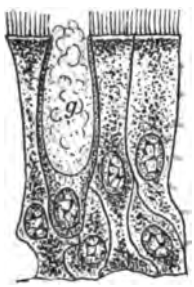

Ciliated epithelium from trachea: *g*, a cell filled with mucus about to be discharged.

FIG. 23.

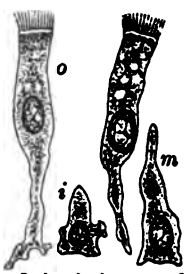

Isolated elements of ciliated columnar epithelium from trachea: *o*, *m*, *i*, cells from surface, middle, and deepest strata.

The exact number of individual cilia attached to the free surface of a single cell varies, but there are, probably, between one and two dozen such appendages usually present. Their length likewise differs with locality, those lining the human epididymis being about ten times longer than those of the trachea. When analyzed, by careful observation of favorable cells in not too rapid vibration, the motion will be seen to consist of two parts—a rapid primary movement, directed to correspond with the general current, and a slower secondary return to the original position, the free end of the cilium describing a course resembling that of a whip-lash. The vibrations, whose rate has been estimated at about ten per second, do not occur simultaneously in all the cells, but exhibit a progression, one cell after the other taking part in the motions, whereby a series of distinct waves of ciliary motion is produced; in addition, a certain periodicity or rhythm often characterizes the vibrations.

When favorable conditions obtain, including a sufficient supply of moisture, oxygen, and heat, ciliary motion may be maintained for

ours, and even for days; the cells of cold-blooded animals in continue to vibrate longer than those of mammals.

rapidity of the ciliary motion is readily influenced by tem- e and reagents. While the application of gentle heat stimu- ıe motion is temporarily arrested by a reduction to 5° C., and ently impaired by an elevation above 50° C. Increased is at first produced by the addition of weak alkalies or acids, l, however, by a permanent suspension after the prolonged of these reagents. Cold, chloroform, etc., on the contrary, prompt reduction and, finally, stoppage of the vibrations.

ırfaces clothed with columnar epithelium, certain cells are ıished by unusually clear protoplasm and exceptional size; re the **goblet-cells**, whose peculiar elliptical or chalice form from the accumulation of mucoid substance ted within their protoplasm. When the dis- becomes too great, the cell bursts in the n of least resistance, evidently towards the face, and the secretion is poured out on the of the mucous membrane. Goblet-cells n all surfaces covered by columnar epithelium, h especial profusion in the large intestine. elements may be regarded as corresponding unicellular glands of the lower animals; in re mucous glands, as the mucous acini of the illary and sublingual, the majority of the secreting elements condition similar to that of the goblet-cells.

FIG. 24.

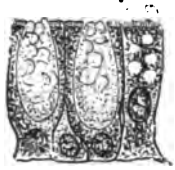

Goblet-cells from large intestine containing mucous secretion.

protoplasm of epithelial cells often becomes invaded by par- f foreign substances; thus, granules of fatty and proteid are very commonly encountered, while esence of granules of eleidin in certain the epidermis characterizes the stratum sum. When these invading particles are , as when composed of melanin, the pro- ı of the affected cell acquires a brown or int, and is then known as **pigmented lium**; such cells are constant in the deeper f the epidermis, especially of certain races, the outer layer of the retina.

FIG. 25.

Pigmented epithelium from outer layer of retina: the nuclei (*n*) still uninvaded.

ialized Epithelium. Reference has ade to the goblet-cells as being, tempo- : least, sufficiently specialized to represent lar glands; when the elements become permanently modified ıge in the elaboration of secretion they are recognized as **lar epithelium.**

The cells lining the ultimate divisions of glands are the modified extensions of the epithelial investment of the adjacent mucous membrane, of which they are the direct outgrowths. **Glandular epithelium** varies in form from columnar (pancreas) to spherical (parotid) and polyhedral (liver). The protoplasm of such cells is generally more or less filled with particles of secretion, upon whose quantity and arrangement the apparent condition of the protoplasm largely depends. Sometimes the latter is almost entirely displaced by fatty matters, as in the sebaceous glands or in the active mammary acini, or, again, is so encroached upon by particles of secretion that a reticulation of the protoplasm is very conspicuous.

The elements lining parts of certain glands exhibit more or less striation, on account of which peculiarity such cells are known as **rod-epithelium**; examples of this are seen in the ducts of the salivary glands, and in the irregular and, to a less evident degree, the convoluted portions of the uriniferous tubules of the kidney.

FIG. 26.

Glandular epithelium: small acinus from a serous racemose gland.

The epithelial coverings of those areas towards which the terminations of the nerves of special sense are particularly directed undergo high

FIG. 27.

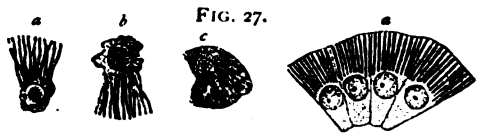

Rod-epithelium: *a*, *b*, *c*, isolated epithelial cells from uriniferous tubules of rat (after *Heidenhain*); *d*, rod-epithelium from submaxillary duct of dog. (After *Schiefferdecker*.)

specialization, resulting in the production of perceptive elements, to which, as a group, the name **neuro-epithelium** has been applied. The rod- and cone-cells of the retina, the hair-cells of Corti's organ and other parts of the membranous labyrinth, the olfactory cells of the nasal fossæ, and the taste-cells of the taste-buds, are all familiar examples of such specialized epithelium. In these elements two parts are present—an inner, containing the nucleus, and corresponding to the usual protoplasm of the cells, and an outer, peripherally-directed segment, which is highly specialized, and not infrequently terminates in stiff, rigid, hair-like processes. The outer segment receives the stimuli from external impressions, while the inner, centrally-directed, segment stands in close anatomical relation with the nerve-fibres.

FIG. 28.

Isolated neuro-epithelium from nose: *o*, olfactory cells; *s*, sustentacular elements.

ENDOTHELIUM.

Although endothelium is intimately related to the connective tissues, being but modifications of the cells of this group, it is convenient to describe this tissue in the present place. Endothelium forms a covering of the free surface of those spaces **not directly communicating** with the external atmosphere, including, therefore, the lining of the various serous cavities, as the pleura, pericardium, and peritoneum (disregarding the communication established through the oviduct), of the synovial surfaces of joints, of the heart and blood-vessels, as well as of the numerous lymphatic spaces and vessels. These cells occur normally as a single layer of thin, irregularly polyhedral plates of variable size and of great delicacy; they possess an oval, sometimes kidney-shaped, nucleus; they never overlap, and usually unite with neighboring cells by serrated and tortuous lines of cement-substance. The endothelial plates covering the serous membranes are, in general, polyhedral, resembling in outline the simple scaly epithelium; those lining the blood-vessels are elongated, irregular spindles, while those found in the lymphatic vessels are often still more unsymmetrical, being limited by very tortuous boundaries.

FIG. 29.

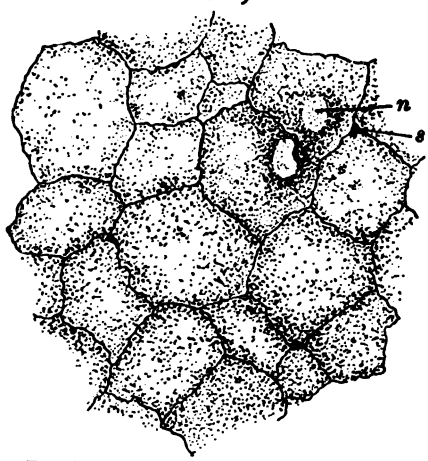

Endothelium from peritoneal surface of diaphragm, stained with silver: *n*, nucleus of endothelial plate; *s*, one of the intercellular clefts or stigmata.

For the satisfactory study of endothelium resource to silver staining (see Appendix) must be had, by which method the intercellular cement-substance is colored deeply brown or black, appearing as dark, frequently-interrupted boundary-lines. In such preparations the points of union common to several cells are often marked by small, deeply-stained areas—the **stigmata**, or pseudo-stomata. These figures are regarded by some as minute openings filled by silver-stained albuminous substances; according to Klein, however, many of these stigmata are the protruding stained processes of connective-tissue cells. In addition to these areas of questionable import are true distinct openings, the **stomata**, which establish direct communication with the adjacent lymphatic channels; the diaphragm,

and especially the septum separating the peritoneal sac from the abdominal lymph-cavity of the frog, exhibit well these pores. The larger stomata are lined by several small granular **guard-cells,** whose expansion and contraction largely influence the size of the openings.

FIG. 30.

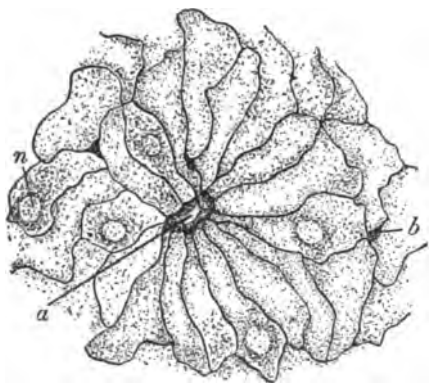

Endothelium from the septum cisternæ of frog, stained with silver: *a*, one of the true stomata, lined with guard-cells; *b*, intercellular cleft; *n*, nucleus.

The **development of epithelium** is intimately associated with the extensions of the great ecto- and entodermic tracts, since, with the exception of the epithelium of the greater part of the genito-urinary organs, the epithelia are the direct descendants of the outer and inner embryonic layers. The cells lining the passages connected with the sexual glands, as well as the urinary tract as far as the bladder, are derived from those of the Wolffian body and duct, and hence have, with these latter, a common mesoblastic origin. The simple arrangement of the cells in the earlier stages gradually gives place to the more complex disposition of the mature tissue.

The **development of endothelium** forms part of the history of the changes taking place within the extensive mesodermic areas; from the specialized sheet, or mesothelium, bounding the primary body-cavity of the young embryo, the endothelium of the pleural, pericardial, and peritoneal cavities directly descends, while the lining cells of the vascular and lymphatic channels trace their origin to the differentiation of certain of the mesodermic elements.

CHAPTER III.

THE CONNECTIVE TISSUES.

THE important group of connective substances—the most widely distributed of all tissues—is the direct product of the great mesoblastic tract, axial as well as peripheral; the several members of this extended family are formed by the differentiation and specialization of the intercellular substance, wrought through the more or less direct agency of the mesoblastic cells. The variation in the physical characteristics of these substances is due to the condition of the intercellular constituents of the tissues. Taken during the period of embryonal growth, they are represented by a semi-gelatinous, soft, plastic mass; a little later, the still soft, but already definitely formed, growing connective tissue exists, which is soon replaced by the yielding, though strong, adult areolar tissue. Grouped as masses in which the white fibrous tissue predominates, the marked toughness of tendon is reached; or where large quantities of yellow elastic tissue are present, great extensibility is secured. A further condensation of the intercellular substance produces the resistance of the matrix of hyaline cartilage, with the intermediate gradations presented by the fibrous and elastic varieties; the ground-substance becoming additionally impregnated with calcareous salts, the well-known hardness of bone or dentine is attained. In all these variations in the density of the intercellular substance the cells have undergone but little change—the connective-tissue corpuscle, the tendon-cell, the cartilage-cell, and the bone-corpuscle being morphologically identical.

The principal forms in which connective tissue occurs are,—

1. *Mucous tissue*, as in the jelly of Wharton of the umbilical cord.
2. *Growing, immature tissue*, as in very young animals or in old embryos.
3. *Areolar tissue*, as in the subcutaneous and intermuscular tissues.
4. *Dense mixed fibrous and elastic tissue*, as in the sclera, fasciæ, etc.
5. *Dense white fibrous tissue*, as in tendon and the cornea.
6. *Dense elastic tissue*, as in the ligamenta subflava.
7. *Cartilage*—fibrous, elastic, and hyaline varieties.
8. *Bone.*
9. *Dentine.*
10. *The reticulum of adenoid tissue and glands.*

11. *The elastic reticulum of organs.*
12. *The supporting and uniting framework* of the various organs.
13. *Adipose tissue.*

The **cellular elements** of the connective tissues are usually described as of two kinds—the "**fixed**" or connective-tissue cells proper and the **migratory** or "wandering" cells. The former, in their typical and unrestrained condition, are flattened stellate protoplasmic plates, each with a nucleus occupying the thicker part of the body of the cell, from which branched processes extend; in some instances the protoplasm extends in several planes as thin, plate-like wings. The nuclei are limited by distinct membranes, and frequently contain well-marked nucleoli.

FIG. 31.

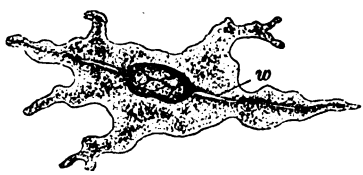

Connective-tissue cell from young subcutaneous tissue: *w*, wing-like expansion seen in profile.

While possessing in its early condition the plate-like form in a greater or less degree, the ordinary connective-tissue cell, owing to its participation in the formation of the intercellular tissue, suffers greatly during the later stages of its history; the expanded cell-body soon gives place to smaller outlines, while the protoplasm diminishes until the once large element is reduced to the inconspicuous spindle-cells of adult areolar tissue, in which only a thin envelope of protoplasm surrounds the nucleus. The connective-tissue cells, when rich in protoplasm and under favorable conditions, are capable of exhibiting amœboid movements, the variations being, however, limited to alterations of form brought about by the extension or retraction of the protoplasmic processes.

FIG. 32.

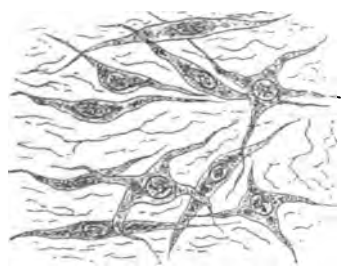

Embryonal connective tissue: the intercellular substance is only slightly differentiated.

Associated with the flattened, plate-like elements of connective tissue, in many places are found the highly-vacuolated **plasma-cells** of Waldeyer. These are of uncertain form, often irregular, extended, or spindle, and consist of soft protoplasm, which, owing to the numerous vacuoles contained, presents an appearance in marked distinction to that of the ordinary branched cell. The plasma-cells probably bear a somewhat constant relation to young tissues in which the formation of new blood-vessels is still progressing.

In addition, occasional peculiar **granule-cells** (the "Mastzellen" of the Germans) must be recognized. These elements often appear spherical in form, and are distinguished by the conspicuous granularity of their protoplasm, the granules possessing a strong affinity for dahlia and basic aniline stains. The granule-cells occur in especial profusion in the vicinity of blood-vessels, and seem to be intimately connected with the formation of adipose tissue.

FIG. 33.

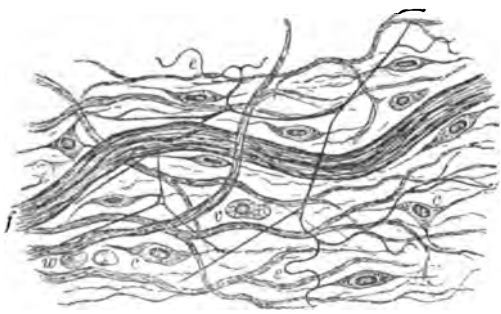

Subcutaneous areolar tissue: *c*, *c*, some of the connective-tissue corpuscles; *w*, migratory cells; *v*, plasma-cell; *e*, elastic fibres.

In contrast to these larger connective-tissue elements, irregularly round or ovoid smaller cells are often present, which, from their ability to change their position as well as form, are termed the **wandering cells.** These consist of small, nucleated masses of active protoplasm, characteristic of the lymph or colorless blood-cells with which they are identical, usually being really leucocytes which have passed out of the vessels into the surrounding tissues, through which they wander as transient guests.

The protoplasm of the fixed cells sometimes exhibits accumulations of dark particles, the elements then appearing as the large, irregularly branched **pigment-cells,** which form conspicuous objects in the connective tissues of many of the lower animals; in man, such cells occur principally within the choroid and iris, and in certain parts of the pia mater. The pigment-cells vary in shape and size; usually stellate and of moderate extent in the higher vertebrates, they assume the most elaborate and grotesque forms and reach enormous dimensions within the tissues of the lower animals.

FIG. 34.

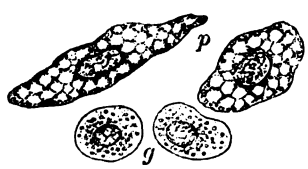

Special connective-tissue elements: *p*, vacuolated plasma-cells; *g*, granule-cells.

FIG. 35.

Pigmented connective-tissue corpuscles from the choroid.

The immediate vicinity of the blood-vessels is a favorite locality for pigment-cells, their arborescent processes often forming a net-work completely enclosing the vessel. The supporting stroma of various organs of many of the lower animals frequently contains such cells, the liver constantly presenting conspicuous groups of deeply-pigmented elements. Pigment-cells are capable of spontaneous movement, the changes including not only alterations or retractions affecting the processes—phenomena directly influenced by the action of the light—but likewise decided alterations in position and location of the cells.

FIG. 36.



Pigment-cell from newt's skin.

The granules of the dark-brown pigment were formerly regarded as composed of **melanin** derived from the coloring-matters of the blood; recent investigations, however, render it probable that, while apparently the same, the dark pigment found within the various tissues is by no means always identical in composition. The isolated particles when examined with high amplification are but slightly colored, the characteristic tint appearing only when the pigment-granules are massed. Exceptionally the colored particles are taken up by the cells as pre-existing pigment-granules; more usually, however, they are produced within the protoplasm of the cell by elaboration from special substances held in solution.

The **arrangement of the connective-tissue cells** varies with the age and density of the tissue. Where the cells retain the stellate type, a protoplasmic net-work extending throughout the tissue is formed by the union of the processes; examples of such disposition are seen in young mucoid tissues, the cornea, and other connective substances rich in cells. Parallel rows of closely-

FIG. 37.

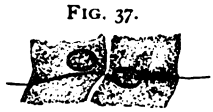

Plate-like connective-tissue cells found in tendon.

FIG. 38.

Cell-spaces of dense connective tissue in which the cells lie: silvered ground-substance; from the cornea.

FIG. 39.

Connective-tissue (corneal) corpuscles: these cells occupy the spaces within the ground-substance.

placed quadrate elements are seen in tendon, while sheets of flattened endothelioid plates characterize basement-membranes and envelop the bundles of fibrous tissue.

In the denser structures the cells occupy **spaces within the ground-substance**; these spaces usually communicate directly with one another by means of minute channels, or canaliculi, and form a complicated system of "juice-canals" through the entire tissue. Within these **tissue-spaces**, or *lacunæ*, lie the connective-tissue corpuscles, generally only partially filling the cavities, and being usually especially applied to one wall of the space after the manner of an endothelial covering. These interfascicular clefts within the ground-substance may be regarded as the radicles of the lymphatic system, in some localities, as in the peritoneum, standing in close relation with both the lymphatic and the blood channels.

The **intercellular** or fibrous constituents of connective tissue are of two kinds—white fibrous and yellow elastic tissue. **White fibrous tissue** ordinarily occurs as wavy bundles of varying thickness, composed of silky fibrils of such fineness that, under ordinary amplification, they present no appreciable thickness; these bundles sometimes run parallel, as in tendon, but more frequently interlace, forming coarser or finer mesh-works, as seen in the omentum and subcutaneous tissues. When examined after teasing, the ultimate fibrils of the white fibrous tissue appear as a confused mass of delicate interlacing lines, but in their undisturbed relation they lie parallel, whatever may be the general disposition of the bundles. Fibrous tissue **yields gelatin** on boiling in water, and swells up and becomes indistinct on treatment with acetic acid.

FIG. 40.

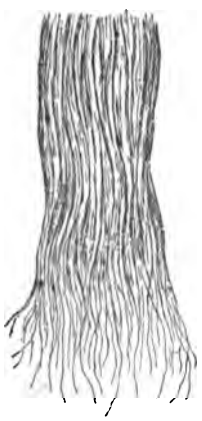

White fibrous tissue: one end of the bundle has been teased to display the component fibrillæ.

FIG. 41.

Elastic fibres isolated; from the adventitia of the aorta. (After *Schiefferdecker.*)

Yellow elastic tissue, on the contrary, occurs usually as a net-work of distinct fibres lying among the bundles of the white fibrous tissue. Examined in detail, the elastic fibre appears highly refracting and

homogeneous, and possesses a definite width throughout its length, although the several fibres forming the same net-work may vary in thickness; not infrequently slight triangular thickenings are found at the points marking the union of several fibrils. Loosened from their attachments, the elastic fibres assume a wavy, bent or coiled condition, highly characteristic. Elastic fibres do not yield gelatin when boiled, but contain **elastin**, which is probably enclosed within a sheath of great delicacy, but of considerable resistance towards reagents.

The most immature, and morphologically the youngest, form of connective tissue is **mucous tissue**, a typical example of which is found in the jelly of Wharton, in the umbilical cord. Here the stellate cells still retain their embryonal characters, and, by the union of their processes, form a protoplasmic net-work throughout the tissue; the meshes of this net-work are occupied by a semi-gelatinous, indifferent, and but slightly differentiated intercellular substance, containing few fibres and occasional wandering cells.

All gradations of density between the immature mucous and the more resistant areolar tissue are supplied by the various stages of development. Ordinary connective or areolar tissue, as found beneath the skin and in many other localities, comprises both white fibrous and elastic tissue. The former usually occurs as wavy bundles, which interlace to form a felt-work of varying compactness; it is probable that the bundles are confined by a delicate sheath, strengthened by transversely and spirally wrapped fibrils, whose positions are marked as constrictions, after the treatment of the bundles with acetic acid. The individual fibrils composing the bundles lie embedded within and held together by a soft homogeneous **ground-substance**, securely uniting them; in the denser tissues the ground-substance contains intercommunicating cell-spaces and canaliculi, the surrounding areas appearing as a homogeneous matrix. The elastic fibres, in varying number and size, form a net-work throughout the tissue. The fixed connective-tissue corpuscles lie embedded among or directly applied to the surface of the bundles of white fibrous tissue, forming, in such cases, an imperfect wrapping or covering; within the interfascicular clefts are the wandering cells.

FIG. 42.

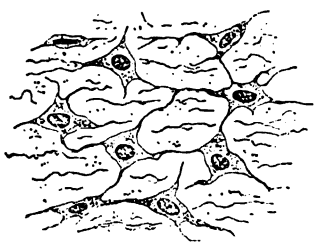

Connective-tissue cells from young umbilical cord: processes of cells unite to form protoplasmic net-work; fibrous elements slightly developed.

The **density** of the tissue depends largely upon the amount and

arrangement of the white fibrous element, while its extensibility is determined by the proportion of elastic tissue present. When the former occurs in well-defined bundles, felted together into interlacing lamellæ, dense and resistant structures result, as fasciæ, the cornea, etc.; in such structures the cement-substance within the interfascicular clefts is usually hollowed out to form the spaces occupied by the connective-tissue cells and their processes.

FIG. 43.

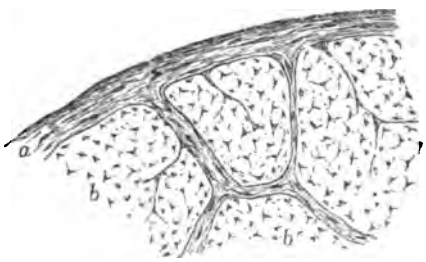

Peripheral part of a tendon in section: *a*, external fibrous investment sending partitions between the secondary groups (*b*) of the tendon-fibres; the small stellate figures represent the stained contents of the interfascicular clefts

Tendon represents a dense connective tissue, composed almost entirely of white fibrous tissue arranged in parallel bundles of varying thickness. The primary bundles, made up of the ultimate fibrillæ, are held together to form larger secondary ones, which latter are enveloped in a delicate sheath covered by endothelial plates; the secondary bundles are bound together and grouped by connective-tissue septa, which are extensions of the thick external sheath wrapping the entire tendon. The larger septa support the blood and lymphatic vessels.

The flattened connective-tissue corpuscles, or **tendon-cells**, occur in rows within the clefts, between the primary bundles, upon and between which the thin, plate-like bodies and wings of the tendon-cells expand. Seen from the surface, these cells appear as quadrate bodies, whose oval nuclei are frequently so disposed that those of two neighboring cells are in close proximity, lying near the adjacent ends of the cells, from which arrangement it follows that each pair of nuclei is separated by the greater part of the length of two cells. Viewed in profile, the tendon-cells show as narrow, irregularly rectangular bodies; while when examined in transverse section the same cells appear as stellate bodies, whose extended arms, passing often in several planes, represent the sections of the wing-plates. Each cell

FIG. 44.



Primary bundles of white fibrous (tendon) tissue, on and between which the flattened tendon-cells lie: at *s* these are seen from the surface; at *o* and *p*, oblique and profile views.

occupies a corresponding space within the cement-substance, just as do the cells of other dense forms of connective substances. Elastic fibres are almost, if not entirely, wanting in tendon.

FIG. 45.

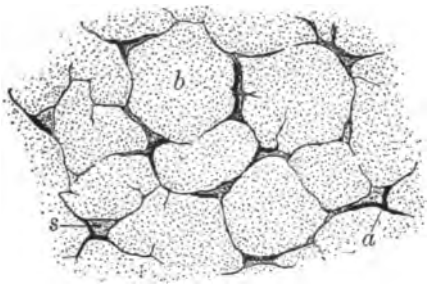

Primary tendon-bundles in section: *b*, the tendon-tissue; *s*, interfascicular clefts occupied by granular material and the tendon-cells (*a*) applied to the bundles.

Elastic tissue, as usually encountered as an element of areolar tissue, occurs in slender fibres; where, however, the elastic tissue becomes the dominating constituent, as in the ligamentum nuchæ or ligamenta subflava of man, the fibres assume much greater size, becoming coarse and of considerable diameter. On transverse section of such tissue the robust individual elastic fibres appear as irregularly angular or polyhedral areas; these are of variable size and held together by a small quantity of areolar tissue. The fibres of elastic tissue may become broad and flattened out, and so closely placed that they assume the form of a reticulated **elastic membrane,** as *Henle's fenestrated membrane* of the larger arteries; again, the tissue may assume the form of a continuous elastic sheet, as *Descemet's membrane* of the cornea.

FIG. 47.

Elastic fibres closely placed, forming the fenestrated membrane; from the aorta.

The **development of the white fibrous tissue** is still a

FIG. 46.

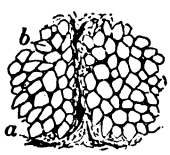

Elastic fibres in transverse section; from the ligamentum nuchæ: *a*, areolar tissue separating the groups of the elastic fibres; *b*, the individual elastic fibres in section.

subject of much uncertainty. It may be regarded, however, as established that it is through the agency of the cells, indirect although their influence may be, that the fibres of connective tissue originate. Two methods are recognized in the production of the fibres. The doctrine of the **direct mode** assumes the transformation of the cell

protoplasm into the white fibrillæ, the periphery of the cell-body becoming the fibres. While such conversion certainly occurs as a primary process (Flemming), it is probable that the **indirect mode,** whereby the fibres originate within an indifferent matrix, also contributes to the production of fibrous tissue ; likewise that the young fibres increase in size by independent growth. Regarding the **development of the elastic fibres,** strong evidence supports the view that the fibres are produced by the fusion of longitudinally-disposed rows of minute particles, which appear within the indifferent intercellular matrix as the derivatives of the cells.

Adipose tissue must be regarded as a member of the group of connective substances, since the accumulation of oily matters within the protoplasm of connective-tissue cells is responsible for the highly

FIG. 48.

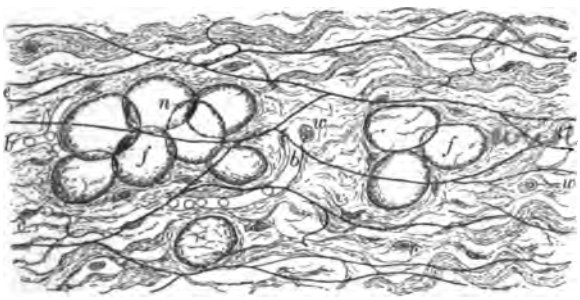

Fat-cells embedded in subcutaneous areolar tissue : *f*, fat-cells ; *n*, nucleus ; *c*, connective-tissue corpuscles ; *w*, migratory cells ; *e*, elastic fibres ; *b*, capillary blood-vessel.

characteristic appearance of the tissue. Whether the fat-cells are developed from elements especially set apart for this *rôle*, or whether they are but modified ordinary connective-tissue cells, is still a disputed point ; there are, however, strong reasons for holding the latter view as correct.

Examined after the usual preparatory manipulations, and in places where the cells maintain their individual forms, as in the omentum, adipose tissue is seen to be made up of relatively large, clear, oval or spherical sacs. The transparent contents are limited by a delicate envelope, composed of cell-membrane and an extremely thin layer of protoplasm ; on one side of the sac a local accumulation marks the position of the nucleus.

Fat-cells occur usually in groups, supported and held together by areolar tissue, through which ramifies a rich, vascular net-work. In localities possessing considerable masses of adipose tissue, as beneath the scalp and the skin, the cells are grouped into lobules, and these

again into larger masses, or lobes; where aggregated and closely pressed together, the normal spherical shape of the individual fat-sacs gives way to a polyhedral form.

Adipose tissue possesses a rich vascular supply, an arteriole passing to each lobule, there to break up into capillary net-works, which surround the individual sacs. The development of adipose tissue is probably not confined to any particular kind of connective-tissue cell, but may involve any of the corpuscles. The granule-cells, however, seem to bear a close relation to the production of fat-tissue.

In those elements about to become fat-cells, a few oil-drops appear within the protoplasm; these increase in size, coalesce, and gradually encroach upon the cell-contents, pushing the nucleus towards the periphery. This displacement progresses with the increasing volume of the accumulating oil, until, finally, the once slender cell is transformed into a distended vesicle, whose protoplasm is expanded to an almost invisible layer immediately beneath the cell-wall, containing, at one side, the flattened and displaced nucleus, which now appears, in profile, as an attenuated crescent. Observations on starved animals show that after the withdrawal and disappearance of the fatty matters, the cells are capable of resuming the usual appearance and properties of connective-tissue corpuscles.

CARTILAGE.

Cartilage represents a dense connective tissue in which the intercellular substance has undergone great condensation. Depending upon the variation in the character of the matrix between the cells, **three varieties** of cartilage are recognized—**hyaline, elastic,** and **fibrous.** Regarded in their relationship to the denser connective tissues, the order of enumeration should be reversed, the fibrous variety standing next and differing but little from tendon. Since by "cartilage" the typical hyaline variety is usually understood, that form first claims attention.

FIG. 49.

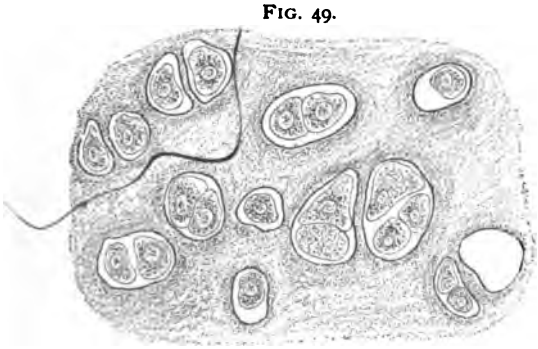

Hyaline cartilage from the rib: the cells lie embedded within the lacunæ, either singly, in pairs, or in groups; matrix exhibits differentiation around the cell-spaces as more deeply staining areas.

Hyaline cartilage, so named from the transparent, apparently homogeneous character of the intercellular **matrix,** enjoys a very

wide distribution, occurring as the articular cartilage of bones, costal cartilages, the larger cartilages of the larynx, trachea, or bronchi, nose, Eustachian tube, etc.; in the embryo the entire skeleton, with the exception of the vault of the cranium, the bones of the face, and the greater part of the lower jaw, is mapped out by primary hyaline cartilage.

The homogeneity of the **hyaline matrix** is only apparent, since, as long ago pointed out by Leidy, the intercellular substance may be resolved into bundles of fibrous connective tissue, which, however, are so closely united and intimately blended by the cementing ground-substance that the presence of the fibres is, ordinarily, not evident. After prolonged boiling, cartilage matrix yields **chondrin.**

Embedded within the hyaline matrix lie the **cartilage-cells**; these are irregularly oval or angular nucleated protoplasmic bodies, which, during life, probably fill the spaces, or **lacunæ**, which they occupy. In adult tissue usually two or more cells share the same compartment, the original occupant of the space having undergone division, so that two, four, or even more daughter-cells form a single group. The **matrix** immediately surrounding the lacuna is specialized as a layer of different density, thereby assuming the appearance of a distinct limiting membrane, described as the **capsule.** A further differentiation of the ground-substance is seen in the greater intensity with which the more recently formed matrix enveloping the cells stains; such resulting figures constitute the **cell-areas.** It is to be remembered that the cartilage-cells are but connective-tissue cells, and that the lacunæ correspond to the lymph- or cell-spaces found in other dense connective tissues. Since it is usual to find these cell-spaces in communication through minute channels, or canaliculi, their absence and the apparent isolation of the lacunæ in cartilage are to be regarded as deviations from the typical arrangement; among some lower forms, however, such a communication exists, the minute canaliculi passing between the neighboring lacunæ.

FIG. 50.

Hyaline cartilage with perichondrium (*p*) attached: *y*, zone of youngest cartilage-cells; *m*, hyaline matrix enclosing the lacunæ containing the cartilage-cells; *l*, space from which the cell has been lost.

The free surface of the cartilage is covered by an envelope of dense connective tissue, the **perichondrium**; this consists of an external

of fibrous layer of dense fibro-elastic tissue and an inner, much looser stratum, between the fibres of which are numerous connective-tissue cells. This inner portion is intimately concerned in the production of new cartilage, and is known as the **chondrogenetic layer.** The cells of the latter arrange themselves in rows parallel to the surface, and gradually assume the characteristics of the cartilage corpuscles, being at first spindle-shaped, but gradually assuming the more spherical form. The new cells soon become surrounded by the recently-formed matrix, which, at first small in amount, soon increases so that the groups of cartilage-cells become separated by more extensive tracts of intercellular substance; as the nests of cells formed by the division of the original single occupant of the lacuna recede from the perichondrial surface they lose their primary parallel disposition and become irregularly arranged and further separated. Sometimes in those portions most removed from the perichondrium the ground-substance appears granular; this feature is intensified when a deposition of calcareous matter takes place, which not infrequently happens in old subjects.

Elastic cartilage is distinguished by the presence of **elastic fibres** within the intercellular substance. The typical hyaline matrix is confined to areas of limited extent immediately surrounding the cell-nests, while the intervening matrix is **penetrated by networks of elastic fibres** extending in all directions. The cells within the lacunæ, in the midst of the **hyaline areas,** resemble closely the usual elements of hyaline cartilage. Elastic cartilage has a much less general distribution than the hyaline variety, occurring principally in the cartilages of the external ear, part of the Eustachian tube, epiglottis, arytenoid cartilages, cartilages of Wrisberg and of Santorini. This tissue presents an opaque, yellowish tinge in contrast to the

FIG. 51.

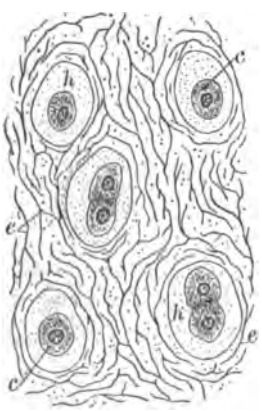

Elastic cartilage from the epiglottis: *c*, cartilage-cells surrounded by a very limited area of hyaline matrix (*h*); the remaining part of the intercellular substance is penetrated by net-works of elastic fibres (*e*), cross-sections of which appear as minute points.

FIG. 52.

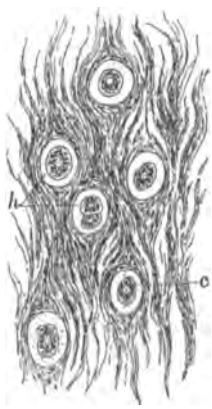

Fibro-cartilage from the knee-joint: *c*, cartilage-cells surrounded by very limited areas of hyaline matrix (*h*); the space between these areas is occupied by the fibrous tissue.

opalescent, bluish tint of the hyaline variety. It is covered by a perichondrium of the usual description.

Fibro-cartilage, as implied by its name, is largely composed of interlacing **bundles of fibrous connective tissue,** embedded in which the round or oval cartilage-cells lie, singly or in groups, immediately surrounded by a narrow **zone of hyaline matrix.** The number of the cells and the proportion of fibrous tissue present differ in various specimens.

Fibro-cartilage is found in comparatively few localities: around the margin of articular surfaces and within certain joints, the symphyses and the intervertebral disks, constitute its chief distribution. The tissue is closely akin to tendon, presenting a white, tough, resistant but pliable tissue. A proper perichondrium is wanting.

The **development of cartilage** proceeds directly from the elements of the mesoderm. The primary close aggregation of the embryonal cells, which early indicates the position of the future cartilage, subsequently gives way to a looser disposition of the cells, resulting from the appearance of the young matrix. After the formation of the perichondrium, the cartilage grows by the addition of new layers beneath the membrane.

BONE.

Bone is a dense form of connective tissue impregnated with lime salts. Composed of the same histological elements as other compact connective tissues, bone differs from these in having a deposit of calcareous matter within the interfascicular cement-substance, to which peculiarity the well-known hardness of the tissue is due. The microscopical appearance of bone varies with the character of the preparation, especially as to whether the earthy matter has been removed before sectioning, or whether thin plates of dried bone are examined; it is in sections of dried bone that the classical pictures of this tissue are seen.

FIG. 53.

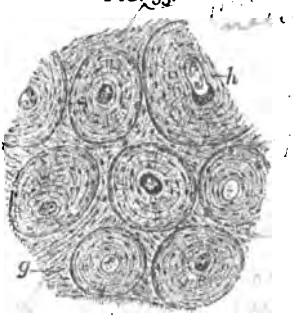

Transverse section of dried bone: *h*, one of the Haversian canals, about which the lamellæ are concentrically disposed, constituting the Haversian systems; *g*, the ground or interstitial lamellæ.

Dependent upon the arrangement of the matrix, **two varieties** of bone are recognized—**spongy** and **compact.** Although the spongy bone is, as we shall see, the fundamental form, yet the compact variety alone presents all the structural peculiarities of the tissue. A **transverse section** of the compact osseous tissue constituting the shaft of one of the long bones presents a number

of round or oval openings—the **Haversian canals**—each surrounded by a broad band or zone composed of **concentrically-disposed lamellæ**; the canal and the surrounding lamellæ form an **Haversian system.** Seen in **longitudinal sections,** the Haversian canals appear as extended channels, some closely corresponding in their course with the general axis of the bone, while others run obliquely and establish free communication between the adjacent canals. The concentric bone lamellæ in such sections appear as parallel bands bordering the large channels. The Haversian canals communicate with the **central marrow-cavity,** of which they are really continuations; variable in width and length, each canal contains an extension of the bone-marrow, comprising a delicate connective-tissue reticulum, rich in cells, blood-vessels, and lymphatics.

FIG. 54.

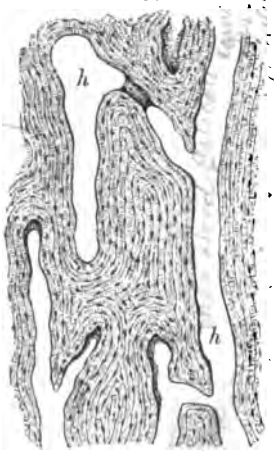

Longitudinal section of dried bone: *h*, Haversian canals opened lengthwise and bordered by the longitudinally-cut lamellæ.

The areas between the Haversian systems are filled out by osseous lamellæ, disposed without regard to the concentric systems; these are the **interstitial** or **ground lamellæ,** and represent the older parts of the bone, being the remains of the primary spongy net-work of periosteal bone. The concentric lamellæ constituting the Haversian systems are secondarily deposited within the enlarged spaces of the bony reticulum. In addition to the lamellæ already mentioned, superficial osseous strata encircle the bone on both its outer and inner (medullary) free surfaces; these are the outer and inner **circumferential** or **fundamental lamellæ.**

FIG. 55.

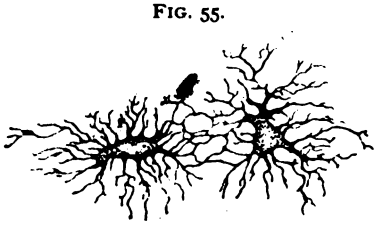

The lacunæ and canaliculi of dried bone under high amplification.

Between the bundles of the ground-matrix spindle-shaped spaces—the **lacunæ**—are seen, from which minute channels—the **canaliculi**—radiate in all directions; these dark, stellate figures with their minute lateral canals form a system of intercommunicating lymph-spaces within the bone; the canaliculi belonging to the same space or to the adjoining lacunæ of the same Haversian system anastomose with one another, but not with the canals of different systems.

In dried bone the spaces are filled with air, the lacunæ and canaliculi consequently appearing dark and sharply defined when viewed by transmitted light. The lacunæ, sometimes improperly called "bone-cells," in dried preparations are empty, or, at most, contain the remains of the soft, protoplasmic bodies, the true bone-cells, which during life partially fill the spaces; these, like the cells of other dense connective tissues, lie within the lymph-spaces of the ground-matrix. In sections of young, well-stained, decalcified fresh bone, after the usual manipulations, the **bone-corpuscles** are seen as nucleated, stellate, protoplasmic bodies, whose processes extend into the canaliculi; in adult and old bones, however, the cells become reduced in size and very inconspicuous. The lacunæ being lenticular, they present different figures according to the direction in which they are sectioned: cut transversely, they appear as short, narrow ovals; opened longitudinally, but not parallel to the lamellæ, they are seen as long, narrow, elliptical figures; while when cut longitudinally, and at the same time parallel to the lamellæ, they present a broad, oval surface, sometimes almost circular; the canaliculi, extending in all planes, appear much the same in all sections.

FIG. 56.

A bone-cell lying within the lacuna of the osseous matrix: decalcified and stained.

The **periosteum,** an envelope of vascular connective tissue, closely invests the outer surface of all bones except the articular facets. This important structure is composed of **two** portions—an outer, dense, protective, **fibrous layer,** and an inner, much looser stratum, rich in cells and blood-vessels, which, from its intimate relations to the formation of bone, is known as the **osteogenetic layer.** This latter contains within its meshes numerous round or spindle cells, many of which later become bone-forming elements—the **osteoblasts.**

FIG. 57.

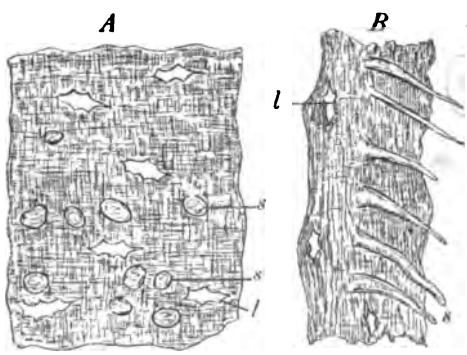

Fragments torn from the surface of a decalcified bone: *A*, surface; *B*, oblique view; *s*, Sharpey's perforating fibres; *l*, the lacunæ.

If a decalcified bone be sectioned parallel to the superficial lamellæ, especially if these be of a spongy bone, or if the outer lamellæ be forcibly torn off, a number of transverse or perpendicular fibres of

more or less delicacy will be exposed; these are the **perforating fibres of Sharpey,** and represent periosteal fibres which have failed to undergo calcification; of these Kölliker recognizes two kinds—those entirely soft and uncalcified, the most numerous and, at the same time, the smallest; and those partly calcified and of larger size, which, in fact, are bundles of fibrous tissue. **Sharpey's fibres** are most numerous in the superficial lamellæ of spongy bones, although found in the interstitial lamellæ of other bones, pinning together the lamellæ which they transfix. The perforating fibres, being derived from the periosteum, never occur in the lamellæ of the Haversian systems, since the latter, it will be found, are not directly produced by the periosteum, but as secondary deposits.

Additional elements of the bone-matrix are the **elastic fibres,** which are found in the outer fundamental lamellæ, as well as occasionally in the deeper interstitial lamellæ; these elastic fibres are generally associated with the uncalcified Sharpey's fibres; not infrequently the elastic fibres are contained within the uncalcified bundles of fibrous tissue composing the large perforating fibres.

Marrow of Bone. The cavities within bones, as well as the elaborate intercommunicating **nutrient channels** extending throughout the osseous tissue, are filled with the highly vascular marrow, which genetically is an extension of the osteogenetic layer of the periosteum, since the primary marrow is a direct ingrowth and extension of this latter tissue. The marrow of all bones in very young animals is red in color; after a certain time, however, that contained within the shafts of the tubular and the spaces of some other bones assumes a lighter tint, finally becoming of a straw color, owing to the accumulation of fat within the marrow-cells. Depending upon this difference, two varieties—the **red marrow** and the **yellow marrow**—are recognized: it is to be remembered that the red marrow is genetically the older and represents the primary condition.

FIG. 58.

Elements of red marrow; stained and highly magnified. *a*, various forms of marrow-cells; *b*, eosinophilic cell; *c*, mast-cell; *d* giant-cell; *e*, nucleated red blood-cells; *r*, red blood-cell.

The **elements** of the red marrow comprise a delicate connective-tissue reticulum supporting a rich vascular distribution, composed of arterioles breaking up into numerous capillaries, which, in turn, give place to venous radicles of large size and extremely thin walls. The

meshes of the tissue contain great numbers of soft, plastic connective-tissue elements, the **marrow-cells**, which, while closely resembling the leucocytes, differ from the blood-cells in possessing a nucleus larger but less rich in chromatin. Larger **eosinophilic cells**, modifications of the marrow-cells, are also encountered. Additional huge multinucleated elements exist as the **giant-cells**, or **myeloplaxes** (Robin); these are of interest as being especially concerned in the **absorption** of osseous tissue, being identical with the **osteoclasts** (Kölliker). Developing nucleated red blood-cells—the erythroblasts—are important constant elements. **Mast-cells**, with eosinophilic granules, are also found as occasional constituents of the red marrow.

Dentine is analogous to bone, although differing in details of arrangement, since it is derived from embryonal connective tissue. The matrix becomes calcified, and contains, embedded within the ground-substance, numerous long, parallel, partly-branched tubes, the **dentinal tubules**. These correspond with the lacunæ of bone, enclosing in some places delicate processes, the **dentinal fibres**. A more extended account of the structure and development of dentine will be found in connection with the structure of the teeth.

Development of Bone. With the exception of the bones of the vault of the cranium, of the face, and of part of the lower jaw, the skeleton is mapped out, in its fœtal condition, by solid cartilages which correspond in form more or less closely with the future bones. The **primary embryonal cartilage** is of the hyaline variety, being extremely rich in cells, many of which are engaged in division; the cell-groups are separated by a relatively small amount of intercellular substance, and the outer surface of these solid cartilages is closely invested by an important membrane, the **primary periosteum.**

FIG. 59.

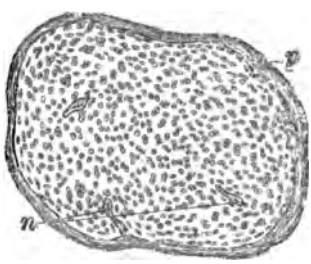

Primary embryonal cartilage representing one of the carpal bones: *p*, perichondrium, or primary periosteum; *n*, nutrient canals extending from the periphery.

When bone is formed at the centres of ossification within the cartilage, it is termed **endochondral bone**; when formed directly from and beneath the periosteum, **periosteal bone.** While quite complicated in its sequence of changes, it must be remembered that endochondral development results in the formation of structures which are largely temporary, and which finally, for the most part, suffer absorption. The permanent bones of the skeleton are, chiefly, the products of

the periosteum; where bone is developed directly from the peric and without being mapped out by primary cartilage, the pr spoken of as **intermembranous bone-formation**, althougl ing in no important respect from that producing the periostea

Endochondral Bone. The first indications of the futu found changes within the solid cartilage correspond in pos the so-called **centres of ossifi** and consist in an increase in t of the embryonal cartilage-cells, as in the amount of intercellul stance separating the cell-nests, f by a characteristic **rearrangen** the enlarged cells **into vertica** or columns; in the matrix betw around these columnar group careous deposit coincidently place. These enlarged cartilag surrounded by the calcified mat the **primary areolæ** of Sharp

FIG. 60.

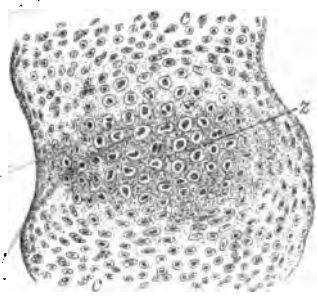

Developing bone—centre of ossification in a carpal bone: *s*, area of enlarged cartilage-lacunæ and calcified matrix; *c*, young cartilage-cells.

Simultaneously with the noted the osteogenetic tissue periosteum has increased and sent processes from a number o into the solid cartilage towards the centre of ossification; the p of the periosteal ingrowth is accompanied by the absorptio cartilage until the focus of central calcification is reached, w greatly enlarged cartilage-lacunæ are opened up and the brought into direct communication with the **primary m cavities.** The **fate** of the **cartilage-corpuscles** has been t ject of discussion; it may be assumed as established that th undergo degeneration and play no part in the formation of bone. This periosteal ingrowth constitutes the **vascular of the cartilage.** The process of breaking down the cartila and opening up the large lacunæ goes rapidly forward, resu the extension of the primary marrow-cavity; the **primary m** filling this latter space, is, as already pointed out, the direct tive of the inner layer of the periosteum.

The primary marrow-cavity, or medullary space, soon be of considerable size, is bordered by the **zone of calcifying car** this area includes the columns of flattened cells and enlarged which pass into the broken and partly-absorbed larger lacu **secondary areolæ,** opening into the primary marrow-cavity

While the horizontal matrix septa between the transvers panded lacunæ disappear, the vertical partitions lying betw

columns of the cells suffer much less reduction, and, as a result, remain and project into the marrow-cavity as irregular **trabeculæ of calcified cartilage.** The marrow-cells rapidly multiply and arrange themselves as a layer upon the surface of the cartilage-trabeculæ; now called **osteoblasts,** they busy themselves in enveloping these with a covering of true osseous tissue. Simultaneously with the deposition of the bone the calcified cartilage within the trabeculæ undergoes absorption, so that the amount of cartilage encased by the new bone gradually diminishes and finally disappears, the entire net-work of anastomosing trabeculæ being now composed of true osseous tissue. This newly-formed net-work constitutes the **central primary spongy bone,** a structure which, in the shafts of the long bones, is but temporary, afterwards entirely disappearing, except at the ends of the bones, where it persists as the cancellous tissue of the extremities.

FIG. 61.

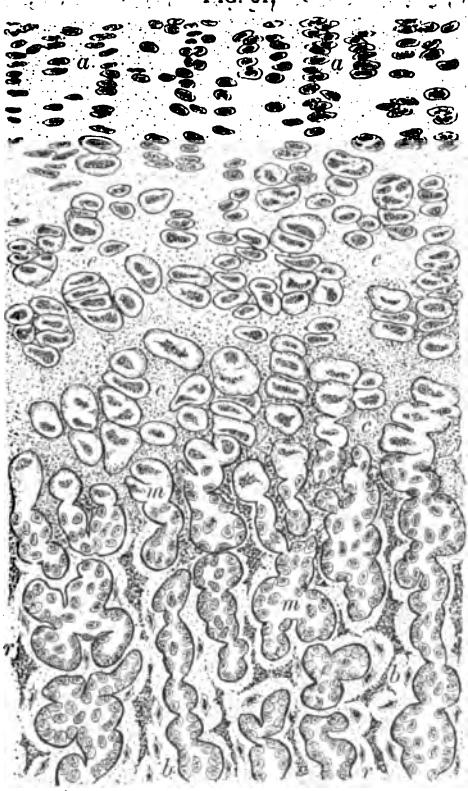

Developing bone—from the end of a long bone: *a*, area of rearranging cartilage-cells; *e*, area of enlarged lacunæ; *c*, zone of calcified matrix; *m*, primary marrow-spaces containing the osteogenetic tissue; *b*, trabeculæ of new bone covering the remains (*r*) of the calcified cartilage-matrix.

It will be noticed that in the changes above described the cartilage is *not directly* converted into bone, ossification being a *process of substitution*, the new bone replacing the primary cartilage.

Starting near the middle of the long bones, the process of calcification and absorption of the cartilage and the formation of the primary spongy bone proceed towards the extremities, the original cartilage gradually disappearing, the growth of the young bone being maintained by increments of new cartilage deposited at the ends beneath the perichondrium.

Periosteal Bone. Simultaneously with the formation of the central spongy endochondral bone the cells of the *osteogenetic layer* of the periosteum are actively engaged in likewise producing osseous tissue, the trabeculæ of which unite to form the peripheral net-work of **periosteal bone,** this in many

FIG. 62.

Developing bone—trabecula of endochondral bone: *a*, the new bone; *b*, bone-cells; *c*, still unabsorbed remains of calcified cartilage-matrix.

FIG. 63.

Developing bone—the surface of portion of bone-trabecula, exhibiting the conversion of the osteoblasts into the bone-corpuscles: *b*, lacuna with young bone-cell; *o*, osteoblasts arranged on the surface of the newly-formed osseous matrix (*m*); at *l* an osteoblast just being isolated.

places forming an outer envelope closely embracing the central endochondral bone.

The details of the process by which the osteoblasts are converted into the bone-cells are the same in both the intracartilaginous and the periosteal formation. The bone-matrix, deposited through the agency of the cells, gradually accumulates around the osteoblast, until this lies completely surrounded by the young matrix, when, after its isolation from the marrow-cavity, it becomes the **bone-corpuscle**. At first the canaliculi are wanting, as are, also, calcareous matters; these later appear.

The **conversion** of the original **spongy into compact bone** depends upon the development of additional lamellæ within the meshes of the primary osseous net-work. As an initial step, a **local absorption** takes place, resulting in the **enlargement** of the primary **medullary spaces** contained between the trabeculæ of the periosteal net-work; these osseous bands are thus reduced to thin bony partitions between large oval cavities, the **Haversian spaces**. A new growth of bone subsequently takes place *within these spaces*,

the osteoblasts depositing new bone upon the walls of these cylindrical cavities, layer upon layer, until only a small central channel—the Haversian canal—remains as the representative of the large Haversian space. The outer boundary of the Haversian system, therefore, corresponds to the limits of the Haversian space, while the remains of the primary bone-trabeculæ constitute the older interstitial lamellæ of the adult tissue.

Osseous tissue, wherever developed, is **formed** through the agency of the **osteoblasts**, the derivatives and descendants of the specialized mesoblastic cells of the embryo; whether in endochondral or periosteal formation, the bone-producing elements

FIG. 64.

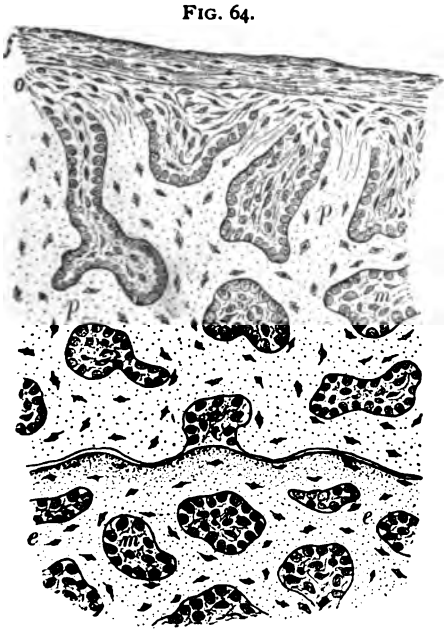

Developing bone—both periosteal and endochondral: *f*, outer fibrous, *o*, inner osteogenetic layer of periosteum; *p*, trabeculæ of periosteal bone covered by the osteoblasts; *e*, endochondral bone; *m*, primary marrow-cavities.

FIG. 65.

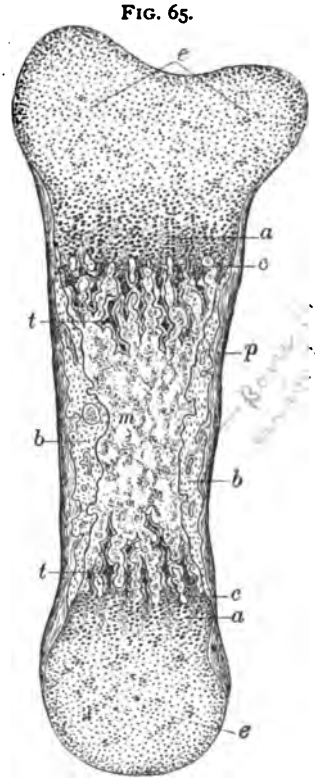

Developing bone—longitudinal section of embryonal phalanx: *e*, the primary cartilage of the extremities of the bone; *a*, zone of enlarged and vertically-disposed cartilage-lacunæ; *c*, zone of calcification; *t*, trabeculæ of calcified cartilage covered with new bone; *m*, marrow-cavity; *b*, periosteal bone formed directly beneath the overlying periosteum, *p*.

arrange themselves over the surfaces of the cartilage-trabeculæ or the periosteal fibres respectively, and soon are surrounded by osseous

matrix; this gradually thickens and encloses the osteoblasts, which now lie within minute bays or recesses, the entrances to which become gradually contracted, until the opposed edges join and the cells lie within lacunæ completely surrounded by the bone-matrix: the osteoblasts have now become the bone-cells. The matrix is deposited as lamellæ, especially marked in the bone formed in the later stages of fœtal life; between these are included the lacunæ. The matrix is at first soft and exhibits an indistinct fibrillated structure in which the subsequent deposit of lime salts—principally the phosphate and carbonate—takes place.

FIG. 66.

Developing bone—portion of trabecula undergoing absorption: *b*, bone-cells; *c*, osteoblasts; *m*, bone-matrix; *o*, multinucleated osteoclast lying within the absorption-pit, or Howship's lacuna.

When, on the contrary, bone or cartilage is **absorbed,** it is through the agency of the giant-cells, the **osteoclasts,** or *chondroclasts* (Klein); these large multinucleated elements usually lie upon the surface of the bone-trabeculæ within larger or smaller pits which have been excavated by them; these are **Howship's lacunæ.**

In recapitulation, the following summary of the phases of development during the growth of a tubular long bone may be noted:

1. *Solid embryonal cartilage.*

2. *Enlargement and rearrangement* of cartilage-cells and lacunæ and calcification of matrix at centre of ossification.

3. *Penetration of periosteal tissue* to the focus of calcification; *vascularization* of the cartilage.

4. *Formation of medullary spaces* by the breaking down of lacunæ surrounded by the *zone of calcifying cartilage.*

5. *Covering of the surface of calcified cartilage* trabeculæ by the layer of osteoblasts and the *production of an enveloping sheath of true bone.*

6. *Resulting central net-work of endochondral bone,* with gradual absorption of encased cartilage trabeculæ.

7. *Absorption of central spongy bone* in shaft and formation of central marrow-cavity.

8. *Formation, meanwhile, of peripheral periosteal net-work* of spongy bone.

9. *Conversion into compact bone* by partial absorption of trabeculæ to form Haversian spaces; secondary deposit of concentric lamellæ within these spaces forming Haversian systems of compact bone.

10. *Absorption of inner lamellæ of compact bone* as the shaft increases in diameter by the deposition beneath the periosteum; production of enlarged medullary cavity.

11. *Continued absorption of endochondral central bone* until the latter is found alone in the epiphyses, where it continues to be produced at the expense of the intermediate cartilage during the entire future growth of the bone.

CHAPTER IV.

THE MUSCULAR TISSUES.

CONTRACTILITY is possessed, to a certain degree, in common by all cells rich in active protoplasm; the distinguishing characteristic of muscular tissue, however, is that this property is so conspicuously developed in highly specialized structures, and that the contractions take place along definite lines in limited directions alone. Contractile tissue or muscle occurs in two principal forms: (1) as the **non-striated, smooth, or vegetative muscle,** usually beyond the control of the will, and hence called *involuntary*, and (2) as the **striated, striped, or animal muscle,** which, being influenced by volition, is known as *voluntary*.

The sharp differences separating the two groups of muscle in man and the higher animals cannot be regarded as fundamental, since in the embryonal condition of these higher forms temporarily, and in the adult form of the lower types permanently, the striped and non-striated varieties of muscle depend upon the degree of specialization rather than upon inherent differences. It is a suggestive fact that long before the cells forming the embryonal heart show indications of differentiation into muscle-tissue the contractions of the organ have commenced. The association of the striped fibres with response to the will and, on the contrary, of the plain tissue with involuntary action must be, likewise, only provisionally accepted, since in some animals the development of marked striæ never takes place in the voluntary fibres. Standing between and connecting the extremes of these groups is the cardiac muscle of the higher vertebrates, in which the fibres are striated, although beyond the control of the will.

NON-STRIATED OR INVOLUNTARY MUSCLE.

Non-striated, smooth, or involuntary muscle, while never occurring in large individual masses, enjoys a wide distribution; its principal localities are—

1. *The Digestive Tract:* the muscularis mucosæ from œsophagus to anus and the delicate bundles of mucosa and villi; muscular tunic from the lower half of œsophagus to anus.

2. *The Accessory Digestive Glands:* in the large excretory ducts of liver, pancreas, and some salivary glands; also in the gall-bladder.

3. *The Urinary Tract:* in the capsule and the pelvis of kidney, ureter, bladder, and urethra.

4. *The Male Generative Organs:* in epididymis, vas deferens, vesiculæ seminales, prostate body, Cowper's glands, cavernous and spongy bodies of penis.

5. *The Female Generative Organs:* in oviducts, uterus, and vagina; in the erectile tissue of external genitals; in the broad and the round ligaments, and in the erectile tissue of the nipple.

6. *The Respiratory Tract:* in the posterior part of trachea; encircling bands in bronchial tubes, and bundles within pleura.

7. *The Vascular System:* in the coats of arteries, veins, and larger lymphatics.

8. *The Lymphatic Glands:* in the capsule and the trabeculæ of spleen; sometimes in the trabeculæ of lymphatic glands.

9. *The Eye:* in iris and ciliary body, and in eyelids.

10. *The Integument:* as the arrectores pili connected with the hair-follicles; in sweat and some sebaceous glands; in skin covering the scrotum and parts of the external genitals.

Involuntary muscle is composed of delicate spindle, often ribbon-like, **fibre-cells**; these vary greatly in size, measuring 75–225 μ* long and 4–8 μ wide. The cells found in arteries are short and flat, being but 25–45 μ long and 9–12 μ wide; the largest elements are found in the gravid uterus, where they reach a length

FIG. 67.

Isolated involuntary-muscle cells from intestine of man.

FIG. 68.

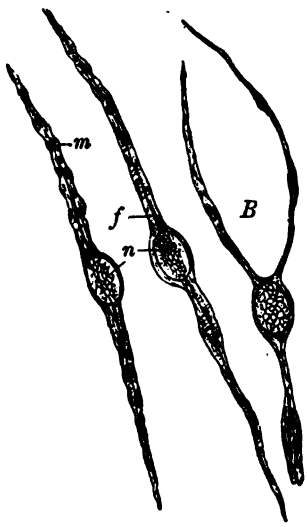

Involuntary-muscle cells from mesentery of newt: *n*, nuclei; *f*, axial fibre; *m*, transverse markings on surface of cell; *B*, muscle-cell with forked extremity.

* 1 μ (*micron*) = the 1000th part of a millimetre.

of over 500 μ and a breadth of 20 μ. Occasional cells with bifurcated ends are encountered, especially among the lower vertebrates.

The spindle muscle-cell is invested with a very delicate, homogeneous, hyaline **sheath**, closely resembling elastic tissue, and corresponding to the sarcolemma of the striated fibre; within this envelope lies the soft, semi-fluid, contractile protoplasm, embedded in which, near the centre of the cell, lies a characteristic, narrow, **rod-shaped nucleus**. Delicate longitudinal fibrillæ usually can be made out extending the entire length of the cell; these are regarded by many histologists as representing the actively contractile parts of the cell, the surrounding protoplasm being largely passive. Transverse markings are also often seen; these correspond in position to local variations in the diameter of the cell, and are probably due to corrugations in the enveloping membrane.

FIG. 69.

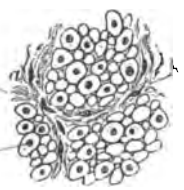

Involuntary muscle in transverse section: portions of three bundles are represented, separated by areolar tissue (*a*): the nucleated areas are sections of the muscle-cells through their nuclei; the smaller figures represent sections of the cells cut nearer the ends.

The individual spindle-cells are closely fitted together and united by an albuminous cement-substance; they are disposed in groups or bundles, which, on cross-section, are made up of rounded polygonal areas of varying size, the larger possessing round nuclei, while the smaller have none. Since these areas are the sections of nucleated spindle-cells, the large nucleated fields correspond to sections passing through the nucleus of the cell, while the small ones are sections of the cell falling near the pointed ends. The bundles of muscle-cells are arranged to form layers or sheets, as in the digestive tract, or net-works, as in the eye, pleura, etc. Examined in longitudinal section, or in considerable masses, it is difficult to distinguish the individual component fibre-cells, the involuntary muscle in such cases closely resembling fibrous connective tissue; however, the numerous more or less regularly disposed *rod-shaped* nuclei, and the absence of the delicate wavy fibres, together with the impression of greater density, usually suffice to establish the identity of the muscle.

FIG. 70.



Involuntary muscle in longitudinal section: the muscle-cells are often cut obliquely, and hence appear shorter than when isolated.

The connective tissue uniting the larger bundles of muscle-cells supports the blood-vessels and nerves. The larger **blood-vessels** break up into capillary net-works, which pass between the muscle-cells. The **nerves**, derived principally from the sympathetic system, likewise penetrate the intercellular spaces and terminate between the cells in the manner more fully described in the chapter devoted to nerve-endings. **Lymphatics** occur, as in parts of the digestive tract, closely associated with the muscular tissue.

STRIATED OR VOLUNTARY MUSCLE.

Striated or voluntary muscle, in addition to the extensive system attached to the skeleton, supplies the special muscles connected with many organs, including the tongue, pharynx, middle ear, larynx, upper half of the œsophagus, diaphragm, generative organs, etc. This form of muscle is composed of long, irregularly cylindrical fibres, each of which represents the high specialization resulting from the development of the single original embryonal cell; the fibre is, therefore, the structural unit of the striated muscular tissue, and corresponds to the spindle fibre-cell of the involuntary variety. The fibre of striped muscle comprises (*a*) the *sarcolemma*, (*b*) the *muscle-nuclei*, and (*c*) the *muscle-substance*.

Each fibre is closely invested by a clear, homogeneous, elastic sheath—the **sarcolemma**—which, ordinarily, so tightly adheres to the enclosed muscle-substance that the two are optically blended together; in favorable positions, as where breaks in the sarcous substance occur, or after the action of water, the sarcolemma is separated from the muscle-substance, and is then seen in profile as a delicate line spanning the break in the continuity of the fibre. The sarcolemma forms a closed sac completely enveloping the contractile substance of the fibre.

FIG. 71.

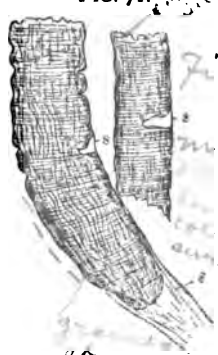

Voluntary-muscle fibres, somewhat broken after treatment with water, showing the sarcolemma (*s*) in several places.

Immediately beneath the sarcolemma, lying within minute depressions on the surface of the muscle-substance, are the **muscle-nuclei.** These are oval or fusiform, usually placed parallel to the long axis of the fibre, and surrounded, especially at their ends, by a small amount of granular protoplasm. These accumulations represent the meagre remains of the indifferent protoplasm which has not undergone conversion into the highly specialized muscle-substance of the fibre. In mammalian muscle the nuclei lie always *upon* the surface of the sarcous substance of the fibre and immediately beneath the sarco-

lemma; in the majority of other vertebrates, however, the nuclei are distributed irregularly throughout all parts of the contractile substance. These differences are well shown in the accompanying figures.

The **muscle-fibres** present alternate light and dark transverse markings, or striæ, to which the tissue owes its characteristic appearance. The highly specialized contents of the sarcolemma are composed of two substances possessing different refractive properties, that forming the dark bands being doubly refracting, or *anisotropic*, while that of the light striæ is singly refracting, or *isotropic*. When fresh or well-preserved mammalian muscle is examined under high amplification it is seen that the dark striæ, or **transverse disks**, are not unbroken homogeneous bands, but that each is composed of a number of minute prismatic elements placed side by side and separated from one another by a thin layer of a substance corresponding to and continuous with that forming the light zone. This latter, in addition, is divided transversely by a delicate interrupted line or row of dark dots—the **intermediate disk**, or *membrane of Krause*. That part of the light zone between the dim intermediate and transverse disks constitutes the **lateral disk**.

FIG. 72.

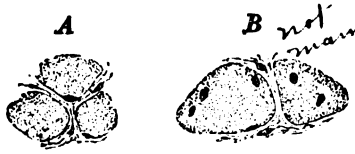

Fibres of voluntary muscle in section: *A*, human fibres, with nuclei upon the surface and beneath the sarcolemma; *B*, fibres from frog, with nuclei embedded within the muscle-substance.

FIG. 73.

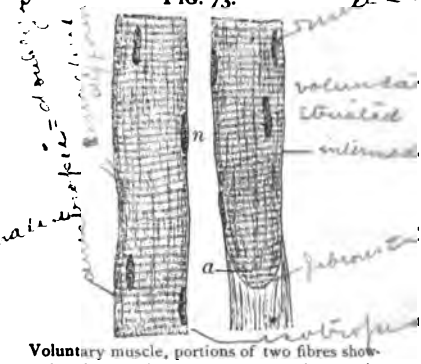

Voluntary muscle, portions of two fibres showing the characteristic transverse markings; the lighter band is divided by the row of minute beads constituting the intermediate disk: *a*, termination of muscular substance and attachment of adjoining fibrous tissue; *n*, nuclei of muscle-fibres.

The explanation of these appearances has caused many and prolonged discussions, and even at present, notwithstanding the careful study bestowed upon the subject, the exact structure of voluntary muscle must be regarded as still unsettled. Heretofore two prominent and opposed views have prevailed: the one regards the fibre as composed of parallel longitudinal rows of minute prisms forming fibrillæ (as rows of bricks placed end to end); the other considers the fibre as built up by the apposition of their disks, whose diameter corresponds to that of the entire fibre (as cheese-boxes piled one

upon the other). After treatment with alcohol, the fibres of striped muscle readily split up lengthwise into delicate bundles, which, with care, may be subdivided to such an extent that the resulting threads embrace in their width only a single row of alternating light and dark elements. These **ultimate fibrillæ** were formerly considered by Kölliker as the normal elements of the fibre; the dark prisms of these fibrillæ correspond to the **sarcous elements,** which were regarded by Bowman as the component units of muscular tissue. The transverse cleavage of the fibre following the action of diluted mineral acids, on the other hand, has been upheld as representing the natural division. According to Krause, the fibre is divided through the light bands by a number of transverse partitions continuous with the sarcolemma; these assumed septa appear as delicate faint lines—the **membranes of Krause**—and are identical with the intermediate disks already mentioned. Adopting this view, the fibre is composed of numerous thin zones or **contractile disks,** each of which embraces the dark dim band in its centre and half of the light stripe at either end. Each contractile disk is further subdivided by vertical partitions extending between the neighboring membranes of Krause, thus forming in every disk a row of compartments or **muscle-caskets.** The portion of the dim band contained within each muscle-casket has been regarded as itself being composed of a series of thin prisms of contractile substance—the **muscle-rods.**

After renewed critical study of the subject, Rollett has presented a view regarding the structure of voluntary muscle which not only offers the most plausible solution of this difficult problem, but is, likewise, in harmony with the history of the development of the tissue. According to this theory, the muscular tissue is composed of the highly specialized, darker, anisotropic **contractile substance,** and the relatively passive, lighter, semi-fluid, isotropic **sarcoplasm.** The contractile substance is arranged as delicate spindles, the apposition of whose thicker parts produces the *dim transverse disk* seen under medium amplification; at either end the spindle is prolonged as an extremely thin thread, which terminates in a minute sphere or bead; the apposition of these beads in the transverse row gives rise to the appearance of the inconspicuous line constituting the *intermediate disk*, or *Krause's membrane.* The darker anisotropic substance forms, therefore, numbers of continuous **contractile fibrillæ,** which extend in parallel bundles the entire length of the fibre; all the remaining interfibrillar space within the sarcolemma is filled with the lighter *sarcoplasm*, which appears faintly granular in preserved tissue, but is, probably, almost fluid during life. On comparing this description with the usual appearances presented by striated muscle,

it will be seen that the lateral apposition of the thicker parts of the *contractile fibrillæ* produces the dark band, or *transverse disk*, while the row of minute spherical masses appears as the inconspicuous dark line bisecting the light zone, or *intermediate disk*. The threads bridging between these beads and the chief mass of the fibrillæ are too delicate to be appreciated under ordinary powers, and that portion of the fibre corresponding to the lateral disk consequently appears as if made up of the lighter *sarcoplasm* alone.

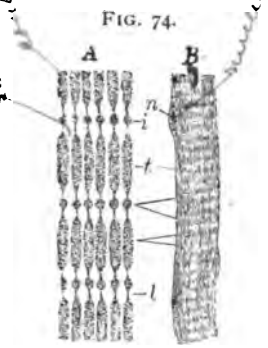

FIG. 74.

A, diagram of arrangement of the contractile substance according to the view of Rollett: the granular figures represent the contractile elements, the intervening light areas the sarcoplasm; *B*, small muscle-fibre of man; the corresponding parts in the two figures are indicated: *t*, *i*, *l*, respectively the transverse, intermediate, and lateral disks; *n*, muscle-nuclei.

In certain forms of invertebrate muscle a more complicated arrangement exists, since on either side of the *intermediate disk* a row of dark granules crosses the light *lateral disk*, forming a dim **secondary disk**; these granules are connected with the intermediate and transverse disks by delicate bridges of contractile substance, along which they occur as local thickenings. The dim transverse disk sometimes contains a central lighter band, the **median disk of Hensen,** which is due, probably, to diminished thickness of the contractile fibrils.

The **contractile fibrillæ**, however, are not uniformly distributed throughout the fibre, but are aggregated into bundles—the **muscle-columns**—each of which is enveloped in a thicker layer of the *sarcoplasm* than the partitions separating the individual fibrillæ.

In transverse section each muscle-fibre presents a number of small, polygonal, dark areas, enclosed by lighter lines, which areas, under high amplification, exhibit minute punctations. These areas are sections of the *muscle-columns* and correspond to **Cohnheim's fields,** the dots being sections of the groups of individual fibrillæ; the lighter intervening and surrounding substance is the *sarcoplasm*, thicker layers of which surround and separate the larger groups into which the muscle-columns are further collected.

The individual **muscle-fibres**, which usually are not circular in cross-section, but rather irregularly polygonal with rounded angles, are held together by a small amount of areolar tissue, the **endomysium.** They are grouped into **primary bundles,** which latter are enveloped and separated from other primary bundles by the thicker bands of connective tissue constituting the **perimysium.** The primary bundles are united to form larger secondary groups or **fasciculi,** upon the width and arrangement of which the coarseness

or the fineness, macroscopically appreciable, of the muscle largely depends. The entire muscle is invested in a fibrous sheath, the **epimysium**, derived from the denser layers of the interfascicular connective tissue.

When contraction takes place, the entire muscle becomes shorter and, at the same time, broader; the striæ also participate in the changes, becoming narrower. These phenomena, however, affect only a limited part of the fibre at one time, consecutive portions being influenced in regular sequence, so that the changes pass along the fibre as a **contraction wave**; after the passage of the wave the muscle resumes its previous condition.

FIG. 75.

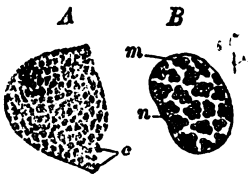

Muscle-fibres in transverse section, highly magnified: *A*, portion of human muscle: the small, irregular areas are the fields of Cohnheim (*c*): *B*, semi-diagrammatic view showing the groups of muscle columns composing Cohnheim's fields; *n*, nucleus; *m*, groups of muscle-columns.

In short muscles the individual fibres quite frequently extend the entire length; in long ones, on the contrary, the fibres are shorter than the muscle, being generally some 30–45 mm. long; sometimes, however, the fibres reach a length of 120 mm. by 10–50 mm. in width (Felix). The fibres, as a whole, are generally somewhat spindle-shaped, being slightly larger in the middle; the ends of the fibres are more or less pointed, although blunted or club-shaped, and, more rarely, branched, extremities are not uncommon. Branched and anastomosing fibres frequently occur (Gage), especially in the tongue

FIG. 76.

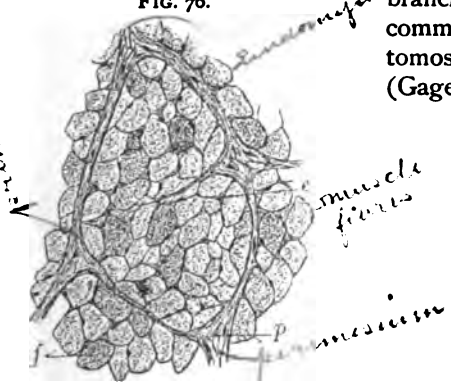

Voluntary muscle in transverse section: the irregular polyhedral areas (*f*) are the individual muscle-fibres in section, held together by the endomysium (*e*); the primary bundles of the fibres are enclosed by the denser perimysium (*p*).

FIG. 77.



Branched voluntary-muscle fibres from the tongue.

and ocular muscles. When the individual fibres do not extend the length of the entire muscle, the sarcous substance terminates in

pointed or rounded extremities, while the sarcolemma is united with the endomysium of the surrounding fibres. The muscle-substance is never directly continuous with adjacent tissues, but is always enclosed within the sac of the sarcolemma; the union between the fibres and other structures is effected by the blending of the endomysium of the muscle-fibres with the connective tissue of the attachments, whether these be tendon, periosteum, perichondrium, or subcutaneous tissue; the sarcolemma closely invests the sarcous contents, being simply received into the connective tissue without becoming directly continuous.

CARDIAC MUSCLE.

The muscular tissue of the heart, as well as of the cardiac ends of the large veins, forms an intermediate group of contractile tissue, standing in its development between the simple spindle non-striated cell on the one hand and the highly differentiated striped fibre on the other. Among the lower vertebrates (fishes, amphibians) the cardiac muscle is composed of nucleated spindle-cells possessing distinct transverse striations and often branched ends; in man and the higher vertebrates these spindle-cells give place to short, striated, cylindrical fibres, provided with lateral processes. By the apposition of these richly-branched cells a close, narrow-meshed net-work is formed, the juncture between the individual elements being indicated by transverse lines of cement-substance.

FIG. 78.

Heart-muscle, showing several joined branched fibres: around the poles of the nuclei are aggregations of pigment-granules.

The peculiarities of heart-muscle are—

1. The tenuity of the sarcolemma, the transversely striated and more faintly longitudinally marked muscular tissue being enclosed by a very delicate sheath.

2. The situation of muscle-nuclei *within* the sarcous substance, usually near the centre of the cell.

3. The characteristic arrangement of the contractile fibrillæ, since these are so placed that the peripheral fibrillæ are grouped into flat, ribbon-like muscle-columns, somewhat radially disposed about the circumference of the fibre; the remaining central portion is occupied by prismatic bundles of fibrillæ, together with the nuclei and the associated protoplasm (Ranvier, Kölliker). The small masses of protoplasm which surround the muscle-nuclei usually contain minute fat-drops and pigment-granules. The amount of **pigment** normally present varies with age, increasing from the tenth year (Maass).

Sometimes, in preserved tissue, the position of the nucleus is occupied by a clear vacuole.

Ranvier has called attention to certain differences in the muscles of the rabbit, describing two varieties—the **red** or especially dark (semitendinosus, soleus) and the **white** or pale (adductor magnus). The red muscles are characterized by slow response to electrical stimulus, less regular transverse striation, greater distinctness of longitudinal markings, and great number of round nuclei.

FIG. 79.

Heart-muscle fibres in section: the peripheral zone is composed of radially-arranged groups (*p*) of muscle-columns; a zone (*c*) of less differentiated sarcoplasm surrounds the nucleus.

The **blood-vessels** of striated muscle are very numerous. The larger vessels, together with the nerve-trunks and, less frequently, the lymphatics, are contained within the perimysium, where they give off numerous smaller branches; these, in turn, extend between the primitive bundles and break up into extremely thin capillaries, which form a characteristic rectangular-meshed net-work around the individual muscle-fibres. The longer sides of the meshes correspond with the axis of the fibre. At various points along the course of these vessels peculiar **dilatations,** or ampullæ, occur, the object of which is, probably, the relief of sudden temporary interference with the circulation during muscular contractions. The relation between the capillary blood-vessels and the muscular fibres of the heart is very intimate; in many places the vessels lie embedded within or even entirely surrounded by the muscular tissue (Meigs).

FIG. 80.



Injected voluntary muscle: the capillaries form rectangular-meshed net-works enclosing the individual fibres.

Lymphatic vessels occur in striated muscle in small numbers, but are entirely wanting in many small muscles; when distinct lymphatic vessels do occur, they are confined to the larger and looser masses of the perimysium (Kölliker).

The **nerves** supplying the striated muscle include the principal trunks which run within the perimysium, where they subdivide into smaller groups of medullated fibres, in order to reach the individual muscle-fibres; these latter receive their nervous supply at certain points only, the nerves passing to the muscle to end in the special **end-plates** in the manner described more fully in connection with the peripheral nerve-endings.

The **development** of all varieties of muscular tissue is closely related to the **mesoderm,** of which they are the direct descendants. The plain or **non-striated muscle** is formed by the differentiation,

within certain areas, of the irregular mesodermic elements into the elongated fusiform fibre-cells. In suitable preparations all gradations between the ordinary embryonal connective-tissue cells and the muscular elements may be observed, emphasizing the common ancestry of the two forms of tissue.

Voluntary muscle, representing a higher specialization, is derived from definite areas constituting the *inner* layer of the **muscle-plates,** which are referable to the early stages of the primary segmentation into *somites*. The cells of the muscle-plate soon elongate, with proliferation of the nuclei, to become the **primitive muscle-fibres.** These at first consist of greatly extended elements, possessed of numerous nuclei and composed of granular indifferent protoplasm. After a time the fibre exhibits a differentiation into **longitudinal striæ,** which, later, are supplemented by the **transverse markings** characteristic of voluntary muscle. The sarcolemma appears about the time the longitudinal markings are seen.

FIG. 81.

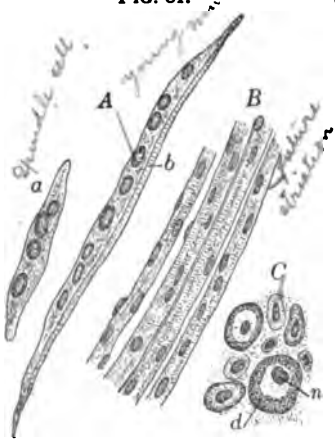

Developing voluntary muscle: *A*, young muscle-cells; *a*, very young spindle-cell; *b*, older element, exhibiting indications of future striation on one side; the remaining part of the cell is composed of the undifferentiated sarcoplasm; *B*, embryonal muscle-fibres possessing many nuclei and traces of striæ; *C*, developing muscle-fibres in section; in the larger fibres a differentiated peripheral zone of striæ (*d*) is seen in section; an area of still indifferent sarcoplasm occupies the centre of the fibre and surrounds the nucleus (*n*).

The **striations** are limited, at first, to one side of the fibre, then extend over the entire periphery, but still for some time do not reach the centre of the fibre, an inner zone of undifferentiated *sarcoplasm* occupying the middle. Later, this area also becomes converted into striated tissue, while the once numerous nuclei are reduced to the few collected beneath the sarcolemma.

Cardiac muscle, likewise, develops from the mesoderm immediately surrounding the primary heart-tubes, the contractions of the cells being displayed even before the histological differentiation becomes apparent. In its development it represents an intermediate stage, since the original spindle-cells become converted into protoplasmic fibres containing a central area which always remains less differentiated and nearer its primary condition of indifferent sarcoplasm than the peripheral portions of the fibre. The fibres of Purkinje, found in the hearts of certain ruminants, represent muscular fibres in which the sarcoplasm remains in part still undifferentiated.

CHAPTER V.

THE NERVOUS TISSUES.

THE nervous system is composed of **two principal parts**—the tissues originating and transmitting nervous impulse, the **nerve-cells** and the **nerve-fibres**, and the tissues uniting and supporting the nervous elements, the **neuroglia** and **connective-tissue framework**. While convenience warrants the consideration of the nerve-cells and the nerve-fibres as distinct elements, it must be appreciated that the nerve-fibres are only the extended processes of the nerve-cells, and that both cells and fibres together constitute the morphological units, the **neurones**, of which, in conjunction with the supporting tissues, the entire nervous system is composed.

In the simplest type of nervous system the perception of external stimuli and the generation and transmission of the responsive impulse are performed by the same cell, the more centrally lying parts of the cell serving to convey and expend the force originating within the protoplasm. Such simplicity, however, is unusual, the nerve-cell soon becoming specialized and removed from the peripheral area with which it maintains connection by means of its process—the nerve-fibre.

NERVE-CELLS.

The nerve-cells contain a large oval nucleus, and often a conspicuous nucleolus. After treatment with methylene-blue (Nissl's staining), the protoplasm is differentiated into two parts—the **stainable** and the **unstainable substance**. The former appears as masses of deeply-tinted granules, arranged in net-works, longitudinal striæ, or, as in a majority of cells, as irregular combinations of both. The unstainable substance constitutes the remaining portion of the cell-body, and, in places, may exhibit delicate striation. A variable amount of pigment is also usually present within the protoplasm.

Nerve- or ganglion-cells of man and other vertebrates differ greatly in form and size, since they may be either spherical (Gasserian, spinal, or other ganglia), ellipsoidal (spinal cord), pyriform (cerebellum), pyramidal (cerebrum), or stellate (spinal cord), and vary from 10 to 100 μ in size.

The protoplasm of every nerve-cell is prolonged into at least two and frequently several **processes**; since an apolar cell is useless, it is doutful whether such cells ever normally exist; apolar cells are frequently seen in preparations, but the absence of the

processes is only apparent, being due either to mutilation or process lying without the plane of the section; where proces really wanting, an immature or pathological condition m suspected.

The **processes of nerve-cells** are of two principal kind **protoplasmic** (*dendrits*) and the **axis-cylinder** (*neurits*) pro

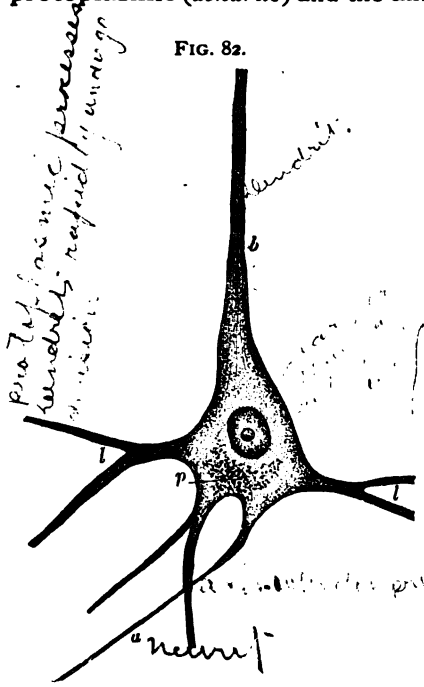

FIG. 82.

Nerve-cell from the cerebral cortex, exhibiting the striations of the protoplasm and the conspicuous character of the nucleus and the nucleolus: *p*, pigment-granules; *a*, axis cylinder process; *b*, *l*, apical and lateral protoplasmic processes.

The protoplasmic pr or dendrits rapidly u division, splitting up an dividing until the re branches form rich te **arborizations** of s threads, which freq interlace, but probably actually join, with fibrils of adjacent Nerve-cells, in one sen but nucleated local acc tions of the interfibrilla toplasm, which latter n termed **neuroplasm** liker); the large s multipolar ganglion-cell be regarded as switch- for the redistribution numerous ultimate continued into the axis ders. The fibrillæ pass divergent paths, alon several processes of th to form new combinatio relations.

The peculiarities fo supposed to constitute the distinguishing characteristics c **axis-cylinder processes** are no longer sufficient in the of recent advances in our knowledge regarding the structu the nervous system. The investigations of Golgi and others shown that, in addition to greater delicacy and a straighter c the axis-cylinder processes present variations which separat glion-cells into two groups—**cells of the first** and **cells c second type.**

Nerve-cells of the first type include elements, as those motor areas, possessing the characteristic axis-cylinder pro *directly continuous with the axis-cylinder of the nerve-fibre.*

these processes, when compared with the richly-divided protoplasmic, may be regarded as unbranched, the existence of delicate lateral offshoots, or **collateral fibrils**, has been established; these delicate branches pass backward towards the gray matter, within which they end,—often at considerable distances, in relation with other cells.

FIG. 83.

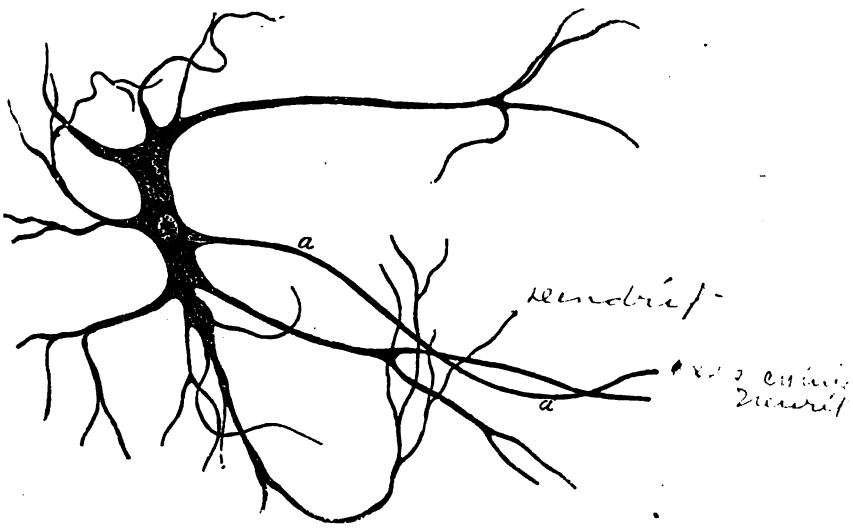

Nerve-cell from the spinal cord, isolated by maceration and teasing; the numerous branched protoplasmic processes are somewhat displaced and distorted, owing to manipulation: *a*, axis-cylinder process.

Nerve-cells of the second type are distinguished by the behavior of the axis-cylinder process; this, instead of passing into the white matter to become the centre of a nerve-fibre, *never leaves the gray matter* in which the ganglion-cell lies, but, after a longer or shorter course, rapidly *undergoes division and subdivision* in the production of a terminal arborization of delicate fibrillæ; these ramifications are limited entirely to the gray matter, their exact manner of ending and their relations to other cells varying in different parts. The free division of the axis-cylinder process does not curtail the branching of the protoplasmic extensions, which are often very conspicuous, notwithstanding the numerous bifurcations of the former. In some instances the axis-cylinder processes of cells of this type split up into fibrils which enclose the bodies of other nerve-cells within **basket-like net-works**; a notable example of this arrangement exists in the cerebellum around the cells of Purkinje.

The axis-cylinder processes usually are directed towards the nearest mass of white matter, since the axis-cylinder of the nerve-fibre is directly continuous with that of the cell. Exceptional arrangements are sometimes encountered, as where one process of a bipolar cell becomes wound about the remaining straighter fibre, constituting a **spiral process**; such cells are comparatively frequent in the sympathetic ganglia of the frog.

Ganglion-cells lie within **peri-cellular lymph-spaces**, which appear with greater or less distinctness according to the condition of the protoplasm of the enclosed cell; when this is contracted and shrunken the space is, obviously, more conspicuous than when almost entirely filled by the cell. These lymph-spaces are limited by a delicate, elastic, hyaline membrane, and lined with nucleated endothelial plates.

FIG. 84.

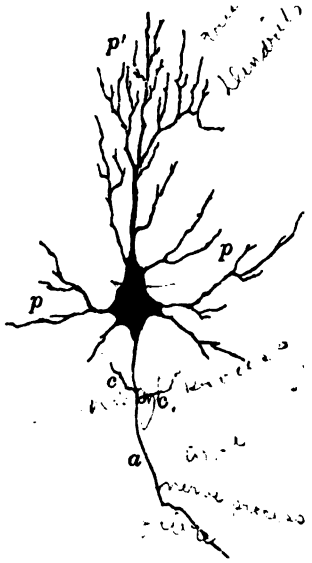

Nerve-cell of first type—from cerebral cortex: p', p, protoplasmic processes directed respectively towards the free surface and laterally; a, axis-cylinder or nerve-process giving off collateral branches, c, c. Golgi staining.

FIG. 85.



Nerve-cell of second type—from cerebellum: p, branched protoplasmic processes; c, cell-body; a, axis-cylinder process breaking up into arborization (n), but entirely confined to gray matter. Golgi staining.

FIG. 86.

Basket-work, formed by the extensions of the branched axis-cylinder process of a nerve-cell, surrounding the body of one of the ganglion-cells of Purkinje: p, base of branched process of Purkinje's cell; n, fibrils constituting basket-work.

NERVE FIBRES.

Depending upon the character of the investing coats, nerve-fibres appear as two kinds—the **medullated**, or *white*, and the **non-medullated**, or *gray*. These do not, however, constitute two sharply defined and distinct classes, but depend upon variations in the condition of fibres, which often represent both varieties at different portions of their course. Every medullated nerve-fibre, starting from the nerve-cell as the axis-cylinder process, at first lacks the

medullary substance; on obtaining the latter, it then courses as the typical medullated fibre until near its termination, where again the white substance of Schwann is wanting, the end arborizations consisting of the ramifications of the naked axis-cylinder. The majority of nerve-fibres constituting the great cerebro-spinal tract may be classed as medullated, although numbers of gray fibres likewise occur here; the non-medullated fibres are especially numerous in the sympathetic system, where they predominate, as well as in certain of the cranial nerves, as the olfactory. In other cases, as conspicuously in the pneumogastric nerve of the dog, distinct bundles of both medullated and non-medullated fibres are associated in the formation of a common nerve-trunk.

FIG. 87.

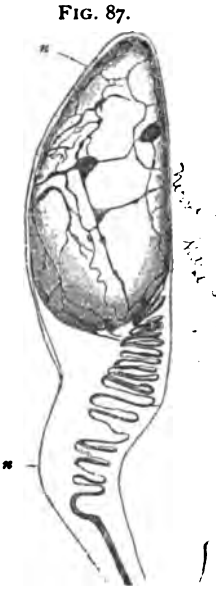

Nerve-cell from a sympathetic ganglion of frog, showing the tortuous course and terminal net-work of the spiral fibre: *n*, neurilemma continued as a delicate sheath. (After *Retzius*.)

A **typical medullated** nerve-fibre consists of the following parts:

1. The *axis-cylinder*, surrounded, possibly, by its sheath, or axilemma (Kühne).
2. The *medullary substance*, or white matter of Schwann.
3. The *neurilemma*, or sheath of Schwann, with the nerve-corpuscles.

Perfectly fresh, uninjured, **medullated nerve-fibres,** when examined by transmitted light, appear as homogeneous, hyaline cylinders, with dark contours and no appreciable structure; seen by reflected light, the fatty character of the medullary substance is indicated by the glistening appearance of the fibres, and their dull white color when viewed in masses. Shortly after death the fibres exhibit characteristic double contours, enclosing an apparently structureless centre; later, the fibres become mottled by irregular spherical masses, derived from the distorted medullary substance.

The **axis-cylinder** appears, in fresh nerves or in those fixed with osmic acid and teased, as an inconspicuous, clear, delicate rod extending along the central part of the fibre, or, perhaps, projecting beyond the outer sheaths at the broken end. The **longitudinal striations** occasionally seen, under high amplification, in carefully fixed preparations, are indications of the **ultimate fibrillæ** of which the axis-cylinder is composed; these fibrillæ are cemented together by a finely granular, interstitial substance, or **neuroplasm** (Kölliker). According to Kühne, the axis-cylinder is enveloped by a special, delicate, elastic

sheath—the **axilemma** (Kühne); other authorities regard this appearance as an artificial production. Since every axis-cylinder is connected with the corresponding process of a nerve-cell, axis-cylinders may be regarded as direct *continuations of the ganglion-cells*, their component fibrillæ forming uninterrupted paths which connect the periphery with the presiding nerve-centres. On approaching its termination, the axis-cylinder splits into smaller bundles of **component fibrillæ**; these groups subsequently divide, until, finally, the naked nervous threads reach their ultimate destination as the terminal arborizations. The nerve-fibrillæ not infrequently exhibit numerous minute fusiform enlargements or **varicosities** along their course, giving to the fibrils a characteristic beaded appearance, especially after gold-staining.

FIG. 88.

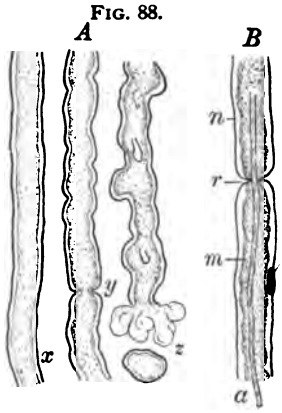

Medullated nerve-fibres: *A*, teased in salt solution, *x*, shortly after death; *y*, a node of Ranvier; *z*, post-mortem distortions of medullary substance. *B*, an isolated stained fibre; *a*, axis-cylinder; *r*, node of Ranvier; *m*, medullary substance; *n*, neurilemma, beneath which a nerve-corpuscle is seen in the lower segment.

FIG. 89.

Gold-stained axis-cylinder (*a*), showing component fibrillæ; *b*, varicose nerve-fibrillæ near their termination.

The **medullary substance**, or **white matter of Schwann**, surrounds the axis-cylinder, and forms the most conspicuous investment of the fibre. The existence of a narrow lymphatic cleft described as lying between the medullary substance and the axilemma is still uncertain. The medullary substance consists of two parts: one of these occurs as a delicate **reticulated framework**, composed of a resistant material probably resembling neurokeratin (Kühne and Ewald); the other fills the interstices of the reticulum and appears as a semi-fluid, highly refracting, fatty substance—the **myelin**—which affords protection to the enclosed axis-cylinder. Other authorities regard the reticulated framework as the effect of reagents, citing the variability in the appearances of the net-work as opposed to its presence as a normal constituent of the coat.

At regular intervals along the medullated nerve-fibres well-marked annular constrictions occur; these are the **nodes of Ranvier**, and mark the interruption of the white substance of Schwann at certain points.

Owing to the absence of the middle coat in these positions, the outer sheath, or neurilemma, is brought into contact with the continuous axis-cylinder. The portions of the fibre included between two constrictions—the **internodes,** or *internodal segments*—vary in length with the size of the fibre, being longer (about 1 mm.) in large and much shorter in thin fibres. Each internode possesses a single **nerve-corpuscle,** usually about its middle, and probably elongates during the growth of the nerve. The neurilemma is not broken by the nodes into segments, but forms a continuous sheath. When a medullated nerve-fibre branches, the bifurcation corresponds in position to a node of Ranvier.

FIG. 90.



Medullated nerve-fibres after treatment with osmic acid, from frog: *A*, fibre displays the incisions of the medulla, or Schmidt-Lantermann segments; *B*, the medullary substance exhibits a reticulated appearance.

FIG. 91.

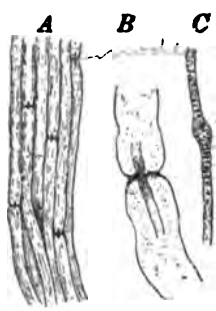

Silvered nerve-fibres: *A*, small bundle of medullated fibres displaying the silver crosses at several nodes; *B*, node of Ranvier under high power: the horizontal limb of the cross is produced by the stained intersegmental cement-substance; the vertical limb is formed by the colored axis-cylinder; *C*, silvered axis-cylinder showing a bi-conical enlargement and the transverse markings or lines of Frommann.

After treatment with silver nitrate the positions of the nodes of Ranvier are rendered conspicuous by the appearance of minute dark-brown **crosses;** the transverse arm is formed by the stained, internodal albuminous substances, forming an **annular disk,** sometimes called the constricting band (Ranvier), while a stained portion of the axis-cylinder contributes the less distinctly marked vertical lines of the cross. Closely-placed transverse markings, known as **Frommann's lines,** as well as bi-conical swellings, occasionally are noted along the axis-cylinder after treatment with silver; their significance, however, is still undetermined.

The medullary substance is very prone to post-mortem change, the coagulated or partly disintegrated myelin producing various grotesque distortions in the contour of the nerve-fibre. After treatment with osmic acid and other reagents, the white substance of Schwann displays oblique markings which are, apparently, clefts or incisions involving the middle coat; relying upon these appearances, many regard the medullary substance as made up of elongated pieces, the **Schmidt-Lantermann segments,** several of which are included within each internode.

The **neurilemma, sheath of Schwann,** or **primitive she** the outer covering of the nerve-fibre, is a delicate, homogen elastic membrane, closely investing the medullary substance resembling the sarcolemma. On its inner surface, placed at re intervals corresponding to the position of the nodes of Ranvie the **nerve-corpuscles,** meagre accumulations of protoplasm rounding the oval nuclei. The medullated fibres of the white m of the brain and spinal cord, as well as those composing the and acoustic nerves, are noteworthy as being without a neurile the surrounding neuroglia in these positions assuming the su and covering of the fibres.

The **non-medullated, pale,** or **Remak's fibres,** as indicate the first name, are devoid of medullary substance, consisting o axis-cylinder and the more or less modified n lemma; such fibres, when aggregated, appe grayish, semi-transparent bands. While e medullated nerve-fibre, before reaching it ripheral distribution, loses the white substan Schwann and becomes sooner or later a medullated fibre, the nerves constituting sympathetic system especially represent group, and evince the distinctive tenden give off branches, which unite to form the acteristic plexuses. The presence of bot rieties of fibres, however, in nerve-trun quite usual; a conspicuous example of this ciation is found in the vagus of the dog, v large bundles of both kinds are included w a common sheath.

FIG. 92.

Non-medullated nerve-fibres from the sympathetic system: the nucleated fibres join to form a plexus.

The **fibrillæ** constituting the axis-cylinde non-medullated fibres are especially distinct, feature being probably due to the gen amount of neuroplasm separating the fibrillæ; not infrequently accumulations of this interfibrillar substance occur, producing conspicuous **varicosities** seen along the course of the fibres. **nerve-nuclei** are far more numerous than in medullated fibres; are, however, irregularly distributed, lying upon the surface o fibre and beneath the outer delicate sheath. This enveloping sh —the attenuated representative of the neurilemma—is often dif or impossible to distinguish, being very thin and closely adhere the fibre. The smallest nerve-fibrils are probably without this the fibrillæ continuing as naked bundles, with the exception o imperfect covering afforded by the numerous overlying nerve-nu Non-medullated nerve-fibres are prone to form rich **plexuses**

junction of several fibres being frequently marked by characteristic triangular areas, in which a number of the nerve-nuclei are often collected.

THE NERVE-TRUNKS.

The nerve-fibres already described are associated in bundles—the **funiculi**—which, in turn, may be grouped to constitute the large macroscopic **nerve-trunks.** The funiculi differ greatly in diameter, a number of varying size being usually included within the nervous cord; in very small nerves, however, a single funiculus may suffice to form the entire trunk. While both kinds of fibres are grouped in bundles, the nerves composed principally of medullated fibres present the more typical arrangement.

FIG. 93.

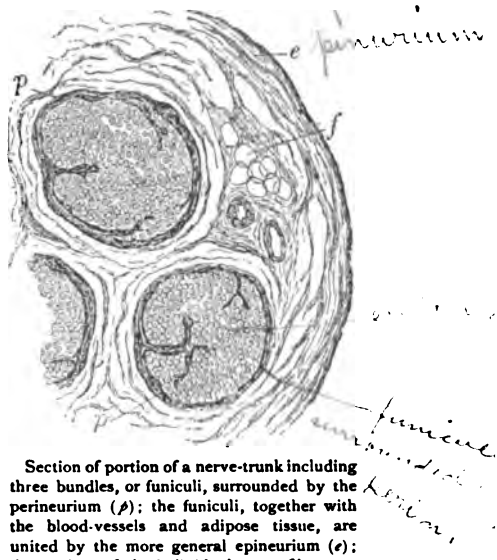

Section of portion of a nerve-trunk including three bundles, or funiculi, surrounded by the perineurium (*p*); the funiculi, together with the blood-vessels and adipose tissue, are united by the more general epineurium (*e*); the sections of the individual nerve-fibres are held in place by the endoneurium; *f*, fat-cells, near which are the sections of blood-vessels.

On transverse section of such trunks the individual nerve-fibres appear as small, round, nucleated cells, whose somewhat eccentrically placed nuclei are the axis-cylinders in section, while the contours of the cell-like areas are formed by the sections of the neurilemma; the shrunken granular or concentrically marked masses within the apparent cell-walls are the remains of the medullary substance. These sections of the fibres are held in place by a delicate connective tissue—the **endoneurium**—extending among and surrounding the individual fibres. When the nerve-bundle, or funiculus, is small, the nerve-fibres are uniformly distributed, and it is spoken of as **simple**; when large, however, the fibres are usually divided into irregular groups by stronger fibrous trabeculæ, thus forming a **compound funiculus.** The individual nerve-fibres vary greatly in diameter (from 2 to 20 μ), even adjoining fibres often exhibiting marked differences. In general, the cerebro-spinal nerves possess the largest fibres, the sympathetic much the smallest (2 to 4 μ), while the components of many of the cranial nerves occupy an intermediate position.

Each **funiculus** is invested by a robust connective-tissue sheath—the **perineurium**—between the fibrous lamellæ of which are seen

the nuclei of the endothelioid plates lying within the interlamellar lymphatic spaces. The endoneurium is directly continuous with the perineurium, of which it is the intrafunicular extension.

Where a nerve-trunk comprises several funiculi, these are held together and enveloped by a loose general connective tissue—the **epineurium**—which supports the blood-vessels and lymphatics, and often contains masses of adipose tissue; the external layer of the epineurium is usually somewhat condensed.

FIG. 94.

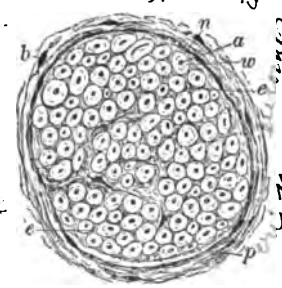

A single funiculus more highly magnified; the apparent small nucleated cells are sections of the nerve-fibres and their axis-cylinders: *a*, axis-cylinder; *w*, medullary substance; *n*, neurilemma; *e*, endoneurium; *p*, perineurium; *b*, connective-tissue cells of same.

When the funiculus divides, the new bundles receive a prolongation of the perineurium, the investment becoming thinner with each successive division. On nearing their final destination, the funiculi break up into small groups or single fibres, which are covered by an attenuated extension of the formerly robust perineurium; this investment constitutes the **sheath of Henle**, and consists of a delicate fibrous envelope lined with endothelioid plates; in some cases these latter alone represent the entire sheath.

The larger **blood-vessels** enclosed within the epineurium give off branches, which surround the funiculi and break up into capillaries passing within the endoneurium among the fibres.

The **lymphatics** are represented by irregular clefts within the endoneurium, which are connected with the interlamellar spaces of the perineurium; from these the lymph is taken up and carried off by the more definite lymphatic channels running within the epineurium.

The **nerves** of the larger trunks—the **nervi nervorum**—are distributed within the epineurium, and are said to terminate, in many cases, in special bodies which resemble in general type the spherical end-bulbs of Krause.

THE SUPPORTING TISSUES OF THE NERVE-CENTRES.

The essential constituents of the nervous system, the cells and fibres, when associated in large masses, as in the cerebro-spinal tract, are held in place and supported by two varieties of **sustentacular tissue.** On examining suitably prepared sections of these organs, the cells and fibres appear everywhere to be embedded within a finely **reticulated ground-substance**, whose composition is especially complex in the gray matter. The basis of this reticulum is the

sustentacular tissue

neuroglia, a peculiar form of ectodermic tissue, with, therefore, close relations to the neurogenetic tract. **Neuroglia** consists of extremely branched elements, or **glia-cells,** whose numerous processes break up into brush-like bundles of delicate fibrils, which pass in all directions among the nervous elements, filling more or less completely all interstices. The body of the glia-cells is frequently stellate, possessing a nucleus and staining intensely with certain dyes. The demonstration of these neuroglia elements is very striking in Golgi silver preparations, where they appear as dark, spider-like figures which send out delicate fibrils in all directions. In the embryo the neuroglia consists of long, delicate fibrils which radiate from the neural tube; later, these fibres become broken up into shorter threads which interlace and form the supporting tissue. The groundwork surrounding the nerve-fibres within the white matter serves the purpose of covering as well as of support, and replaces the neurilemma.

FIG. 95.

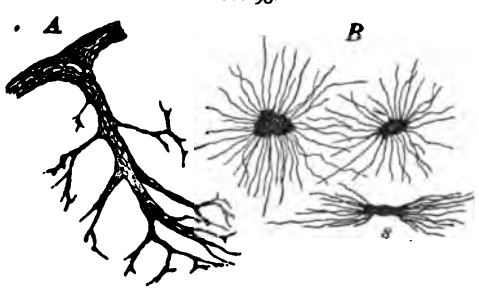

Supporting tissues of nerve-centres: *A*, extensions of the peripheral connective tissue of the pia mater; *B*, neuroglia-cells, one of which is seen in profile (*s*). Golgi staining.

In addition to the dense reticulum formed by the neuroglia, constituting the special sustentacular tissue of the nervous system, prolongations from the enveloping pia mater in places penetrate within the nervous masses and contribute **connective-tissue trabeculæ,** which form a supporting framework for the blood-vessels. These connective-tissue ingrowths constitute the septa, which in many places, as conspicuously in the spinal cord, accompany the blood-vessels into the nervous substance. The finer ramifications of these partitions fade away in delicate extensions which mingle with the fibrils of the neuroglia-cells. It is evident, therefore, that the supporting tissue of the nervous system can no longer be regarded simply as a form of connective tissue, since, in addition to the undoubted connective tissue present, the larger part is contributed by the peculiar ectodermic structure, the neuroglia.

THE STRUCTURE OF GANGLIA.

Along the course of certain nervous cords, such as those constituting the sensory roots of the spinal nerves, the trunks of many of

the cranial nerves, and especially of the sympathetic system, groups of nerve-cells occur associated with the nerve-fibres in the form of **ganglia**; these may be large and conspicuous masses, as the Gasserian

FIG. 96.

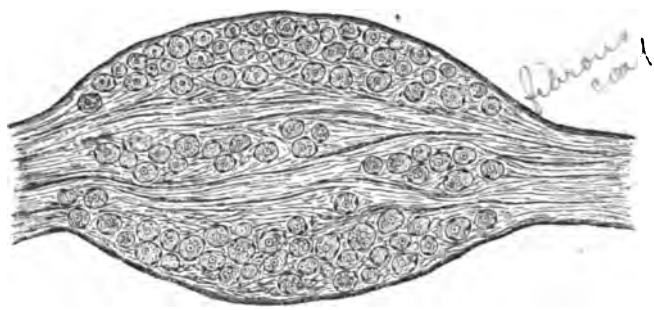

Spinal ganglion, in longitudinal section, from cat: the groups of nerve-cells lie embedded among the bundles of the nerve-fibres.

ganglion of the trifacial nerve, or their size may be microscopic, as many of the interstitial ganglia connected with the distribution of the sympathetic fibres.

The **outer covering** of the ganglion consists of a fibrous envelope, a condensation of the adjacent epineurium in many cases, from which prolongations extend among the nervous elements, where they break up into delicate bundles of connective tissue, which serve for the union and the support of the cells and the fibres. Some of the **nerve-fibres** pass through the ganglion on their way to more distant points without joining any of the nerve-cells, while many others end in or take origin from these elements. The presence or absence of the medullary coat depends upon the character of the component fibres of the nerve-trunk; before joining a nerve-cell, however, the medullary substance disappears, while the neurilemma of the fibre continues and becomes the **nucleated capsule**

FIG. 97.

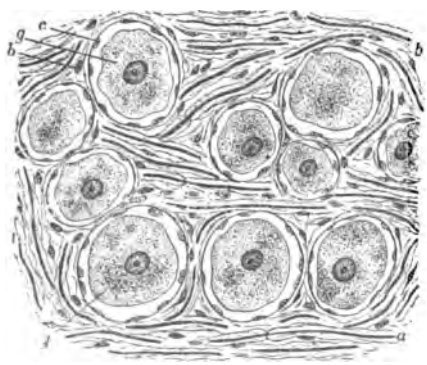

Section of spinal ganglion more highly magnified: *g*, the nerve-cells, cut in various planes, surrounded by the nucleated sheath (*c*); *a*, the medullated nerve-fibres, on which several nodes of Ranvier are seen; *b*, cells of the supporting connective tissue.

enclosing the individual **nerve-cells.** These latter possess, in general, a spherical form, and are usually provided with one or two, seldom more, processes; in the bipolar cells the processes frequently pass from opposite poles to become continuous with the afferent and efferent fibres. In the ganglia of some of the lower vertebrates bipolar cells occur in which one process becomes invested by the turns of the other or spiral fibre. Unipolar cells exist in which the single process divides into T-branches extending almost at right angles; such cells occur also in man.

The **development** of all nerve-fibres and nerve-cells must be referred to the elements derived from the invaginated **ectoderm** forming the neural tube. Without entering upon an exhaustive account of the process, many details of which are still uncertain, it may be accepted that the primary neural ectoderm differentiates into two varieties of cells—the **neuroblasts** and **spongioblasts.** The nerve-fibres are formed as outgrowths from the primitive nerve-cells or neuroblasts. This may take place either in *one direction* alone, from the centre towards the periphery (*centrifugally*), as in the formation of the efferent fibres of the motor-nerve roots of the spinal cord; or, as in the production of the afferent (sensory) nerves, the neuroblasts may be somewhat removed from the central nervous mass, occupying the position of the spinal ganglia, and send out fibre-processes in *two directions*, one set growing into the nerve-centre (*centripetally*), while a second group of fibres extends towards the periphery (*centrifugally*). In *all* cases the nerve-fibres are formed as *outgrowths from the primary nerve-cells*; in later stages the cells concerned in extending the nervous path may disappear after the establishment of the tract. The **spongioblasts,** on the other hand, are especially concerned in the production of the neuroglia-cells, these ultimately becoming transformed into the close reticular formation supporting the nervous elements.

FIG. 98.

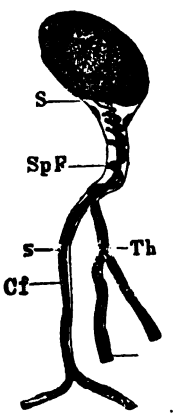

Ganglion nerve-cell with spiral fibre from the sympathetic of frog: *Sp F*, the spiral fibre surrounding the straight process (*Cf*) and dividing at a node of Ranvier (*Th*); *s*, neurilemma. (After *Schiefferdecker.*)

The **nerve-fibres** are at first pale and possess neither medullary substance nor neurilemma. The acquisition of the white substance of Schwann occurs much later, the exact mode of its production, however, being by no means certain; whether the medullary substance owes its formation to the influence of the axis-cylinder, or its origin must be referred to the more or less direct agency of the ele-

nts represented by the nerve-nuclei, future investigation must ermine. If traced to the axis-cylinder, the sheath must be classed ectodermic tissue; as mesodermic, on the other hand, if referred he nerve-corpuscles. The period at which the **medullary coat** ears in the various groups of nerves is variable, but constant for en tracts; account has been taken of this fact with great advantage the laborious investigations of tracing the path of many nerve-cts composed of medullated fibres. The **neurilemma** may be arded as certainly derived from the differentiation of surrounding sodermic cells, as likewise the more general connective-tissue velopes constituting the endoneurium, the perineurium, and the neurium of the nerve-bundles.

CHAPTER VI.

THE PERIPHERAL NERVE-ENDINGS.

Terminations of Sensory Nerves. A medullated nerve, in passing to its ultimate distribution, first loses the medullary substance, or white matter of Schwann, which ends abruptly at some bifurcation of the nerve corresponding in position to a node of Ranvier. The fibre continues for a variable distance non-medullated, being covered with the neurilemma and the nerve-corpuscles; these coats become reduced gradually until the neurilemma disappears, the nerve-nuclei then alone remaining as an imperfect investment of the axis-cylinder. The nuclei soon occur less frequently, until finally they disappear and the bundles of nerve-fibrillæ, by this time greatly reduced owing to repeated division, continue as **naked axis-cylinders**; these unite to form a widely-meshed **ground-plexus,** possessing characteristic triangular, nucleated nodal points where the bundles of fibrillæ meet.

FIG. 99.

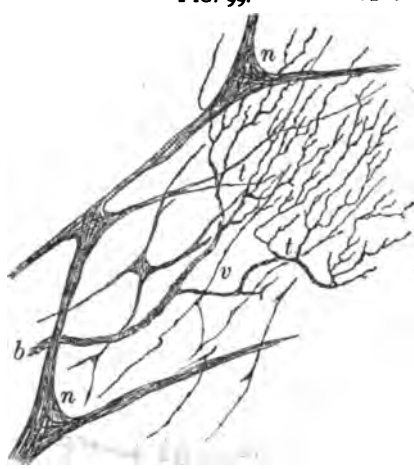

Termination of sensory nerve fibres; portion of the plexuses occupying the anterior layers of the cornea; gold preparation: *n*, *n*, nodal points of the coarser ground-plexus; *b*, small bundle of nerve-fibrils which breaks up into the terminal arbor (*t*) of ultimate fibrillæ; *v*, fibrils showing varicosities.

The axis-cylinders sooner or later break up into their component **primitive fibrillæ,** which frequently interlace to form rich net-works, or **terminal plexuses,** within the connective tissue of the organ supplied; these net-works quite often are situated immediately beneath the epithelium; in immediate proximity with the basement membrane fine fibrillæ emerge from the plexus, enter the epithelium, and terminate in pointed or club-shaped **free endings** between the epithelial cells. The nerves of common sensation frequently end in this manner, including, probably, many nerves of the skin, cornea, and mucous membranes.

Many sensory nerves, however, terminate in **special endings** of

varying complexity: of such specialized structures over a dozen forms have been described; since a number of these occur only among the lower vertebrates, the more important types alone will be here considered.

The special **sensory nerve endings** may be grouped as—

1. *Tactile Cells.*
2. *Tactile Corpuscles.*
3. *End-Bulbs.*

The **tactile cells** are found within the deeper layers of the epidermis or the adjacent stratum of the corium, and may be either **simple** or **compound**; the former are oval nucleated elements, 5–12 μ in size, and resemble ganglion-cells. The centrally-directed portion of the cells is embraced by a peculiar crescentic expansion—the **tactile meniscus**—with which the nerve-fibre is probably connected.

FIG. 100.

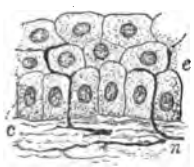

Termination of sensory nerve-fibres within the epidermis; gold preparation: *e*, deeper layers of epidermis; *c*, subjacent connective tissue; *n*, nerve-fibrillæ penetrating among the epithelial cells.

Where two or more such cells are associated to receive the nerve-fibre, a **compound tactile cell** results; the *corpuscles of Grandry* and *of Merkel*, found respectively in the epidermis of birds and of mammals, are examples of such structures. The medullated nerve-fibre, on meeting the cells, loses its neurilemma and Henle's sheath, these coverings becoming fused with the connective-tissue capsule of the corpuscle; the axis-cylinder passes between the cells, to become lost within an intercellular flattened **tactile disk**; the medullary substance terminates at the point where the axis-cylinder enters the disk.

FIG. 101.

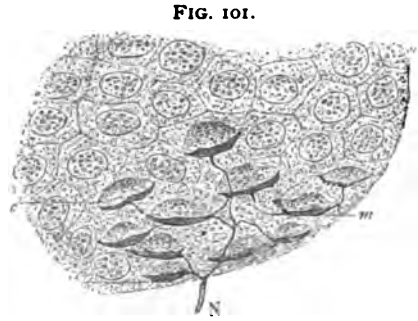

Special nerve-endings within the epidermis; gold preparation: *N*, nerve-fibre entering the epithelium and dividing into the fibrils which are connected with the tactile disks (*m*); upon these latter rest the tactile cells, *c*. (After *Ranvier*.)

The dark stellate figures sometimes seen in gold preparations of the epidermis, lying between the epithelial cells, and known as the *cells of Langerhans*, do not represent nerve-endings, as formerly claimed, but are probably migrated wandering cells.

The more elaborately arranged compound tactile cells and the simpler tactile corpuscles, such as the spherical end-bulbs of the conjunctiva, are closely related, their differences being but slight; the various

tactile corpuscles present increasing degrees of complexity of structure, the most highly specialized ending of this class being the *tactile corpuscle of Meissner*, found in the skin of the palmar surfaces of the fingers and of the toes.

FIG. 102.

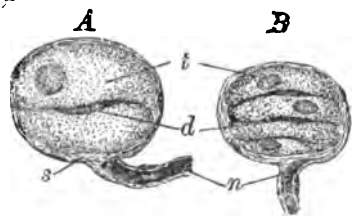

Tactile corpuscles from the bill of duck: *A*, simple, *B*, compound, corpuscle; *t*, tactile cells; *d*, tactile disks; *n*, medullated nerve-fibres entering the nucleated capsules (*s*) into which the neurilemma continues.

The corpuscles of Meissner are oval elliptical bodies, 45–140 μ long and 35–55 μ wide, situated usually at the apices of the papillæ of the corium; they possess numerous transversely-placed nuclei, which, with the edges of the indistinctly defined tactile cells, produce the characteristic transverse or somewhat spiral markings. Each corpuscle is supplied with one or two, sometimes three or four, medullated nerve-fibres, which are invested with Henle's sheaths; the fibres may undergo numerous windings before entering the corpuscle, the sheath of Henle, together with the neurilemma, becoming continuous with the fibrous envelope of the corpuscle. The nerve-fibres retain their medullary substance for a short distance, but later lose this sheath and break up into a number of non-medullated fibres; these latter subdivide into fibrillæ, which pursue a spiral course throughout the corpuscle, being connected here and there with **terminal disks.** The compressed tactile cells themselves are usually indistinctly defined, the transversely-placed nuclei and the outlines of the cells producing the transverse markings. A large number of the nuclei seen, however, belong to the superficial layers contributed by the connective-tissue coverings. As to the exact course and mode of termination of the nerve-fibrillæ within these tactile corpuscles, much uncertainty still exists.

FIG. 103.

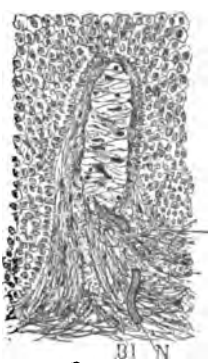

Tactile corpuscle of Meissner from the skin of human toe: *N*, the nerve entering the complicated group of tactile cells composing the corpuscle; *Bl*, blood-vessel accompanying the nerve-fibre. (After *Schiefferdecker.*)

The **spherical end-bulbs** of the conjunctiva and of other mucous membranes, as well as the genital and the **articular nerve-corpuscles,** must be included in this class of nerve-endings; these bodies are all formed on the same general plan, the differences in their structure being limited to the details of arrangement.

The **End-Bulbs.** The third group of special nerve-terminations embraces the nerve-endings of a *cylindrical type* in contrast to the

spheroidal form of those already considered. Just as in the preceding group, so here the simpler endings lead from the tactile cells to the more highly specialized structures; the *cylindrical end-bulbs* of the conjunctiva of the calf are the simplest members of this group, while the *corpuscles of Vater*, or the *Pacinian bodies*, are its most highly specialized representatives.

FIG. 104.

Simple spherical end-bulb from the human conjunctival mucous membrane: *n*, the medullated nerve-fibre which disappears within the capsule. (After *Krause*.)

FIG. 105.

Genital corpuscle from the human clitoris; this ending represents a group of partly fused simple spherical end-bulbs: *n*, nerve-fibres entering the capsule. (After *Krause*.)

The nerve-endings of this class are composed of three parts—the **capsule**, the **inner bulb**, and the **nerve-fibre**. Upon the arrangement and development of these the differences distinguishing the individual endings chiefly depend.

In the simpler forms of end-bulbs, as those found in the conjunctiva and the oral mucous membrane of certain mammals, the body is borne upon a stalk, which contains the medullated nerve-fibre and, possibly, a minute blood-vessel enveloped in connective tissue. The sheath of Henle investing the nerve is prolonged into the nucleated *capsule*. The latter encloses a conspicuous cylindrical mass of granular or faintly striated pale substance—the **inner bulb**—within which the free axis-cylinder lies, terminating often in a slightly marked knob-like expansion. The medullary substance ends where the nerve-fibre enters the inner bulb.

FIG. 106.

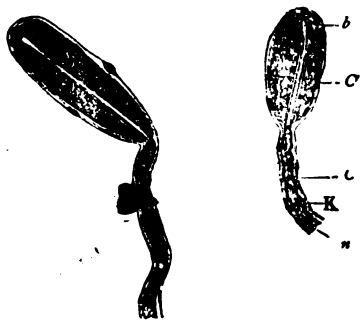

Simple cylindrical end-bulbs from the scleral conjunctiva of calf: *n*, nerve-fibre passing into the inner bulb (*b*); *K*, neurilemma which, with perineurial sheath (*C*), continues as the capsule, *C'*. (After *Schiefferdecker*.)

Further complexity in the structure of the end-bulbs is largely due to elaboration of the capsule; this latter becomes laminated and very thick, while the inner bulb likewise exhibits new details of structure. Since the intermediate forms in the series of end-bulbs do not occur in man, the highly specialized **corpuscles of Vater**, or the Pacinian bodies, may at

once be considered. These structures, widely distributed in man and mammals, are elliptical, semi-transparent bodies, some 2–3 mm. long and half as broad, which occur along the nerves supplying the skin, especially of the hands and feet, the external genitalia, the joints of the extremities, the periosteum of certain bones, the peritoneum, and many other localities. Of the three component parts of the typical end-bulb, the **capsule** has undergone the greatest development in the corpuscles of Vater, being composed of 25–50 concentric connective-tissue **lamellæ**, each of which possesses an outer transverse and an inner longitudinal layer of fibres, and is lined by a single layer of endothelial cells; the nuclei of these plates are seen in profile throughout the capsule. The individual lamellæ

FIG. 107.

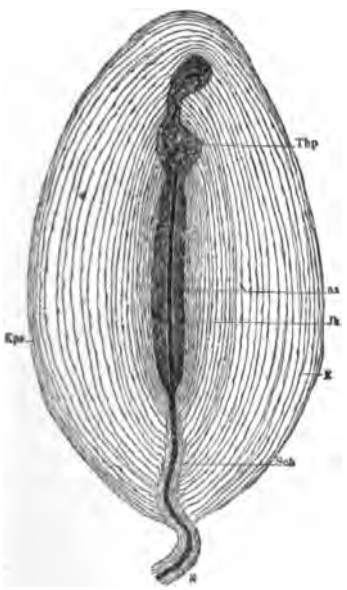

Corpuscle of Vater, or Pacinian body, from the mesentery of cat: *N*, nerve-fibre enclosed within the perineurial sheath, with which the lamellæ of the capsule (*Kps*) are connected; *K*, nuclei of the endothelial plates of same; *Jk*, inner bulb enclosing the axis-cylinder (*ax*), which at *Thp* divides into the terminal branches. (After *Ranvier*.)

FIG. 108.

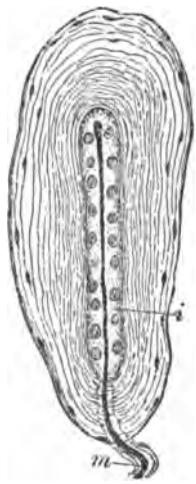

Herbst's corpuscle from the bill of duck: *m*, medullated nerve-fibre passing into the interior of the capsule, where the axis-cylinder lies within the granular inner bulb (*i*) surrounded by a row of nuclei; the spindle nuclei appear between the outer and less closely placed lamellæ of the capsule.

are separated by a clear serous fluid, which is largest in amount between the peripheral layers, since the lamellæ immediately surrounding the inner bulb are thinner and more closely placed. The lamellæ of the capsule are often united along a longitudinal area—the **intracapsular ligament**—which corresponds to the course by which the nerve-fibre gains entrance to the inner bulb; occasional trabeculæ

also pass between the adjacent lamellæ. After silver stainings the corpuscles of Vater appear to be completely invested with a mosaic of endothelial plates; these markings are due to the cells which line the inner surface of the outer lamellæ.

The core of the corpuscle is occupied by a light granular or faintly striated cylindrical mass—the **inner bulb**—composed, seemingly, of an almost homogeneous tissue, closely resembling protoplasm, in which nuclei and indistinct fibrils sometimes are seen. Within and corresponding to the axis of the inner bulb lies the **free axis-cylinder,** ending frequently in a slightly expanded terminal knob; the medullary substance surrounds the axis-cylinder as far as the inner bulb, where it disappears. The small artery usually accompanying the nerve-fibre within the stalk of the corpuscle gives off fine branches to be distributed to the outer layers of the capsule.

The **corpuscles of Herbst,** found in birds, closely resemble the Vaterian corpuscles of mammals, possessing, however, a less developed capsule and an inner bulb beset with a single or double row of nuclei.

From the foregoing sketch it will be seen that, taking the tactile cells as a ground-form, the special nerve-endings are developed along two lines: one type is represented by the **spherical tactile corpuscle,** composed of winding nerve-fibres bearing tactile disks placed between tactile cells and enveloped within a capsule; the other by the **cylindrical end-bulb,** in which the central nerve-fibre lies within a cylindrical inner bulb, enveloped by a capsule developed to a greater or less degree. As the highest representative of the first group stand the complex *tactile bodies of Meissner;* of the second group, the *corpuscles of Vater.*

The following table indicates the relations of some of the principal forms of special sensory nerve-endings:

Simple Tactile Cells.

(*Ground-Form.*)

Epidermis of man and mammals.

Compound Tactile Cells.

Grandry's Corpuscles: Epidermis of birds.
Merkel's Corpuscles: Epidermis of mammals.

Tactile Corpuscles.

(*Spherical.*)

Spherical End-Bulbs: Conjunctiva and mucous membranes of man.

Leydig's Corpuscles: Skin of amphibians and reptiles.
Genital Corpuscles: Clitoris, penis, etc., of man, etc.
Articular Corpuscles: Phalangeal joints of man, etc.
Tactile End-Bulbs: Skin of bill, lip, etc., of birds.
Meissner's Corpuscles: Cutis of hands, toes, etc., of man.

End-Bulbs.

(*Cylindrical.*)

Cylindrical End-Bulbs: Conjunctiva and mucous membranes of mammals.
End-Capsules: Buccal glands of hedgehog; tongue of elephant.
Herbst's Corpuscles: Skin and mucous membranes of birds.
Key-Retzius Corpuscles: Skin of bill of birds.
Vater's Corpuscles: Cutis and many other situations in man and mammals.

NERVE-ENDINGS IN MUSCLE AND OTHER ORGANS.

Non-Striated Muscle. The sympathetic nerves supplying this tissue are composed of bundles of non-medullated nucleated fibres, and are enveloped by a thin perineurium; these fibres are associated as small bundles and unite to form the **ground-plexus,** in the nodal points of which ganglion-cells usually occur. From this net-work

FIG. 109.

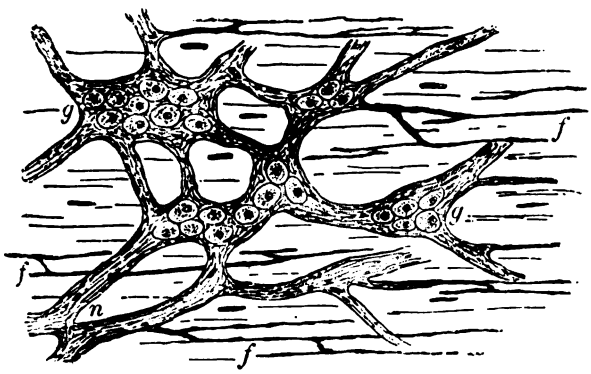

Nerves of involuntary muscle from the plexus of Auerbach of intestine of dog; gold preparation: *g*, nodal points of plexus containing ganglion-cells; *n*, bundles of non-medullated nerve-fibres; from these the small branches (*f*) extend which give off the fibres directly supplying the muscular tissue.

small branches are given off, which join to make up the **intermediate plexus**; fine bundles of **intramuscular fibrillæ** further extend directly to the contractile tissue. The fibrillæ pass between the

primary bundles of the muscle-cells, and probably terminate in finely pointed or slightly thickened **free ends**; the direct connection between the nerve-fibrillæ and the nuclei of the muscle-cells is, at best, extremely doubtful.

Striated Muscle is supplied with both motor and sensory nerves; the latter are distributed as a loose net-work, the fibrillæ of which apparently terminate between the individual muscle-fibres.

FIG. 110.

Nerves of voluntary muscle of rabbit; gold preparation: *n*, small bundle of medullated motor nerve-fibres, from which fibres pass to the individual muscle-fibres (*m*) and bear the motor end-plates; *s*, some of the sensory nerve-fibres supplying the muscle.

The medullated nerve-fibres composing the motor supply of a voluntary muscle unite to form an **intramuscular plexus**, from which small bundles of nerve-fibres spring, and subsequently divide in such manner that a single medullated axis-cylinder passes to each muscle-fibre. At the point where the nerve pierces the sarcolemma the medullary substance abruptly ends, while the neurilemma, blended with the sarcolemma, joins the perineurial (Henle's) sheath in forming the **telolemma**, or the sheath investing the end-organ. The axis-cylinder, now beneath the muscle-sheath, continues upon the surface of the sarcous substance, and, later, breaks up into a number of somewhat tortuous **ultimate fibrillæ**, which irregularly unite and end in thickened bulbous extremities. The terminations of the nerve are embedded in a flattened nucleated mass—the **sole-plate**—composed of soft faintly granular protoplasm, which resembles sarcoplasm and is closely applied to the surface of the muscular substance; this mass, together with the embedded nerve-fibrillæ, constitutes the motor disk, or **end-plate.**

FIG. 111.

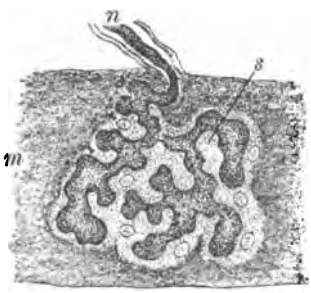

Motor end-plate of voluntary muscle from rabbit: *n*, medullated nerve-fibre passing to muscle (*m*'), on the surface of which the axis-cylinder ends in the dark arborescent figure; the latter lies embedded within the nucleated sole-plate (*s*) composed of granular protoplasm.

Each muscle-fibre possesses usually but a single end-plate; in exceptional cases, however, there may be two or more; likewise,

several nerve-fibres instead of a single one may supply the end-plate.

The nerve-endings in the voluntary muscle of amphibians and bony fishes differ from the foregoing in the absence of the granular protoplasmic disk, and in the more diffuse disposition of the terminal nerve-fibres. The axis-cylinders, in these cases, branch into fibrillæ which extend for some distance parallel to the axis of the muscle-fibre and end in slight bulbous expansions; granular pyriform nuclei also occur along the course of these fibrillæ.

The **muscle-spindles** described by Kühne are considered as special sensory nerve-endings. They contain muscle-fibres and the terminal arborizations of the nerve surrounded by an envelope of connective tissue.

Tendon. In addition to the **sensory end-plates** of tendon, studied by Kölliker, Rollett, Sachs, Golgi, and others, which consist of an intricate net-work of pale non-medullated fibres, Golgi has described peculiar nerve-endings in tendon to be found in the immediate vicinity of the union with the muscle.

FIG. 112.

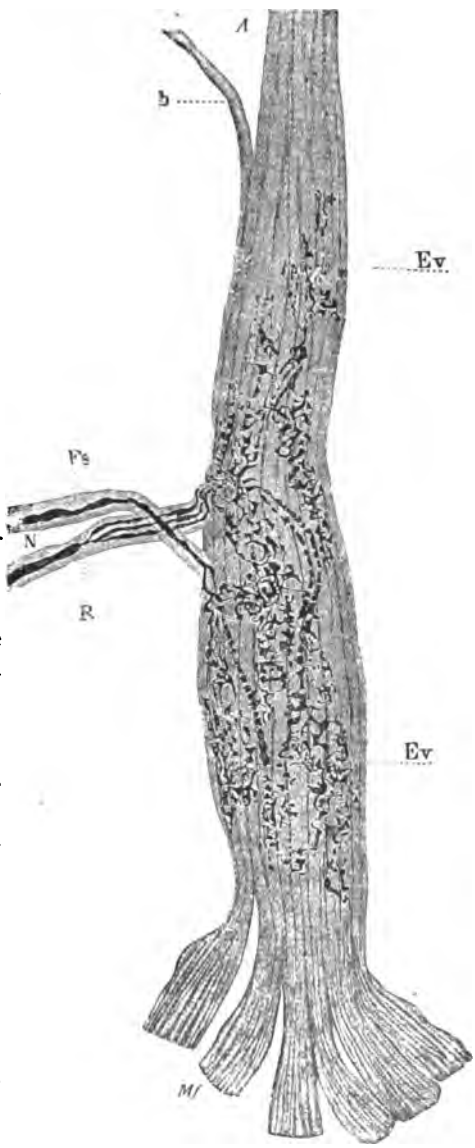

Golgi's corpuscle or tendon-spindle from the human tendo Achillis; gold preparation: *N*, nerve-fibres surrounded by the perineurial sheath (*Fs*) spreading out into the reticular ramifications (*Ev*) of the axis-cylinder; *A*, the tendon-bundles, one of which is separated at *b*; *Mf*, the muscle-fibres; *R*, node of Ranvier. (After *Ciaccia*.)

These **tendon-spindles** appear as sharply-defined, greatly-elongated, elliptical masses (in the rabbit .25–.75 mm. long and .02–.05 mm. broad), one end of which extends upon the tendon, while the muscular pole is usually, although not always, continuous with the adjoining muscle-fibres. The tendon-spindle is composed of a distinct connective-tissue capsule, which, embracing two or more of the primary bundles of the tendon, becomes united with the sheath of the latter; the inner surface of the spindle is covered with endothelial plates. Medullated nerve-fibres to the number of two, three, or four join the organ near its widest part, sometimes, however, at one end; after repeated division as medullated fibres, the nerves spread out on the surface of the tendon as pale non-medullated fibres, whose axis-cylinders unite to form a richly but irregularly meshed arborescent figure; the ultimate fibrillæ, in addition to the net-work, present numerous knobbed free ends.

Blood-Vessels. The blood-vessels are accompanied by nerve-fibres derived from the sympathetic system; in addition to the pale fibres, a few medullated ones usually take part in the production of the irregular net-work surrounding the larger vessels. From this plexus fine branches are given off, which ultimately end between the muscular bundles of the media and within the fibro-elastic tissue of the adventitia. The capillaries are accompanied and partly surrounded by delicate non-medullated nerve-fibres.

FIG. 113.

Nerve-fibres accompanying a small artery (*v*), from the mesentery of rabbit; gold preparation.

The muscular tunics of the large **lymphatic trunks** are supplied with nerves in a manner similar to the blood-vessels; the delicate, thin-walled lymphatics are probably without nerves.

Glands. A detailed account of the nervous supply of the larger glands will be given in connection with the consideration of the several organs; it may be mentioned here, in general, that the more important glands are provided, in addition to the medullated nerves often found passing through the substance of the gland in their course to the contiguous skin or mucous membrane, with nervous bundles in which non-medullated fibres predominate, but in which some medullated ones also occur. These bundles form an **interlobular** plexus, rich in ganglion-cells, which accompanies the larger excretory ducts and blood-vessels, and gives off a few branches to be distributed to the muscular coats of these tubes. Thin bundles of pale fibres bear the smaller ducts company as far as the primary groups of acini, and there break up into minute bundles of free axis-cylinders passing

between the acini. The nerve-fibrillæ may be traced readily to the membrana propria of the acini, around which a net-work is spun; regarding their ultimate distribution and relation to the secreting cells much uncertainty still exists, notwithstanding many elaborate investigations and positive statements.

The exact mode in which the nerves terminate within the acini is still doubtful; it is probable, however, that the fibrillæ end between, or in apposition with, the ends of the secreting cells directed towards the basement-membrane; proof of direct connection between the nerve-fibrillæ and the secreting cells, as often described, is wanting. Likewise the mode of termination of the medullated fibres, which, as already stated, contribute to form the interlobular net-work, is uncertain; in some glands, as in the pancreas of the cat and the buccal glands of the hedgehog, they terminate in special nerve-endings resembling the corpuscles of Vater.

FIG. 114.

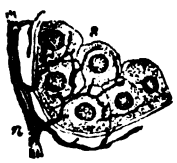

Nerves ending in glands, from the parotid of dog; gold preparation: *s*, group of secreting cells of single acinus; *n*, nerve-fibre lying outside the membrana propria and giving off twigs which enclose the acinus within a net-work of terminal nerve-fibrillæ.

The perceptive apparatus connected with the termination of the **nerves of special sense** include the highly specialized epithelial structures made up of the **neuro-epithelium**; the rod- and cone-cells of the retina, the hair-cells of the internal ear, the olfactory cells of the nasal fossæ, and the gustatory cells of the taste-buds are important examples of such tissue. In these structures the specialized epithelium forms the apparatus for the reception of the external stimuli, while the nerve-fibres provide for the further transmission of the impressions so appreciated. The relation between the receptive cells and the conducting nerve-fibres must be, evidently, very intimate; a direct anatomical continuity between the two, however, must be regarded as extremely doubtful in the light of recent research.

CHAPTER VII.

THE CIRCULATORY SYSTEM.

THE circulatory apparatus comprises the channels for the conveyance of the blood-stream, the vessels, and the dilated and specialized portion of the vascular tube, constituting the heart, for the propulsion of the current. In development and structure the several parts of the vascular system possess much in common, although variations in the details of the walls of the blood-channels suffice to distinguish the different portions.

THE BLOOD-VESSELS.

The blood-vessels occur in three forms, as **arteries, veins,** and **capillaries,** the latter constituting an expanded system of thin-walled tubules, intimately related to the organs, and especially designed to facilitate the interchanges between the nutritive current which they carry and the tissues through which they pass.

The **arteries** possess three coats—the inner, or **intima,** the middle, or **media,** and the external, or **adventitia.** Since these coats vary in relative thickness and in details of structure with the size of the vessel, it is usual to classify

FIG. 115.

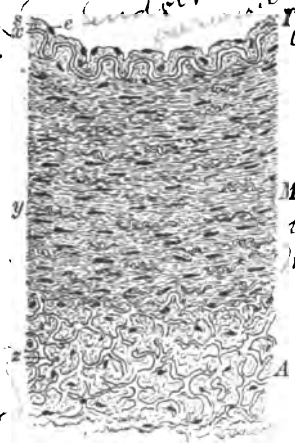

Section of human artery of medium size: *I*, the intima, consisting of the endothelium (*e*), the sub-endothelial tissue (*s*), and the internal elastic membrane (*x*); *M*, the media, composed of the involuntary muscle and the bundles of elastic tissue (*y*); *A*, the adventitia, containing irregular elastic trabeculæ (*z*).

FIG. 116.

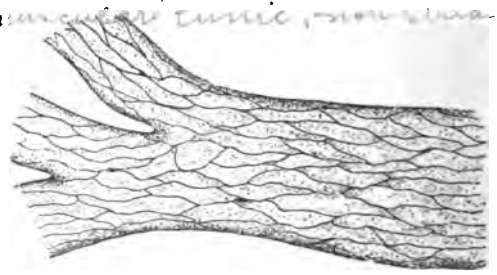

Endothelium of artery of frog: the vessel has been treated with silver, hence the boundaries of the endothelial plates are indicated by the dark lines of stained cement-substance. Several pseudo-stomata appear as minute dark areas between the cells.

arteries as small, medium, and large. The first group includes the terminal branches near transformation into capillaries, the second, all the named arteries of the body, except those which, as the aorta or the pulmonary artery, are recognized as belonging to the third group of large arterial vessels.

The **inner coat, or intima,** as seen in a typical artery of medium size, comprises three layers: (*a*) an **endothelial lining,** made up of long, lanceolate, nucleated plates, united by a sinuous line of cement-substance and placed parallel to the axis of the vessel; (*b*) a **sub-endothelial layer** of delicate fibrous connective tissue, with branched corpuscles; (*c*) a band of elastic tissue—the **internal elastic membrane**—which forms the most prominent part of the intima, appearing in sections of medium-sized arteries as a clear, glistening, and usually corrugated band separating the tissue of the inner coat from that of the media. The sub-endothelial tissue, which separates the endothelium from the internal elastic membrane, is wanting in the smaller arterioles, but appears in vessels of medium size as a longitudinally disposed layer, becoming more conspicuous with the increased calibre of the artery. In tubes of large diameter, as in the aorta, the sub-endothelial tissue appears as a stratum composed of layers made up of fibrous tissue, elastic networks, and flattened connective-tissue cells. Likewise, the elastic tissue of the intima increases in amount and in complexity, in the large arteries the broad elastic fibres becoming fused together to form an almost continuous sheet—the **fenestrated membrane of Henle.**

FIG. 117.

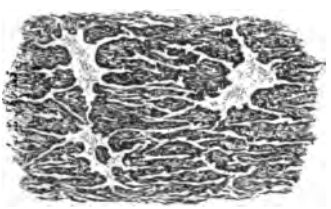

Portion of the intima of the human aorta, silver stained: the larger stellate figures are the cell-spaces in the ground-substance between the elastic bundles and contain the connective-tissue corpuscles.

FIG. 118.

Portion of the elastic tissue of the intima of the human aorta; the fibres are so broad and so closely grouped that they constitute an elastic sheet—the fenestrated membrane of Henle.

The **middle coat, or media,** is the muscular tunic, and consists principally of circularly disposed bundles of non-striated muscle-cells; these elements, when isolated, appear as broad, nucleated, irregular spindle-cells, presenting ragged outlines. In many arteries, conspicuously the subclavian, the inner portion of the media contains additional muscle-cells longitudinally disposed. In the smaller arteries the muscular tissue constitutes almost the entire media, but an insignificant amount of intermuscular fibrous connective tissue

being present; with the increase in the size of the vessel, h the quantity of such tissue becomes greater, in addition t bands of elastic tissue also make their appearance betw muscle-bundles.

In the large vessels the fibro-elastic tissue forms a cons portion of the media; in the aorta th tissue occurs as robust circularly arrange supplemented by oblique and longitudi beculæ of similar nature; these elastic together with the accompanying fibrou constitute the predominating structu muscle being less conspicuous in plac the intermuscular fibro-elastic strata.

FIG. 119.

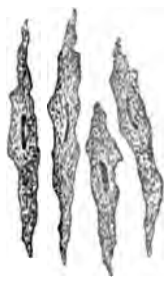

Muscle-cells isolated from the media of human artery.

Owing to this generous admixture of tissue, the large arteries, while possesse lutely of a greater amount of elastic tissu walls relatively less contractile than thos smaller arteries, whose media is comp almost pure muscular tissue.

The **external coat**, or **adventitia**, is the most resistant the vessel, its characteristic strength being due to the g amount of component fibro-elasti The fibrous tissue is arranged as felted bundles, irregularly plac intermingled with longitudinal b elastic tissue; numerous flatten nective-tissue cells lie between the applied to the fibrous trabecula mesh-work is closer and the of elastic tissue greater next th than towards the outer surroundi nective tissue into which the ac insensibly blends. In the **larger** the middle and outer coats are s by a band of condensed elastic the **external elastic membran** tain arteries present **peculiari** their coats; as examples of suc tions may be noted the slight ment of the sub-endothelial tissu intima of the external iliac, renal, teric, and cœliac arteries, the ance of longitudinal muscle-cell the intima of the aorta, and the presence of longitudina

FIG. 120.



Section of aorta of child: *I*, *M*, and *A*, respectively intima, media, and adventitia. The thick stratum of sub-endothelial tissue and the layer of longitudinally disposed bundles of muscle (*b*) are peculiarities of the inner coat.

posed muscular tissue within the adventitia of other vessels (superior mesenteric, splenic, renal, and iliac arteries).

In passing from medium-sized arteries towards smaller vessels, the coats become reduced in thickness, the media being earliest affected. The intima of the **smallest arterioles** consists of an endothelial layer alone, the middle coat includes but a single layer of muscle-cells, while the external tunic is reduced to a few longitudinal bundles. The vessels intermediate between small arteries and true capillaries no longer possess a complete layer of muscle-cells, the media being represented in such arterioles by scattered groups of circularly placed spindle-cells, forming an imperfect muscular sheet, which partially encircles the vessel. The nuclei of these circular muscle-cells are transversely placed, while those of the endothelial plates are usually longitudinal or parallel with the axis of the vessel.

FIG. 121.

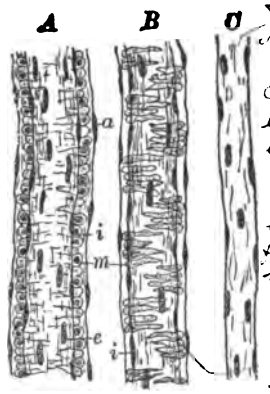

A, small human artery, in which the coats are reduced each to a single layer of cells; the media here consists of only one layer of muscle-cells (*m*), which are seen in optical section: *i*, intima; *a*, adventitia; *e*, nuclei of the endothelial plates. *B*, an arteriole just before becoming a capillary; the vessel still possesses muscle-cells (*m*), but these are now arranged as irregular groups. *C*, true capillary vessel, consisting of only an endothelial coat, the other tunics having disappeared; the nuclei are those of the endothelial plates.

THE VEINS.

The **veins** possess the same tunics as the arteries, but, in general, are characterized by thinner walls and a preponderance of connective over the muscular and elastic tissues. There is, further, less regularity and constancy in the structure of the coats.

The inner layer of the intima consists of a single layer of **endothelial cells**, rather broader and more polyhedral in form than those lining the arteries, the spindle shape being best marked in the smaller veins. The subendothelial tissue contains numerous connective-tissue corpuscles, and, in the larger veins, is arranged in distinct lamellæ. An inner elastic membrane is generally present, in some cases taking the form of a fenestrated layer.

The **media** consists of circular bundles of muscle-cells, associated with lamellæ of fibro-elastic tissue in the larger veins. This coat is best developed in the veins of the inferior extremities, less so in those of the upper limbs. The **muscle-tissue** of the veins is subject to many variations, both in amount and in arrangement, that

of the media is very scant or altogether wanting in a nun veins, including the thoracic part of the vena cava, the inter external jugular veins, the veins of the pia and dura, of the of bone, and of the corpora cavernosa. Certain veins posses **tudinal muscular bundles** in the inner part of the media ; the mesenteric, umbilical, iliac, and femoral.

The adventitia, often the thickest coat of the vein, con stout net-works composed of bands of fibro-elastic tissue ; veins additional **bundles of plain muscle** occur within th



Section of human vein of medium size: *I*, *M*, and *A*, respectively intima, media, and adventitia.

Among the venous trunks possessi marked, longitudinally arranged lar tissue in the external coat abdominal cava, azygos, hepatic, splenic, axillary, superior mes renal, spermatic, and external ilia The veins of the gravid uterus muscular tissue in all the coats, tl cipal bundles running longitudinal

The **valves** with which many v provided consist of crescentic fold inner tunic of the vessel, strengthe additional fibro-elastic tissue; i instances the muscular bundles ext a short distance into the valve. T or the attached margin of the valve its thinnest part, the free edge somewhat thickened. **The striat diac muscular** tissue is continu short distance in the walls of tho of the venæ cavæ and of the pulmonary veins immediately a the heart; the explanation of this fact is found in the deriv these portions of the vessels from the tissues of the primitiv tube.

THE CAPILLARIES.

The capillaries establish the only communication, with fev tions, between the arteries and the veins, and, further, pro intimate anatomical relation between the nutritive current tissues of the body necessary for the maintenance of the i and functional activity of the various organs. As exceptior usual intervention of the capillaries between the arterial and radicles, the direct communication between these vessels ex the erectile tissue of the genital organs, in the spleen, and parts of the peripheral circulation, as in the tips of the fing toes and of the nose, may be mentioned.

The capillaries form rich net-works in almost all tissues and organs, the principal localities where these vessels are wanting being epithelium, the hairs, the nails, teeth, cartilage, the cornea, the crystalline lens, and certain parts of the nervous system.

The capillary net-works vary in the size both of the meshes and of the constituent vessels. The average diameter of the capillaries is 7–10 μ; the smallest are found in the brain, retina, and muscle; the largest in bone-marrow, dentinal pulp, and the liver. The closest meshes are found in the air-vesicles of the lungs, the choroid, the liver, and other glands; the widest in the serous membranes, tendon, etc. Young tissues are more richly supplied than old ones.

FIG. 123.

Capillary blood-vessels from mesentery of young dog: *n*, the capillaries, with the nuclei of the endothelial plates, lying within the connective tissue (*g*).

The **capillaries** consist of a single layer of **endothelial cells,** united by intercellular cement-substance; they are, consequently, protoplasmic tubes of high vitality, admirably designed to facilitate the interchanges maintaining nutrition. After staining with silver the endothelial plates are seen as extended spindle-cells, united by irregular lines of darkened cement-substance; at the points where the vessels branch, irregular triangular cells are not infrequently seen. In such preparations, likewise, along the lines of union or at the juncture of several plates, irregular darkened areas—the **stigmata**—may be observed; these are probably minute spaces occupied by stained albuminous substances; these areas are supposed to aid the diapedesis or transmigration of the blood-cells.

Some capillaries are invested by an imperfect adventitious coat, formed by a net-work of surrounding branched connective-tissue cells, and resembling the reticulum present in lymphoid tissue. The intimate relation existing between the endothelium of the vessels and the surrounding connective-tissue corpuscles is well exhibited in young growing tissues, as the omentum.

The peculiarities distinguishing the capillaries from the small "capillary" arteries or veins consist not so much in the size of the vessels—for the capillaries may have absolutely the greater calibre—as in the character of their walls. The true capillary possesses *no muscle-cells*, these first appearing in irregular groups beyond the limits of the capillary vessel; in those cases where, as in certain veins, muscular tissue is wanting, the character of the adventitia of the vein will aid in determining the character of the vessel.

Small blood-vessels—the *vasa vasorum*—provide for the nutri-

tion of the walls of the medium- and large-sized arteries and veins. These vessels arise some distance from the area which they supply, frequently coming from a different branch or, as in the case of the veins, from a neighboring arterial stem.

The **nerves of blood-vessels** are mainly derived from the sympathetic system, and hence are principally of the non-medullated kind; a few medullated fibres, however, are usually present. The nerves accompanying the blood-vessel give off branches, which form surrounding plexuses; from these minute bundles pass, whose component fibrillæ are distributed to the media and the adventitia. The capillaries are accompanied by correspondingly delicate fibres.

Lymphatic clefts and **vessels** are found in the external coat of the larger vessels. In many places, as in the nerve-centres, including the organs of special sense, in the peritoneum, etc., the lymphatic clefts of the adventitia unite to form a large ensheathing circular sinus—the **perivascular lymph-space**—which separates a portion of the adventitia from the remainder of the vessel; as a result of this arrangement, the blood-vessel seemingly lies within the lymph-space. Perivascular lymphatics may be readily observed in the peritoneum of the frog.

THE HEART.

The heart-walls consist of three layers—the **endocardium**, the **muscular layer**, and the **pericardium**.

FIG. 124.

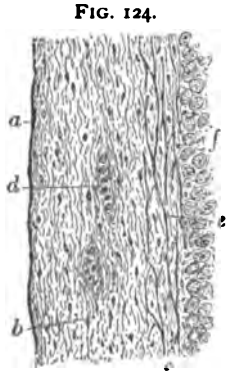

Section of human heart showing endocardium: *a*, endothelium; *b*, subendothelial connective-tissue stroma in outer layer (*c*), containing net-work of elastic fibres (*e*); *d*, transversely-cut bundles; *f*, muscular tissue.

The **endocardium** forms the serous lining of all parts of the organ, becoming continuous with the inner tunic of the blood-vessels at the several cardiac orifices. The inner free surface of the heart is covered with a single layer of polyhedral nucleated **endothelial cells.** These latter rest upon the **substance proper** of the endocardium, a stratum composed of fibrous connective tissue mingled with a felt-work of elastic fibres; the elastic net-works are especially well developed in the auricles, in certain parts of which the broad fibres join to form fenestrated membranes. The outer **connective-tissue layer** of the endocardium is continuous with the perimysium of the muscular tissue.

The **heart-valves** are formed by duplicatures of the endocardium strengthened by bands of fibrous tissue enclosing numerous elastic fibres. The endocardial layer of the auricular side of the

auriculo-ventricular valves is thicker than that of the ventricular surface. The roots or attached portions of these valves possess thickenings—the **annuli fibrosi**—composed of supplementary masses of fibro-elastic tissue. The auricular muscle is continued into the valves for about one-third of their width, following closely the general contours of the fold. Within the larger **chordæ tendineæ** the papillary muscles extend for some distance, in addition to which isolated muscle-bundles are also sometimes present. The semilunar valves possess a thin elastic layer on the arterial surface, augmented by a thick stratum of connective tissue, the bundles extending parallel with the margin of the valve; increased strength is secured by a fibro-elastic nodule, or **corpus Arantii**, which occupies the middle of each leaflet.

Beneath the ventricular endocardium, in many animals (deer, sheep, calf, pig, horse, goat, dog, certain birds, etc.), but not in man, peculiar bands—the **fibres of Purkinje**—occur; these are muscular fibres whose transverse striations are limited to the peripheral zone, while their centre is occupied by a large continuous mass of nucleated protoplasm. The fibres of Purkinje represent an embryonal condition of the muscular tissue, since the peripheral part of the fibre alone has undergone differentiation, while the central portion has remained indifferent protoplasm. Among some lower vertebrates, as fishes, a similar condition of the muscle-fibres is constant.

FIG. 125.

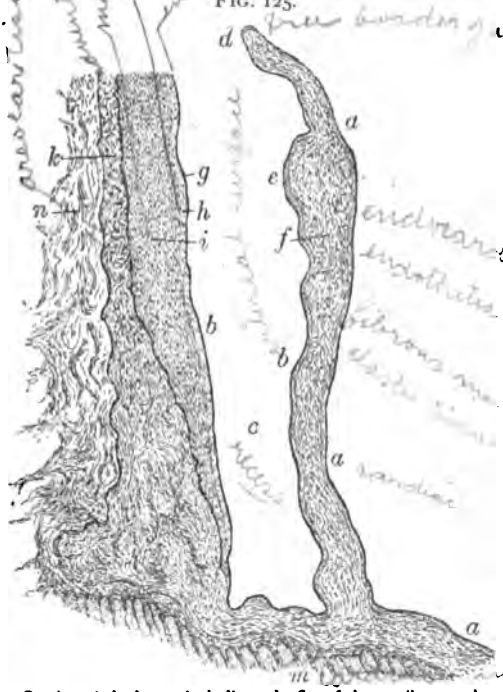

Section of the heart, including a leaflet of the semilunar valve of the pulmonary artery of child: *a*, *a*, cardiac, *b*, *b*, arterial, surface; *c*, recess behind the valve (*f*), constituting part of a sinus of Valsalva; *d*, free border of valve; *e*, thickening near edge of valve corresponding to a corpus Arantii; *g*, endothelium, *h*, intima, *i*, media, *k*, adventitia, of the pulmonary artery; the adventitia is continuous with the principal fibrous layer of the endocardium; *m*, cardiac muscle; *n*, areolar tissue.

The **muscular tissue of the heart** possesses the pec already described in Chapter IV.: it is composed of short, b nucleated fibre-cells, devoid of a sarcolemma, which unite an intricate net-work. The naked muscle-fibres are e within a perimysium and are grouped into primary and s bundles, which are associated to form lamellæ disposed i irregular and complex manner.

The muscular tissue of the auricles is arranged in gene outer transverse and an inner longitudinal layer, many s ditional bundles deviating from the principal disposition t independent courses in various d The muscle-bundles of the ventri a very intricate arrangement, the extending in an irregular oblique direction, some, in fact, describing of-eight in their course.

FIG. 126.

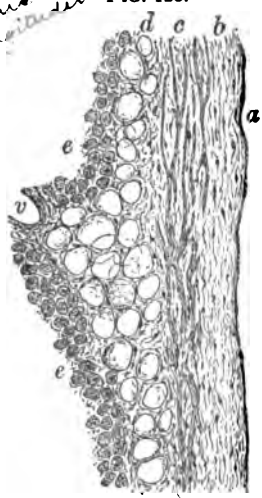

Section of human heart, including pericardium: *a*, endothelium of pericardial surface; *b*, subendothelial fibrous tissue; *c*, net-works of elastic fibres; *d*, subpericardial areolar tissue containing fat-cells embedded between pericardium and muscle (*e*); *v*, blood-vessel.

The **pericardium,** which in exterior of the heart, and by forms the pericardial sac, resen endocardium in possessing a sin of **endothelial plates** coverin surface, and a stratum of fibro-ela **nective tissue** beneath. The pericardium is distinctly thicker visceral, all the constituent laye better developed. The subp tissue covering the heart is cc with the intermuscular connecti of the outer muscular layer; in tion numerous fat-cells lie betv bundles of the fibrous and the tissue.

The **blood-vessels** supplying tl of the heart are derived as bra the coronary arteries. The principal trunks are situate larger interlamellar masses of connective tissue, within wh divide into numerous twigs giving origin to the capilla latter penetrate the primary muscle-bundles, among and p which they run. The relation between the individual mus and the capillaries is more intimate than usually supposed, shown by Meigs, the blood-vessels deeply impress the fil in some places are surrounded completely by the muscul The extraordinary demands made upon the nutrition of tl tissue as the result of its remarkable functional activity ex

necessity for such close arrangement. The deeper fibrous layers of the pericardium and of the endocardium receive numerous capillaries, a few being also found within the chordæ tendineæ and the valves.

The **lymphatics** of the heart are very numerous. They form a comprehensive system, embracing the lymph-spaces occupying the clefts between the muscle-fibres and the rich net-works of more definite channels extending within the pericardium and endocardium, including the valves. These two sets of lymph-radicles communicate but sparingly and pursue largely independent courses. Lymphatic vessels also accompany the branches of the coronary arteries.

The rich **nervous supply** of the heart is derived from the coronary plexuses, and includes numerous medullated fibres coming from the pneumogastric, as well as the non-medullated sympathetic fibres proceeding from the cervical ganglia. Numerous microscopic ganglia are found along the course of the larger nerve-trunks accompanying the branches of the coronary arteries, especially in the longitudinal interventricular and in the auriculo-ventricular furrows. Many additional small groups of ganglion-cells occur within the muscular tissue associated with the fibres supplying the intimate structure. The nerves and the blood-vessels are covered by the visceral pericardium.

The **development** of all parts **of the circulatory apparatus** takes place within the mesoderm; while possessing a common origin, the blood-vessels and the heart, however, develop independently, and, for a time, are distinct and disconnected. The earliest blood-vessels appear near the periphery of the **vascular area,** outside the limits of the proper body of the embryo; later and secondarily they extend centrally and unite with the primitive heart and those parts of the large trunks which have been formed coincidently within the embryo.

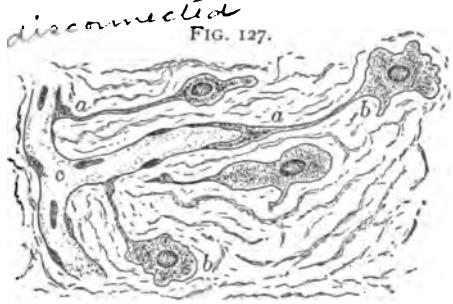

FIG. 127.

Developing capillary blood-vessels within the omentum of young rabbit: *a*, *a*, elongated protoplasmic processes connecting the walls of the newly-formed capillary (*c*) with the angioblastic connective-tissue corpuscles (*b*).

The mesodermic elements within certain tracts near the periphery of the vascular area undergo proliferation, which results in the production of deeply staining densely nucleated areas known as the **blood-islands of Pander;** these are the direct progenitors of the

earliest blood-vessels and the first blood-cells. The blood-channels appear within the nucleated "islands" as spaces which follow the partial breaking down of the inner portions of the areas. The peripheral zone of the nucleated cell-mass becomes the **endothelium** of the future blood-vessel, while, probably, certain of the enclosed mesodermic elements persist as the **primary blood-cells.** After a time the mesoderm surrounding the newly-formed endothelial tube differentiates into the muscular and other tissue of the **remaining coats.** The endothelium is, therefore, genetically the oldest part of the vessel, although its characteristic appearance, as seen in silvered adult tissue, is not visible until further differentiation has taken place.

The blood-channels are further extended by the fusion of elongated mesoblastic cells with those of the walls of the primary vessels, the lumina of the latter gradually entering the solid processes, which are thus converted into tubes. After the development of the earliest vessels in the manner indicated, the formation of all new vessels subsequently, in pathological processes as well as in normal ones, is **associated closely with the connective-tissue cells,** since solid protoplasmic processes of the united cells become later the walls of the young vessel.

The **development of the heart** resembles that of the extra-embryonic vessels in so far that the part first formed—the primary endothelial tube—originates by the differentiation of the mesodermic cells and the hollowing out of the tissue lying enclosed. In its very early stage the mammalian heart exists as **two** distinct and widely-separated tubes, which later unite to form a single sac. Outside the **primary endothelial heart** the mesoderm differentiates into the muscular tissue of the cardiac wall, but for some time the endothelial and muscular layers continue as independent tubes, the inner endothelial lining appearing as a shrunken cast reproducing the contours of the larger **muscular organ.** The two tunics are connected by numerous bridging bands, which increase in number and size with the progress of the development of the organ; these primary trabeculæ are represented in the adult organ by the columnæ carneæ and musculi pectinati. The **pericardium** originates as the specialized layer of mesoderm—the mesothelium—forming the immediate boundary of the general primary body-cavity, of which the pericardial sac is only a constricted portion.

FIG. 128.

Section of a part of the developing heart of a rabbit embryo of eleven days: *e*, the endothelial tube, within which lie several of the primary nucleated red blood-cells (*b*); *m*, the slightly differentiated mesoblastic cells, which later become the muscular tissue.

THE BLOOD.

While, when physiologically considered, the blood is regarded, with Bernard, best as an internal medium of exchange, histologically it may be classed as a mesodermic tissue possessing a fluid intercellular substance, the **liquor sanguinis**; in the latter float the cellular elements—the **blood-corpuscles.**

The **morphological constituents** of the blood are of two kinds, the **colorless** or **white corpuscles** and the **colored** or **red cells**; to these must be added a third variety, the **blood-platelets** or blood-plaques, which are probably constant and independent elements.

THE COLORLESS CELLS OF THE BLOOD.

The **colorless blood-cells** are not peculiar to the blood, since they originate in lymphoid tissues and bone-marrow and are carried into the blood-current, in which fluid they usually are observed. Critical examination of suitably stained preparations of human blood shows that the colorless cells include several varieties which are characterized by differences of size, nucleus, and granularity.

FIG 129.

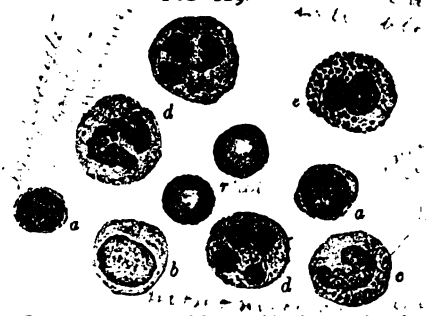

Leucocytes in normal human blood, stained and highly magnified: *a*, small lymphocytes; *b*, large leucocyte; *c*, transition form; *d*, polymorphonuclear cells; *e*, eosinophilic leucocyte; *r*, red corpuscles.

These varieties are:

1. **Small lymphocytes,** which are about the same size as the red blood-cells, or somewhat smaller, and contain a nucleus relatively so large that almost the entire cell is occupied by this body. The protoplasm is confined to a thin inconspicuous envelope and is usually devoid of granules. This variety may be regarded as the youngest form, and probably originates solely within lymphoid tissue.

2. **Large mononuclear leucocytes,** two or three times larger than the red cells, are frequently of an oval form and contain a nucleus which stains less intensely than in the younger cells, owing to its comparative poverty in chromatin. The protoplasm of these leucocytes contains but few, if any, pale granules.

3. **Transitional leucocytes,** which represent more advanced stages of development, are characterized by a nucleus exhibiting varying degrees of indentation, so that the nucleus often appears kidney-

shaped or of a horseshoe form. The protoplasm resembles that of the large mononuclear cells, presenting ordinarily no granularity, a few eosinophile granules, however, sometimes being distinguishable.

4. **Polymorphonuclear leucocytes** constitute the form most frequently encountered, and probably represent the fully developed condition of the leucocyte. These elements are distinguished by the variously distorted nucleus, which, being fairly rich in chromatin, presents a striking figure in stained preparations. The segments usually retain connection by delicate threads of chromatin; exceptionally the bridges become broken, in which case the term "polynuclear" is appropriate. Occasionally cells may be observed containing granules which stain deeply with eosin. Such "eosinophilic" leucocytes probably represent later phases of development. According to Ehrlich's teaching, the lymphocytes and the leucocytes are to be regarded as distinct varieties of cells, the former being derived from lymphoid tissues and the latter from bone-marrow.

Ehrlich has classified the granules occurring within the leucocytes into the following four groups, according to their affinity for "acid," "basic," or "neutral" stains:

1. *α-granules*, which are coarse and highly refracting, appearing in fresh blood as minute fat particles. These granules possess a strong affinity for eosin and acid stains; hence they are known as *eosinophile* and *oxyphile*.

2. *γ-granules*, which are coarse, intensely basophilic, and occur in the mononuclear "mast" cells.

3. *δ-granules*, which are fine, basophilic, and are seen in the polymorphonuclear leucocytes.

4. *ε-granules*, which exhibit an affinity for neutral staining mixtures and are neutrophilic. These constitute the most abundant and important variety of granules in the polymorphonuclear cells.

THE COLORED CELLS OF THE BLOOD.

The adult mammalian red blood-cell represents a condition of retrogression, since in its development it has suffered the loss of its nucleus and a profound metamorphosis of its protoplasm, changes of such importance that some authorities dispute the propriety of regarding the mammalian red blood-corpuscles as true cells. The presence or absence of the **nucleus** within the colored corpuscle, together with its general form, furnishes a basis for a division of all vertebrate bloods into—

A. **Those having nucleated, oval red corpuscles:** including fishes (except *cyclostomata*, which have *round*, *discoidal* cells, as the lamprey), amphibians, reptiles, and birds.

B. **Those having non-nucleated, round, discoidal red cor-**

puscles: including man and other mammals, except the camel family, which have *oval, non-nucleated* red blood-cells.

Since an oval corpuscle on being subjected to certain reagents may present a circular outline, the presence or absence of a nucleus offers the most reliable means of differential diagnosis between mammalian and other bloods.

The human **colored blood-cell, or erythrocyte,** is a small disk, about 8 μ in diameter, and exhibiting individually a faint greenish-yellow tinge. The well-known color of the blood appears only when great numbers of these corpuscles are massed; the term "red" conventionally applied to these elements is, strictly regarded, incorrect and less appropriate than "colored." The two surfaces of the blood-disk are not perfectly flat, the centre of the corpuscle being slightly biconcave, while its edges are rounded, biconvex, and somewhat thickened: in consequence of this peculiar "biscuit" form, all planes of the corpuscle are not seen accurately focused at one time, the centre usually appearing either darker or lighter than the marginal parts of the cell, depending upon the focal adjustment.

FIG. 130.

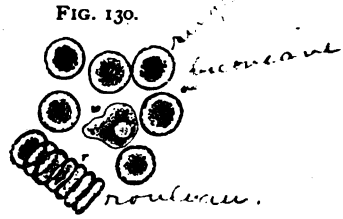

Human blood-cells: *w*, colorless corpuscle, surrounded by red cells; those at *r* exhibit a partially-formed rouleau.

The structure of the colored blood-corpuscles is still a subject of discussion. According to the generally accepted view, the corpuscles consist of two parts: (*a*) the transparent, colorless, apparently homogeneous, and plastic **stroma,** extensible and pliable to a high degree, and (*b*) the coloring matter, or **hæmoglobin,** which is held within, and uniformly distributed throughout, the former. This conception of the corpuscle assumes the presence of a uniform though highly flexible stroma-mass of definite form, colored by the imbibition of the soluble hæmoglobin. On the other hand, the behavior of these elements when treated with water, upon the addition of which the corpuscles swell, lose the discoidal form, and become globular, as well as the suggestive appearances following the staining with aniline of such bleached corpuscles, the outlines of the cells then showing as distinct rosy rings, offers strong arguments, in the opinion of not a few, for the belief that the red corpuscles are minute sacs, consisting of a limiting membrane and the colored fluid contents.

The nuclei of the red cells, when present, lie embedded within the colored stroma; in perfectly fresh or circulating corpuscles they are made out with great difficulty, since they possess a refractive index almost identical with that of the other parts of the cell. After reagents, or after the expiration of some minutes, the nuclei become

very evident, and correspond in appearance and structure with those of other cells, a nucleus often being visible.

In fresh blood the red corpuscles within a few minutes arrange themselves in rows or piles by the apposition of their broader surfaces, thus forming figures which, from their resemblance to rolls of coin, are termed **rouleaux.** The cause of this phenomenon is still uncertain, although it is not improbable that it is to be attributed to the presence, in the fresh corpuscles, of a film of a nature repelling the liquor sanguinis and favoring the adhesion of the disks; the rouleaux are only temporary, the corpuscles later spontaneously separating and remaining apart. It is of interest to note that only discoidal corpuscles of mammalian bloods (including, however, the discoidal cells of the lamprey) run together to form these figures, the projecting nuclei and the slight biconvexity of the oval nucleated cells affording surfaces evidently unfavorable for adhesion.

The **average diameter** of the red corpuscles in the various races of mankind is identical, being between 7 and 8 μ, or about 1-3200th of an inch.

The size of the animal bears no relation to that of its red blood-cells, as shown by the following measurements of some mammalian bloods, based on the observations of Gulliver:

	Millimetre.		Millimetre.		Millimetre.
Elephant	.0092	Guinea-pig	.0071	Pig	.0060
Sloth	.0086	Dog	.0071	Horse	.0059
Whale	.0080	Rabbit	.0070	Cat	.0058
Man	.0079	Bear	.0070	Sheep	.0048
Beaver	.0076	Mouse	.0067	Goat	.0040
Monkey	.0074	Ox	.0048	Muskdeer	.0024

The largest corpuscles are those of the amphibians, the red cells of the frog measuring .0016 mm. in breadth by .022 mm. in length, those of the triton, .019 by .029, and those of the proteus, .035 by .058. The maximum size is reached in the huge red cells of the amphiuma, which are no less than .046 mm. wide by .075 mm. long, and are readily distinguishable by the unaided eye.

The **number of colored cells** normally present in one cubic millimetre of human blood, as determined by the hæmacytometer, is about five millions; these figures are modified by sex, the male subject usually having more corpuscles than the female.

The number of red corpuscles varies in different animals: the carnivora possess a greater number of cells in a given quantity of blood than do the herbivora; in birds the proportion is still larger; while in the sluggish amphibians the number of the huge red cells is reduced to thousands.

Effect of Reagents applied to Human Blood. No elements

are more sensitive to changes in environment or to the effects of reagents than are the cells of the blood. An appreciation of the alterations referable to external causes is important as guarding against unwarranted conclusions as to the existence of pathological conditions, since not infrequently appearances which lead the tyro to infer disease may be ascribed to influences acting on the corpuscles outside the body.

FIG. 131.

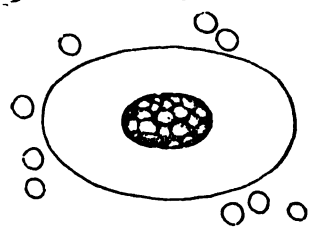

Red blood-cells of man and of amphiuma, magnified to the same extent to show the size of the human corpuscles in comparison with that of the largest known blood-cell.

If fresh blood be exposed to a current of air, subjected to undue pressure or to other disturbing influences, alterations of the corpuscles at once take place. One of the most common distortions affects the exterior of the **red corpuscles,** and results in the formation of a number of minute projections, or spines, producing a condition known as **crenation.**

Saline Solutions. The application of a weak saline solution or of urine is attended with similar effect; if the strength of the reagent be gradually increased, a corresponding progressive degree in the distortion is observed, until, finally, upon the addition of a concentrated brine, a shrivelled, shapeless mass replaces the former discoidal red corpuscle. The reaction is less marked upon the **colorless cells,** weak salines producing no perceptible change, while a slight shrinkage is noticeable after the stronger solutions.

FIG. 132.



Reactions of human blood-cells with various reagents: *A*, effect of treatment with water upon the white (*w*) and the colored cell (*r*); *B*, red cells after the addition of saline solutions, crenation following the application of weak solutions, great shrinking and distortion (*s*) succeeding the action of the concentrated reagent; *C*, action of dilute acetic acid on the colorless cell (*w*) and on the red corpuscle (*r*); *D*, red blood-cell after the addition of one-per-cent. solution of tannic acid.

Water. Upon the application of water the **colored cells** swell up, lose the discoidal form, and become spherical, and at the same time part with their coloring matter, the hæmoglobin; the latter, being dissolved, leaves the bleached and colorless stroma to form the "ghost." That the red corpuscles are not destroyed by the water, as sometimes stated, may be demonstrated by the addition of a suitable aniline dye, when the presence of the bleached corpuscles is made evident by the colored rings which mark their outlines.

The action of water upon the living **colorless blood-cells** is somewhat different. These corpuscles cease their amœboid movements, retract their

processes, become round, and swell up into larger spheres; meanwhile, the protoplasm resolves itself into a number of sharply-cut granules, which, owing to their suspension within a fluid of less density than the blood-plasma, exhibit the active dancing or oscillatory movements which constitute the **"Brownian motion,"** a phenomenon entirely physical in nature. The nuclei of the colorless cells after treatment with water appear as clear or slightly granular areas among the vibrating particles. After a time the distention of the corpuscle becomes too great, and rupture takes place, followed by the escape of the particles of disintegrated protoplasm.

Acids. Upon the addition of weak **acetic acid** the **red cells** become rapidly decolorized, at the same time losing the discoidal form and approaching the spherical. The protoplasm of the **colorless corpuscles** clears up entirely, the nuclei coming very conspicuously into view. Upon subsequent treatment of acid preparations with aniline, the nuclei of the white cells appear deeply stained, while the red cells are outlined by faintly-colored rings.

Tannic acid, when applied to the red corpuscles in weak (one-half to one per cent.) solutions, produces a peculiar effect: the coloring matter of the corpuscle is coagulated as it escapes from the cell and becomes conspicuous as a minute accumulation adhering to one edge of the corpuscle. Where strong solutions of tannic acid are employed, the hæmoglobin is coagulated within the corpuscle before it has had an opportunity to escape, producing appearances which have been mistaken for nuclei and other details of cell-structure.

The Blood-Platelets. If human blood be drawn *directly* into a drop of osmic acid solution (one per cent.) or of a three-fourths per cent. solution of sodium chloride, covered at once, and examined with a high power, numbers of small, colorless, circular disks will be seen on careful observation; these are the **blood-platelets** of Bizzozero, sometimes called the third corpuscular elements of the blood. They are very unstable, prone to disintegration, and are variable in size, possessing an average diameter of about one-third of that of the red cells; they occur singly, but show a marked disposition to run together in groups preparatory to breaking up into the minute particles long known as the **granules of Max Schultze.** Unless great precaution is taken to insure the immediate action of the preserving fluids, the blood-platelets will not be seen in their normal form.

FIG. 133.



A, human red blood-cells and blood-platelets (*p*); *g*, minute fatty (?) particles, which occur isolated or in masses; *B*, fibrin filaments, among which lie partially disintegrated blood-platelets.

These bodies may be recognized in the circulating blood, as observed by Osler and others, and are constant, although numerically variable, elements of mammalian bloods. The peculiar elongated elliptical "blood-spindles" found in the blood of other vertebrates are probably to be regarded as the homologues of the blood-plaques of mammals. While the presence of the blood-platelets as distinct, constant, and normal constituents of the human blood is now generally recognized, authorities are far from accord as to their significance. The evidence at present seems to point to a close relation between these bodies and the red cells, the blood-platelets being regarded by many as only fragments of the former.

Fibrin filaments are to be observed in a drop of blood mounted in the usual manner for microscopical examination and allowed to stand for some time in a moist chamber; they appear as very delicate straight interlacing threads which occupy the interspaces between the corpuscles and frequently radiate from a common centre, containing a group of partially broken-down blood-platelets.

Additional minute particles are to be seen in human blood, regarding the nature, source, and significance of which much has been surmised and but little definitely established. These include the small colored disks, the **microcytes** or the **hæmatoblasts** of Hayem, according to whose authority they constitute an important source of the red corpuscles; by others they are regarded as separated portions of the ordinary red cells. Other minute, colorless, often highly refracting, granules are encountered floating in the liquor sanguinis; such are the **elementary particles** of Zimmermann and the **granules of Max Schultze.** These particles differ in nature as well as in source; some probably are derived from the disintegration of the white corpuscles and of the blood-platelets, others from that of the endothelial plates of the vascular channels, while many represent fatty granules absorbed during digestion or taken up, possibly, in the course of pathological processes.

FIG. 134.

Hæmin crystals from dried human blood.

Blood-Crystals. The coloring matter of the blood—the **hæmoglobin**—readily crystallizes in man and most mammals as elongated, rhombic prisms; the hæmoglobin crystals of the squirrel and of the guinea-pig, however, are respectively hexagonal plates and rhombic tetrahedra. These blood-crystals, of a deeper or lighter red color according to their size, often form in preparations of blood which have been sealed and allowed to stand after the addition of a few drops of water; the blood of the rat is especially favorable for their production. If dried blood be treated and thoroughly mixed with glacial acetic acid (the addition

of a few granules of common salt being advantageous in the case of old clots), on slightly heating until bubbles appear, numbers of dark-brown irregular rhombic prisms form. These are the **hæmin crystals** of Teichmann, which are positive indications of the **presence of blood,** but have no value in the determination of its source. They vary greatly in size and considerably in form, the peculiar unequally-notched ends presented by the larger crystals being quite characteristic.

DEVELOPMENT OF THE BLOOD-CORPUSCLES.

The origin of the colorless blood-cells must be referred to the lymphoid tissues, since these elements are identical with those occurring within the lymph with which they are poured into the blood-current. The colorless corpuscles appear later than the red cells, the first ones probably entering the circulation as migratory mesodermic elements. The lymphatic tissue and the bone-marrow constitute the principal sources of the colorless blood-corpuscles, which are produced by the division of the numberless masses of active protoplasm contained within the various aggregations of lymphoid and marrow tissue throughout the body.

The multiplication of existing colorless cells which takes place normally, but which is especially active under the stimulus of pathological conditions, accounts for the origin of a certain number of white corpuscles; the division of the cellular elements of connective tissue is regarded by some as an additional source of these blood-cells. The efferent lymph-streams passing from the lymphatic tissue, as well as the blood contained in the splenic vein, are richer in colorless cells than are the corresponding afferent currents, showing that the augmentation is due to the new elements contributed by the lymphoid tissues through which the currents pass.

The origin of the colored blood-cells is usually considered as taking place during two epochs—before and after birth. It must be remembered, however, that such division is conventional and largely arbitrary, since the period at which the primary embryonic processes of such formation cease and are replaced by those maintained throughout life is uncertain and variable; in man and mammals born in a condition of advanced development the production of blood-corpuscles within the marrow is instituted before the termination of intra-uterine life.

Before Birth. The first blood-cells originate outside the body of the embryo, within the angioblastic cells of the mesodermic tract of the vascular area. Certain cells of this layer increase in size and undergo proliferation of their nuclei, forming multinucleated areas known as the **blood-islands of Pander.** These subsequently

unite into an irregular net-work, the nodal points of which are distinguished by an active production of new nuclei. Some of these acquire protoplasm and later become the endothelium of the blood-vessel, while others, more centrally situated, are converted into the **primary blood-corpuscles**, the intervening tissue undergoing liquefaction to constitute the blood-plasma. These earliest blood-cells, although destined to become the red corpuscles, are at first colorless masses of active protoplasm, provided with nuclei and exhibiting amœboid movements. After a time the protoplasm gradually acquires the characteristic tinge and assumes a discoidal form, the elements then constituting the nucleated red blood-disks of the embryo. The earliest red cells unquestionably increase by the division of the primary corpuscles, the reproduction being attended by the changes of karyokinesis. This multiplication of the early red corpuscles probably ceases in man long before the end of gestation, the primary colored corpuscles meanwhile becoming smaller and losing their nuclei, so that at birth all the nucleated red cells have disappeared. The exact details of the metamorphosis from the embryonal to the adult form are still uncertain. There is no trustworthy evidence to establish the descent of the red corpuscles from the colorless cells, the two being distinct elements having independent origins. Multiplication of the embryonal blood-cells occurs within the recesses occupied by the sluggish blood-streams of the liver. The spleen must probably be reckoned among the situations in which the red blood-cells are formed.

After Birth. Of the many suggested sources for the post-natal production of the red blood-cells, of which great numbers must be formed constantly to replace those continually undergoing destruction, the **red marrow of bones** is undoubtedly the most important.

Among the more common elements of the red marrow, cells usually are to be observed which strongly resemble the embryonal red blood-corpuscles, being distinguished from the ordinary marrow-cells by their hæmoglobin-colored protoplasm, smaller size, and unstable nuclei. These cells, often called the **erythroblasts**, are undoubtedly transitional forms of red blood-corpuscles, the nuclei disappearing and the protoplasm assuming the usual appearance of such elements.

As to the **source** of the erythroblasts, however, whether they are transformed colorless marrow-cells or distinct elements, the descendants of the red corpuscles of the embryo, much uncertainty still exists. There are strong reasons for regarding the latter supposition the true indication of their nature and origin, the production of the red corpuscles both before and after birth being thus closely related.

Direct transformation of the colorless cells, production within the

spleen, and growth from the blood-platelets, or hæmatoblasts of Hayem, have been advanced from time to time as additional sources of origin of the red blood-corpuscles. Without entering upon a detailed critical consideration of the evidence supporting these views, it may be stated that, excepting the spleen, they lack the conclusive proof of unimpeachable direct observation. Concerning the relations of the "hæmatoblasts" much confusion exists in consequence of the application of the term to different objects by various writers. The formative processes within the red bone-marrow may be regarded, in the light of our present knowledge, as the most important source of the new red blood-corpuscles produced throughout life. After severe hemorrhage, it is probable that the spleen may assume the *rôle* of a blood-forming organ.

Mention may be made in this place of the problematic organs the so-called **arterial glands,** which include the **coccygeal** and **carotid glands.**

The first of these, the **glandula coccygea,** or **Luschka's gland,** occurs near the tip, in front of the apex, of the coccyx, associated with the middle sacral artery, which contributes the blood-vessels largely forming its pea-sized mass. The **carotid gland** lies at the bifurcation of the common carotid artery, frequently between the resulting branches, and appears as a somewhat flattened ovoid nodule.

These peculiar bodies are **similar in structure,** both consisting of **dense capillary net-works** enclosing irregular groups of **granular polyhedral cells,** whose presence suggested the once supposed glandular nature of the organs. The entire plexiform mass is invested by **connective tissue,** fibrous **septa** penetrating between the vascular territories, at the periphery of which course the veins. Numerous non-medullated **nerve-fibres** are also present.

The true nature and function of these rudimentary organs are entirely unknown, and probably will remain so until the embryology of these bodies is better understood. Their apparent close relation to the sympathetic has led many to regard these organs as affiliated with this nervous system ; hence they are sometimes designated as "sympathetic ganglia."

CHAPTER VIII.

THE LYMPHATIC SYSTEM.

THE lymphatic system consists of two parts—the **lymph-channels** and their contents the **lymph**, and the **lymphatic tissue.** The former may be represented by irregular interfascicular clefts between the bundles of fibrous tissue or by vessels with well-defined walls, while the latter may exist as diffuse adenoid tissue, the simple lymphatic nodule, or the complicated compound lymph-gland.

THE LYMPH-CHANNELS.

The **lymphatic spaces,** the radicles of the more distinct vessels, are almost universally present, since they exist in almost every locality where connective tissue abounds, forming intercommunicating systems of greater or less perfection throughout the various organs. The relation between the connective tissue and the lymph-radicles is very intimate, and it may be assumed that *all interfascicular clefts are directly or indirectly connected with the lymphatics.* In loose areolar tissues, as the subcutaneous, the lymph-spaces are ill-defined clefts, irregular in form and size, which are bounded by the neighboring bundles of fibrous tissue and lined by an imperfect layer of endothelioid connective-tissue cells. In the denser forms of fibrous tissue, as the central tendon of the diaphragm, cornea, etc., the lymph-spaces are more limited and form well-defined intercommunicating systems of canals, or "juice-channels;" of such the corneal spaces and the bone-lacunæ are familiar examples.

FIG. 135.



Lymph-spaces between bundles of fibrous tissue seen in profile, from the human cornea: *b, b,* bundles of fibrous tissue; *s,* lymph-spaces containing flattened connective-tissue cells.

These spaces are filled incompletely by the connective-tissue corpuscles, which usually are applied to one wall of the cavity to form a partial lining. The **number of cells** occupying a single space varies: sometimes several lie side by side (kitten's cornea) united by lines of cement-substance; in such cases, after silvering, the cells present the appearance of endothelial plates. The **large serous**

cavities, as the peritoneal or pleural sacs, are, in pr greatly-dilated lymph-spaces, lined by modified connective-tissue cells, the endothelial plates, which by mutual pressure become polygonal in outline; in-

FIG. 136.

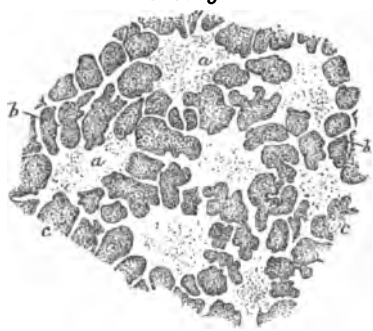

Lymph-spaces of cornea, surface view: *a*, the spaces within the ground-substance (*c*) connected by the minute canals (*b*), or canaliculi.

FIG. 13

Lymph-capill silver-stained me frog: a number corpuscles occup cate endothelial constitutes the ve

stead of a few cells sufficing for the formation of a lining as in the case of lymph-space, innu ments are require the large serous ca

FIG. 138.

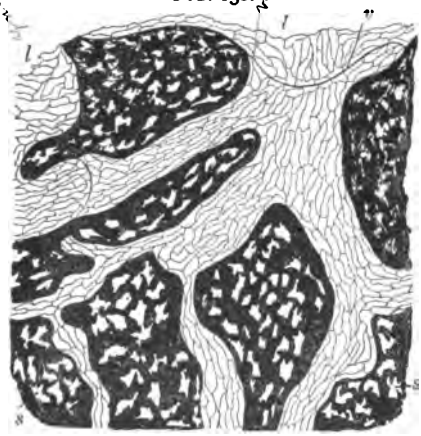

Lymphatics of silvered diaphragm of rabbit: *s*, *s*, lymph-spaces lying within the deeply-stained ground-substance; *l*, *l*, lymphatic vessels lined with endothelium and possessing valves (*v*) and corresponding dilatations.

The lymphatic s the connective tis form definite char margins of the fib the lymph being ca **lymphatic vesse** organs to the adja of adenoid tissue phatic glands. T vessels immediate ing the spaces may as the **lympha laries,** being p tubes of great del posed of a single dothelial plates.

The contours c phatic vessels are not uniform, but present numerous dil constrictions, which indicate the positions of the imperf

these latter consist of a fold of endothelium, strengthened often by a minute quantity of elastic tissue.

The relation of the lymph-spaces to the capillary blood-vessels on the one hand and to the lymphatic vessels on the other is very intimate; in certain localities, as in the omentum, indirect communication between the blood-vessels and lymphatics is established by means of the spaces of the groundwork of the dense connective tissue (Klein). Many nerve-trunks are enclosed by **perineurial lymphatic channels,** into which the lymph-spaces of the surrounding tissue open. The blood-vessels of the central nervous system, especially of the retina, likewise are surrounded by distinct **perivascular lymph-sheaths,** formed by the enlargement and confluence of the clefts within the adventitia of the vessels. In some membranous structures, notably the amphibian mesentery, the vessels lie encased within distinct endothelial tubes.

FIG. 139.

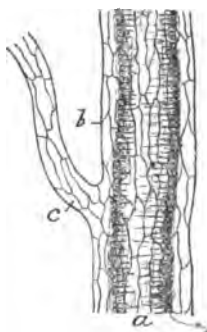

Perivascular lymphatic (*b*) enclosing a small artery (*a*), from the silvered mesentery of frog: *c*, branching lymphatic capillary.

Lymphatic vessels of large size have walls of considerable thickness, resembling those of the veins. In such vessels three coats are recognizable—the inner, or **endothelial,** the middle, or **muscular,** and the outer, or **connective tissue.** The **thoracic duct** possesses a well-developed intima, composed of a considerable layer of subendothelial connective tissue containing a net-work of longitudinally disposed elastic fibres. The muscular tissue of the media is supplemented by bundles of involuntary muscle extending lengthwise within the outer coat, which in the vessel under consideration is particularly robust.

FIG. 140.



Transverse section of human thoracic duct: *i*, *m*, and *o*, respectively the inner, middle, and outer tunics; *x*, endothelial lining, beneath which lies the fibrous stratum containing net-work of longitudinal elastic fibres (*y*); *z*, longitudinally disposed bundles of muscular tissue within adventitia; *v*, capillary blood-vessels.

The **lymph** contained within the lymphatic vessels, like the blood, consists of two parts—the clear, straw-colored **plasma,** or **liquor lymphæ,** and the **cellular elements,** the **lymph-corpuscles.** The cells of the lymph are small nucleated masses of active protoplasm, when at rest presenting a spherical form and measuring about .01 mm. in diameter; in their usual condition of activity, however, their outlines

are continually undergoing the changes effected by amœbo
ment. These elements, in short, possess all the peculiariti
colorless blood-corpuscles with which, in fact, they are iden

In addition to the lymph-corpuscles, numerous **fatty g**
are usually present within the plasma; in the lymphatic v
the intestinal tract the absorption of fatty matters is made cor
by the presence of the **chyle,** an emulsion occupying the
lacteals, or chyle-vessels; these latter are not distinct tu
only those portions of the lymphatic net-work which co
milky-looking chyle during certain stages of digestion.

The **sources of the lymph-corpuscles** are those alre
sidered in connection with the colorless cells of the blood,
phoid or adenoid tissues of the body being unquestionably
important and prolific seats for the production of these e
The presence of a few cells within the lymph-radicles, betw
commencement and the first masses of adenoid tissue occu
their course, is due to the entrance within the vessels of n
cells from the surrounding connective tissue; only after th
stream has passed through considerable masses of lymphc
do the corpuscles appear with profusion.

THE LYMPHATIC TISSUES.

Lymphatic, lymphoid, or **adenoid tissue** usually c
circumscribed masses known as **lymphatic nodules** or "
in certain localities, however, as in pa
mucous membranes of the larynx, the
the stomach, the intestines, etc., i
masses of **diffuse lymphatic tissu**
The term "gland," as applied to c
lymph-nodules, is an inaccuracy sanc
long usage.

FIG. 141.

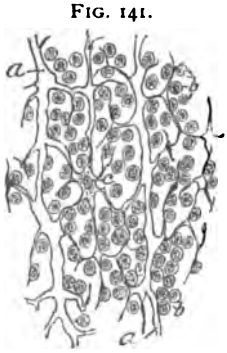

Elements of adenoid tissue from partially brushed section of lymphatic gland of child: *a*, fibres of reticulum; *b*, lymphoid cells; *c*, expanded connective-tissue plate.

Lymphatic tissue, wherever foun
posed structurally of **two** elements—
cate **connective-tissue reticulum**
surface of the fibres of which plate-l
stellate, connective-tissue corpuscles ar
and the **small round cells** contain
the reticulum. These elements—the **ly**
or **adenoid cells**—become the ly
puscles and the colorless blood-cells
escape from the denser reticulum
lymph-current and their subsequent
into the blood.

The variations in the compactness with which the cells a

within the net-work constitute the **denser** or **looser forms** of adenoid tissue found in the lymphatic nodules; ordinarily the cells are so closely placed that the reticulum is greatly masked, satisfactory views of the latter being obtained only in sections of great thinness or after the cells have been removed by brushing or by violent agitation.

The **reticulum of lymphoid tissue** consists of intertwining and anastomosing bundles of connective tissue; along the fibrous trabeculæ, especially at the nodal points, flattened plate-like or stellate connective-tissue cells are applied after the manner of an imperfect endothelial investment. In parts of many adenoid structures the delicate reticulum seems to be formed by the union of the protoplasmic processes of the branching connective-tissue cells themselves; this arrangement, however, is usually only seeming, the cells really being applied to the surface of the fibres and not constituting an integral part of the reticulum. It is probable that in the splenic pulp and in a few other localities the processes of the stellate cells do unite to form protoplasmic net-works.

FIG. 142.

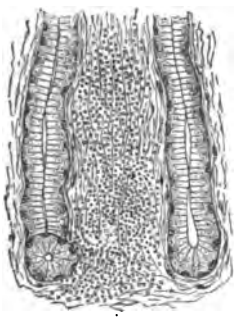

Diffuse lymphoid tissue occupying deeper layers of mucosa of human stomach: the lymphoid cells infiltrate the fibrous tissue between the glands without being definitely limited.

FIG. 143.

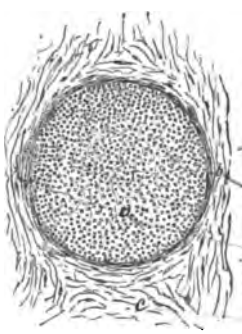

Simple lymph-follicle from conjunctiva of dog: *a*, lymphoid tissue, limited by the fibrous capsule (*b*); *c*, surrounding connective tissue.

Diffuse adenoid tissue represents the least specialized form of the lymphoid structures; the mucosæ of the digestive and of the respiratory tracts afford good illustrations of the presence of such tissue.

Simple lymphatic nodules, or solitary follicles, stand next in differentiation; these are found in almost all mucous membranes (those of the bladder and of the sexual organs excepted), while they occur in great numbers in the respiratory and digestive tracts, the solitary glands of the latter being important examples of these structures. The simple nodules consist of oval masses of adenoid tissue, limited by a delicate connective-tissue wall or capsule, composed of fibrous lamellæ. The central parts of such nodules, as well as of the cortical follicles of the larger glands, are usually occupied by **germ-centres,** areas composed of lymphoid tissue of looser

texture containing large cells exhibiting mitotic figures. The **afferent lymph-vessels** conveying the lymph to the simple follicles break up at the periphery of the nodule into branches, which distribute the lymph to the adenoid tissue; corresponding **efferent vessels** carry off the fluid returned from the lymphoid tissue and unite to form larger lymphatic trunks.

Compound lymphatic follicles, the lymphatic glands of gross anatomy, are formed by the aggregation and partial fusion of a

FIG. 144.

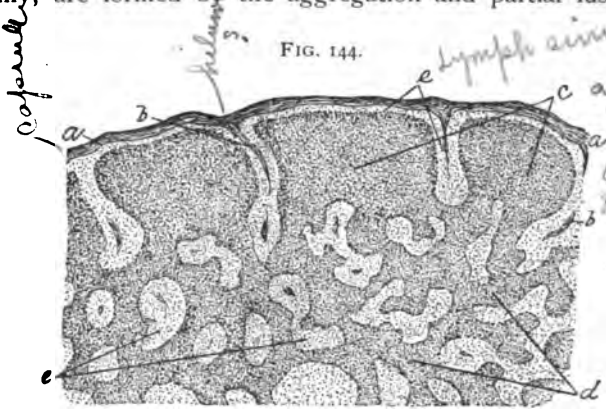

Section of lymph-gland from child, showing general arrangement of lymphoid tissue and lymph-sinuses: *a*, capsule from which trabeculæ (*b*, *b*) extend; *c*, masses of dense adenoid tissue composing the cortical follicles; *d*, the same, of the medullary cords; *e*, lymph-sinuses.

number of simple nodules. These structures enjoy a wide distribution, and are represented by the numerous chains of deep and superficial lymph-glands, of which the axillary and inguinal glands are familiar instances.

FIG. 145.

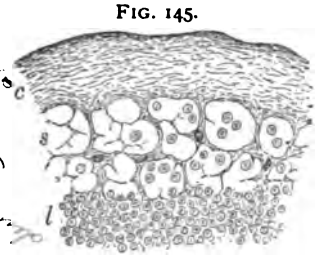

Section of lymphatic gland of child, including portion of cortex at periphery: *c*, capsule; *s*, loose tissue of the lymph-sinus; *l*, denser lymph-tissue of the cortical follicle.

The periphery of these lymph-glands is occupied by a firm **capsule** composed of fibrous connective tissue, intermingled with which, in the largest glands, bundles of **involuntary muscle** are sometimes present. At the position of entrance and exit of the larger blood-vessels and the efferent lymphatic trunks, usually opposite the most convex surface of the organ, the capsule dips deeply into the interior of the gland and forms the **hilum.** The space included within the capsule is subdivided into a peripheral zone, the **cortex,** and a centrally situated part, the **medulla,** which at the hilum reaches

the exterior. The details of arrangement distinguishing these portions of the gland depend primarily upon the distribution of the trabeculæ which continue the tissue of the capsule into all parts of the organ.

The **trabeculæ,** composed of stout bundles of fibrous tissue, extend from the inner surface of the capsule towards the hilum and divide the cortex into a number of imperfect spherical compartments which enclose masses of adenoid tissue, the **cortical follicles,** which correspond to simple lymph-follicles. The continuations of the trabeculæ towards the centre of the gland unite at much more frequent intervals and form throughout the medulla a series of incomplete partitions which separate imperfect compartments occupied by elongated masses of adenoid tissue, the **medullary cords.** These latter and the cortical follicles constitute one continuous mass of dense lymphoid

FIG. 146.

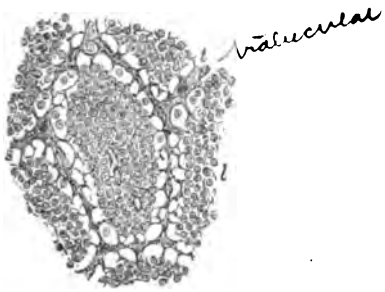

Section of lymphatic gland of child, including portion of medulla: *t*, part of trabecula, on either side of which narrow lymph-sinuses are seen, bounded by denser structure of medullary cords (*l*).

FIG. 147.

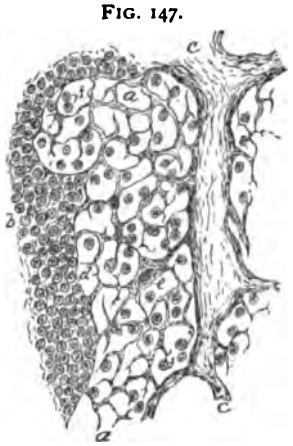

Portion of human lymph-gland, showing details of structure: *a*, lymph-sinus; *b*, adenoid tissue; *c*, trabeculæ; *d*, coarser reticulum of lymph-sinus; *e*, expanded connective-tissue plate applied to fibres; *f*, lymphoid cells.

tissue, which follows the contours of the spaces occupied, but does not completely fill the compartments formed by the fibrous trabeculæ.

The spaces included between the fibrous trabeculæ and the masses of dense adenoid tissue are occupied by a very loose reticulum and sparingly distributed lymphoid cells; these channels are the **lymph-sinuses,** into which the lymph brought by the peripherally-situated afferent vessels is poured and through which it finds its sluggish course, thus securing the opportunity of taking up numerous new cells in its journey through the organ. The lymph-sinuses form a freely intercommunicating system of canals throughout the gland, beginning at the periphery, where they receive the afferent lymph-vessels, and ending in the hilum, where the lymph is collected and carried off by the **efferent trunks.**

The **trabeculæ** all along their course give off numerous ramifications which break up into the delicate reticulum constituting the **supporting framework** in whose meshes the lymphoid cells are held.

The **blood-vessels** supplying the lymphatic glands are arranged as two groups: the one set gains entrance at the periphery and is distributed principally to the capsule and larger trabeculæ; the other group enters at the hilum, the majority of the arterial branches passing directly into the lymphoid tissue. The **nerves** include both the medullated and the pale fibres.

In certain localities, especially in the prevertebral retroperitoneal and cervical regions, in the vicinity of the abdominal aorta, vena cava, adrenal and renal vessels, along the brim of the pelvis and in the root of the mesentery, are found minute organs known as **hemolymph glands** (Warthin). They lie embedded within the fat and connective tissue and are usually the size of a mustard-seed or pea; exceptionally they are larger. The hemolymph glands are lymph-nodules modified by the presence of blood-spaces and the slight development or absence of the lymph-sinuses. The blood-spaces often include a peripheral blood-sinus with irregular central extensions, the lymphoid tissue being correspondingly reduced to trabeculæ surrounded by the vascular channels. All degrees of development of the blood-spaces exist, from the type of the ordinary lymph-nodule on the one hand to that of the spleen on the other. Warthin subdivides the hemolymph glands into two groups, the *splenolymph* and the *marrowlymph glands*, which he regards as transitional forms standing between the lymphatic nodule on the one side and the spleen and the lymphoid marrow respectively on the other.

THE SPLEEN.

The **spleen** may be regarded as a specialized compound lymphatic gland, modified by the arrangement of its blood-supply. The organ is invested by a firm **capsule,** composed of a dense felt-work of bundles of fibrous tissue, with which are mixed numerous elastic fibres. The outer surface of the capsule, with the exception of a limited area, is covered by the **serous coat** of the peritoneum, the union between the two being very intimate.

On the inner surface the capsule is continuous with numerous prolongations, the **trabeculæ.** These penetrate deeply into the interior from all sides, and by the free union of their processes form a spongy **connective-tissue framework** throughout the organ, enclosing an elaborate system of intercommunicating spaces occupied by the lymphoid tissue.

In certain animals (dog, cat, hog) the capsule contains bundles of **involuntary muscle**; these are only exceptionally present in man.

FIG. 148.

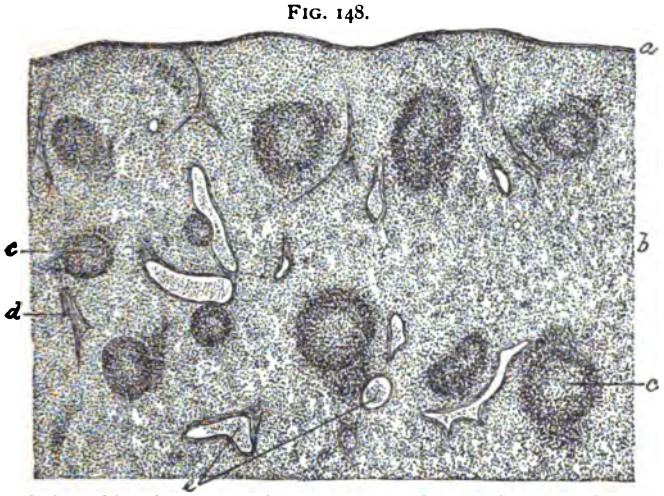

Section of spleen of dog, showing general structure: *a*, capsule, from which trabeculæ extend; sections of these latter are seen in several places, as at *d*; *b*, tissue of splenic pulp; *c*, *c*, Malpighian corpuscles; *e*, sections of blood-vessels.

Likewise, bundles of muscular tissue are constituents of the trabeculæ in many mammals, including man to a limited degree; the muscle-cells are distinguishable from the surrounding connective tissue by their rod-shaped nuclei. The stoutest trabeculæ are found at the hilum, which corresponds to the position at which the larger blood-vessels enter and leave the organ.

FIG. 149.

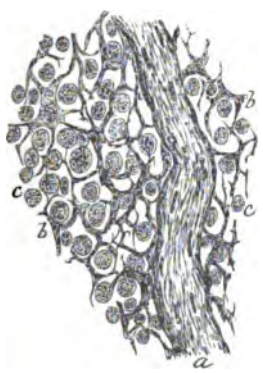

Section of human spleen, showing trabeculæ (*a*) and fibrous reticulum (*b*) continued into the surrounding splenic pulp; *c*, lymphoid cells.

FIG. 150.

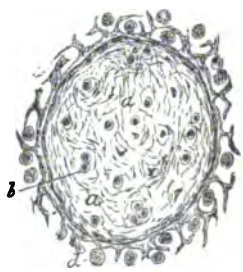

Transverse section of large trabecula of human spleen: *a*, fibrous tissue, containing a few groups of plane muscle-cells (*b*); *c*, extension of trabecula into fibrous reticulum; *d*, lymph-corpuscles.

The **lymphoid tissue** filling the intertrabecular spaces exists in two forms—as the **loose adenoid tissue** which, together with the

intimately related vascular channels, forms the **splenic pulp,** and as the cylindrical or spherical masses of dense adenoid tissue ensheathing the arteries, constituting the **Malpighian corpuscles.**

The central trabeculæ support the branches of the splenic artery; on entering at the hilum, these twigs receive a strong fibrous investment, or adventitious sheath, which accompanies the vessel and becomes gradually reduced as the arteries diminish in size; finally, this sheath blends with the connective-tissue framework of the parenchyma. Most of the terminal branches of the splenic artery are deflected from the trabeculæ and enter the surrounding tissue, where they become ensheathed at irregular intervals by cylindrical or spherical masses of dense adenoid tissue and constitute the Malpighian corpuscles. The **artery** usually pierces the mass somewhat eccentrically, sometimes, however, passing near the centre. Numerous small twigs are distributed to the tissue composing the corpuscles; after forming a net-work they eventually open into the venous channels of the pulp; the main artery of the Malpighian corpuscle has a similar destination.

FIG. 151.



Section of human spleen cutting transversely a Malpighian corpuscle: *a*, section of the somewhat eccentrically situated artery; *b*, capillaries distributed to the tissue of the corpuscle; *l*, the surrounding lymphoid tissue of the splenic pulp.

The **form** of these ensheathing masses of adenoid tissue varies in different animals; in some (guinea-pigs) the arteries are accompanied throughout their entire course by a layer of lymph-cells, while in others (man, cat) the investment is limited to irregularly spherical masses; between these extremes numerous intermediate forms exist. The peripheral zone of the Malpighian corpuscle is usually denser than the central part, an arrangement favoring the sharp demarcation of the body from the surrounding looser parenchyma; in man the corpuscles are less clearly defined than in many lower animals.

The **splenic pulp,** which makes up the larger part of the bulk of the organ, consists of a loose net-work of anastomosing **splenic cords,** composed of a delicate reticulum supporting the cells of the

lymphoid tissue. The reticular fibrillæ unite with one another to form imperfect partitions; in young animals multinucleated plates are frequently encountered. Adhering to the delicate reticulum, partially occluding the channels throughout the pulp, are numerous characteristic lymphoid cells, which are the offspring of the elements forming the adenoid tissue.

FIG. 152.

Portion of channel within splenic pulp from human spleen: *a*, endothelioid connective-tissue plates of the imperfect wall of the space; *b*, red blood-corpuscles; *c*, lymphoid cells; *d*, larger amœboid elements, containing pigment-granules; *e*, large multinucleated cell.

The **spaces of the splenic pulp** are sometimes occupied by numberless colored blood-cells, which escape from the thin-walled vessels into the channels within the pulp; the dark-red appearance of the organ is thus explained. As a result of the breaking down of numerous worn-out red blood-cells,—in which process of destruction the leucocytes may take an active part,—**pigment-granules**, both free and within the lymph-cells, are constantly encountered. The splenic pulp, in addition to giving origin to numerous leucocytes, in common with other lymphoid tissues, is regarded by many histologists as the birthplace, as well as the "graveyard," of a certain number of colored blood-cells; the presence of young nucleated red cells supports this view.

The **blood-vessels** of the spleen form an important part of the organ. After entering at the hilum, the splenic artery gives off trabecular branches which rapidly diminish in size by repeated division. As already described, most of the smaller arteries leave the septa and become ensheathed by the Malpighian corpuscles, to which they contribute with capillary net-works. A small number of the arteries extend the entire length of the trabeculæ, and hence never become encased within the masses of adenoid tissue. The veins lie within the trabeculæ which tend to subdivide the organ into units, the **splenic lobules** of Mall, within the centre of which course the terminal arterial branches. The latter enter the cords of splenic cells and end in delicate and imperfectly walled channels which become continuous with the beginning of the venous radicles within the lobule. The blood-paths are directly surrounded by the lymph-tissue composing the splenic cords. It is probable that under usual conditions the blood is largely retained with the definite vascular channels; extravasations, however, into the spaces of the splenic

pulp readily occur. The venous radicles unite to form more definite intralobular veins which become tributary to the larger venous trunks occupying the trabeculæ. The retarded current within the splenic pulp is favorable to the removal and destruction of the worn-out red cells and to the acquisition of additional leucocytes. Within the pulp, while passing from the arteries to the veins, the blood is probably confined to channels provided with definite walls, but comes into close relation with the lymphoid tissue.

FIG. 153.

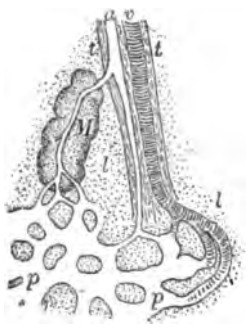

Diagram of the relations of splenic vessels to the tissue of the pulp: *a*, *v*, small arterial and venous branches of splenic vessels within trabecula (*t*, *t*); main twig of artery enters the lobule and becomes ensheathed by tissue of Malpighian corpuscle, *M*; smaller part of artery follows trabecula for a distance before ending in blood-channels (*p*, *p*) surrounded by lymphoid tissue (*l*, *l*); the venous radicles take up the blood from the dilated channels and carry it into the larger veins within the trabeculæ.

The **lymphatics** of the spleen are limited to the connective-tissue framework of the organ, in which they form a **superficial plexus** in the deeper layers of the capsule, and a **deeper plexus** within the trabeculæ. The lymphatic clefts within the adventitia of the arteries communicate with the deeper lymphatics of the trabeculæ; regarding the definite relations of the deeper lymphatics our knowledge is incomplete.

The **nerves** of the spleen are composed mostly of non-medullated fibres, although a few of the medullated variety are present; they are distributed to the walls of the blood-vessels; also ganglion-cells have been observed as small groups situated along the nerve-trunks.

THE THYMUS BODY.

The thymus body is included among the lymphatic tissues on account of the histological characteristics of the fully-developed organ; in its early stages, however, the bulk of the organ is epithelial in nature, being derived from the endodermic cells and closely resembling many glands in its earliest growth. The rapid invasion of mesodermic tissues, at a later period, so changes the character of the organ that tissues of a lymphoid type predominate, while the original epithelial structures are reduced to mere rudimentary remains.

The entire organ usually consists of two **lateral lobes,** more or less intimately united, composed of numbers of **lobules,** held together by the interlobular areolar tissue and enveloped within the general fibrous **capsule** of the organ. The irregularly ovoid **lobules,** 5–10 mm. in diameter, are further divided by connective-tissue septa into compartments, each of which includes several smaller secondary

ıules; these, in turn, are made up of groups of the primary alveoli **follicles.** The latter closely resemble lymph-follicles in structure, ng limited by a rous envelope giv- ; off slender tra- culæ, which are on lost in the deli- te reticulum of nnective tissue rvading all parts the follicles. The eshes of the re- culum are occupied y numerous lym- hoid cells, among hich many capillary lood-vessels run. he adenoid tissue f the peripheral ne, or **cortex,** of e follicles is more sely packed with lls than that occupying the centre, or **medulla,** in consequence of which variation the medulla appears lighter than the denser cortex.

FIG. 154.

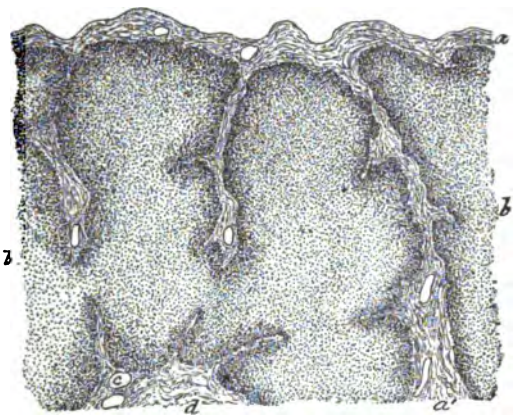

Section of human thymus body, showing general arrangement of follicles: *a*, fibrous tissue enveloping lymphoid tissue and sending septa (*a'*) between the follicles (*b*); *d*, interfollicular tissue, containing blood-vessels (*c*).

Scattered throughout the follicles

FIG. 155.

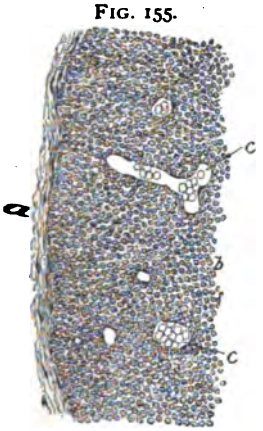

tion of the periphery of one of the folli- of the foregoing section, more highly nified: *a*, fibrous tissue; *b*, lymphoid e, containing numerous capillaries (*c*).

FIG. 156.

Portion of the same follicle, showing corpuscles of Hassall (*a*), which represent the original epithelial constituents of the organ.

nd or oval bodies are seen, which vary greatly in number and size —175 μ), usually stain but faintly, and present an irregularly concen-

tric striation, with occasional nuclei; these bodies are the **corpuscles of Hassall,** or the **concentric corpuscles.** They represent the remains of the epithelial structures which, as already stated, in the early stages of the thymus constitute the principal tissue of the organ.

The larger **blood-vessels** of the thymus run within the interlobular connective tissue, giving off branches which penetrate the follicles and break up into a rich capillary net-work supplying the adenoid tissue of cortex and medulla.

As may be inferred from the character of the organ, the **lymphatics** occur in large numbers. The radicles coming directly from the follicles are received by the interlobular vessels, which, in turn, communicate with the superficial net-work occupying the surface of the organ.

Bundles of **nerve-fibres** accompany the ramifications of the arteries and veins, to the coats of which they seem principally to be distributed.

The thymus body reaches its **highest development** about the second year, after which time it gradually diminishes, undergoing retrogressive changes and absorption, until, by the eighteenth to the twenty-first year, the characteristic tissues have disappeared or have been replaced by fibrous connective tissue and fat.

THE SEROUS MEMBRANES.

The serous membranes are intimately related to the lymphatic system, since the cavities which they enclose form parts of the general lymph-tract of the body; when considered in their widest significance they include the lining of all cavities clothed with endothelial cells and cut off from atmosphere. Regarded in a more limited and critical sense, such cavities may be separated into certain groups, following which the connective-tissue linings may be divided into:

a. The serous membranes proper, as the peritoneum, the pleura, and the pericardium.

b. The synovial membranes, including the synovial capsules of the joints, the synovial sheaths of tendon, and the synovial bursæ placed between opposed movable surfaces to reduce friction.

c. The endothelial lining of the vascular system, comprising that of the heart, of the blood-vessels, and of the lymphatics.

d. The lining of various spaces developed within the connective tissues; such spaces are usually small and provided with very rudimentary linings; they may be, however, of considerable size, as in the case of the perilymphatic spaces of the internal ear.

The **serous membranes proper,** represented by the peritoneum, the pleura, the pericardium, and the tunica vaginalis, are all derived as constrictions from the originally single **pleuro-peritoneal** cavity

first formed. In the closed sacs constituted by the serous membranes a **parietal** and a **visceral layer** are always distinguishable; the connection of these with the subjacent structures is slight or intimate according to the character and amount of the subserous tissue.

Every organ which projects beyond the wall of the serous pouch into its cavity must be enveloped by the serous membrane to a greater or less degree. When the organ remains closely attached to the wall of the body-cavity, as does the kidney, it obtains only a partial serous investment; where, on the other hand, the organ leaves the parietes and encroaches upon the cavity, the serous investment becomes almost complete, as in the case of the small intestines. In all cases the viscera lie outside the serous sac, the membrane which constitutes the lining of the space being pushed before the encroaching organ to form a serous covering more or less complete. The serous cavity of greatest extent—that of the peritoneum—in the female presents an exceptional arrangement in possessing outlets at the orifices of the oviducts; in this connection, however, it must be remembered that the oviduct is the persistent Müllerian duct, which is only one of a number of tubes formed during early fœtal life by evagination of the primary serous membrane, thus establishing communication with surfaces exterior to the serous cavity. While such tubes in the higher animals are only transient, in the lower types they may remain as permanent structures.

FIG. 157.

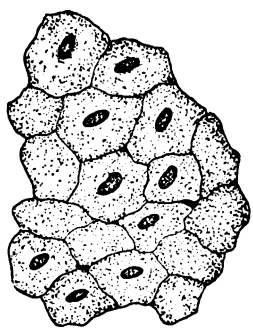

Peritoneal endothelium of dog, silver-stained; several pseudo-stomata are seen as dark areas among the cells.

The **serous membranes** are sufficiently thin and transparent to permit the color of the underlying parts to be seen readily through them; moderate strength, extensibility, and elasticity are among their physical properties. These membranes consist of the **endothelium** covering their free surface and resting upon the connective-tissue stroma, which constitutes the chief substance of the membrane; external to this layer a variable amount of **subserous tissue** usually is present. The endothelium comprises a single layer of the large, thin, irregularly-polyhedral connective-tissue plates already described and figured in Chapter II.

In addition to the minute deeply-stained intercellular areas, or pseudo-stomata, true openings, or **stomata,** also exist occasionally in serous membranes. These orifices are especially well seen in silver preparations from the posterior wall of the frog's peritoneal

cavity (Fig. 30); but they are seldom demonstrable in the tissues of man and of the higher animals: the central tendon of the diaphragm, on which they were first discovered in the peritoneum by von Recklinghausen, offers a favorable place for their study. In addition to the stomata occurring in the peritoneum covering the diaphragm, similar apertures have been described in the omentum, the pleura, and the pericardium. Their existence is, however, doubtful. The stomata lead into the subjacent lymphatic vessels and are surrounded by cuboidal or spherical guard-cells.

FIG. 158.

Peritoneum in section from dog: *p*, peritoneum proper, consisting of endothelium of free surface and subendothelial fibrous stroma containing network of elastic fibres; *s*, subperitoneal vascular connective tissue.

The **stroma** of the serous membranes consists of interlacing bundles of white fibrous tissue, mingled with elastic fibres, which are especially numerous in the more superficial parts, where they frequently form a reticular layer. The interstices between the fibrous bundles are occupied by the **ground-substance**; the latter after a time in some cases, as in the omentum, suffers local absorption, interfascicular orifices then partially taking its place. The serous membrane, which in its earlier condition forms a continuous sheet, may become riddled with apertures, and is said to be fenestrated. Where the ground-substance and stroma are well developed and of considerable thickness, particularly in the vicinity of folds, adipose and sometimes lymphoid tissue occur in addition to the blood-vessels and lymphatics. The ground-substance in places where dense is penetrated by an intercommunicating system of **lymph-spaces** opening into the lymphatic vessels of the serous membrane. Branched **connective-tissue cells** are also frequently seen with processes extending between the endothelial plates of the free surface; such processes when stained with silver probably form the pseudo-stomata already mentioned; other protoplasmic extensions of the cells may come into relation with the walls of the blood-vessels or of the larger lymphatics.

The **subserous layer,** where well developed, is composed of loosely-arranged bundles of fibro-elastic tissue, between which blood-vessels and lymphatics, with migratory leucocytes, are situated.

The **blood-vessels** of serous membranes contribute wide-meshed net-works both to the layer of proper stroma and to the subserous tissue; in positions where tracts of adipose or of lymphoid tissue exist, the capillaries form net-works enclosing the fat-sacs or the lymphoid masses.

The **lymphatics** of serous membranes are very numerous, and are represented by the definite lymphatic vessels and the lymph-spaces

within the ground-substance; by means of the stomata and the minute passages leading from them the lymphatics communicate with the serous cavities, while, on the other hand, they join with the wide, irregular lymph-channels within the subserous tissue.

The **nerves** supplying these membranes are limited, those which are present being largely derived from the sympathetic system, composed of pale, non-medullated fibres destined chiefly for the blood-vessels. The few fibres passing into the substance of the membrane form a loose reticulum throughout its deeper layers, from which finer fibrillæ extend beneath the surface.

The **synovial membranes,** which constitute a second group of serous membranes, include the lining of the clefts developed within the connective tissue (mesoderm) surrounding opposed movable surfaces, embracing the capsules enclosing the articulating surfaces of the various joints, the synovial sheaths in which the tendons glide, and the bursal sacs interposed between surfaces; these varieties of synovial membranes are known respectively as the **articular,** the **vaginal,** and the **vesicular. Synovial membranes** differ from the serous in the character of their secretion; that of the former—the **synovia**—is a glairy, viscid fluid, resembling the white of egg, well adapted for the lubrication of the opposed parts, and contains fat particles, lymphoid cells, and degenerated endothelial plates.

FIG. 159.

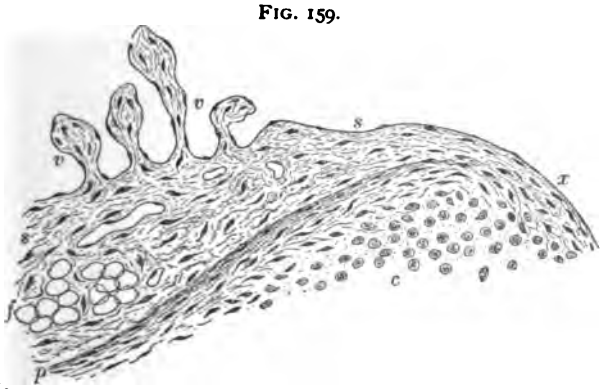

Section of synovial membrane at edge of articular surface: *s*, *s*, tissue of synovial membrane bearing villous projections (*v*, *v*); *x*, position at which tissues of membrane become continuous with those of periphery of cartilage; *f*, group of fat-cells; *p*, fibrous tissue constituting peripheral zone of cartilage (*c*).

The secretion moistening serous membranes is thinner, watery, and less suited to the reduction of friction.

The **articular synovial membranes** surround the joints, tightly embracing the bones and enclosing them within their sacs, but do not extend over the articulating surfaces, which are composed of

naked cartilage, over whose surfaces of contact not even the imperfect endothelial covering is continued; tendons or other structures traversing the joint-cavity receive an investment of the synovial membrane. The **marginal zone,** embracing the attachment of the membrane to the cartilage, is marked by the gradual alteration of the tissues of the synovial membrane to assume the characters first of fibro-cartilage, and finally of the typical articular cartilage of which the membrane then seems a part.

The **synovial sacs,** originating as clefts within the mesoderm surrounding the extremities of the young bones, exhibit a structure corresponding to slightly condensed connective tissue. The **membrane** is composed chiefly of closely-felted bundles of fibrous tissue, mingled with elastic fibres, containing the usual connective-tissue elements; the free surface of the membrane possesses an imperfect **covering of connective-tissue cells,** which, when closely placed, as in the younger tissue, present the characters of an endothelium; when less densely arranged, they retain their processes and appear as branched elements, resembling those of other dense fibrous tissues; in the vaginal membranes the cells are often elongated to correspond with the axis of the sheath.

Cleft folds of the synovial membrane project into the serous cavity as the **Haversian fringes**; they are free processes of the membrane containing vascular loops and, in the larger ones, fat; the smaller **secondary fringes,** or villi, often present as finger-like processes attached to the edges of the larger folds, contain no blood-vessels, but consist principally of small, irregularly-round cells, separated by a scanty intercellular substance. In some cases these villi enclose a denser core, which consists of fibrous bundles; occasionally the entire villus is formed of fibro-cartilage, the superficial round cells being wanting.

Blood-vessels are quite numerous within the synovial membranes, as well as in the subjacent tissues, nearly all parts of the joints being generously supplied. Many of the Haversian fringes contain vascular tufts, while the termination of the blood-vessels around the margin of the cartilages is marked by vascular loops possessing greatly dilated terminal arches.

The **nerves** of the synovial membranes, by no means numerous, form a loose plexus beneath the free surface; in connection with the joints, peculiar special nerve-endings, the **articular end-bulbs** of Krause, have been found attached to the nerve-fibres; Pacinian corpuscles have likewise been observed in relation with the synovial membranes.

The serous surfaces lining the blood-vessels and the lymphatic

channels and spaces have been considered in connection with their respective systems.

The **development of the lymphatic system** in all its parts involves the mesoderm alone. Very early in the life-history of the embryo, shortly after the appearance of the three blastodermic layers, the **mesoderm undergoes cleavage** into two leaves, the separation affecting the mesodermic layer on either side as far as the lateral margin of the uncleft axial band. The resulting sheets of mesodermic tissue become the **parietal layer** (*somatopleuric*) and **visceral layer** (*splanchnopleuric*); the former clings to the ectoderm to become the future wall of the body-cavity, while the latter adheres to the entoderm to form the wall of the digestive tube.

The space included between these leaves is the **primitive body-cavity**, or **cœlom**, and the mesodermic tissue forming its immediate wall becomes differentiated into a special lining—the **mesothelium**—whose elements are the ancestors of the later endothelium.

FIG. 160.

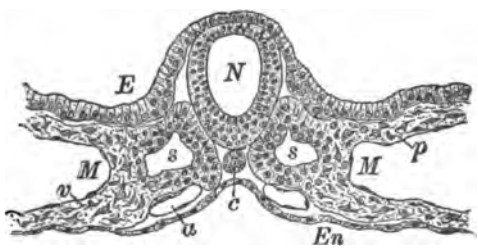

Transverse section of ten-day rabbit embryo, showing the cleavage of the mesoderm and the formation of the primary body-cavity: *E*, ectoderm; *M*, *M*, the letters occupy the body-cavity and have the parietal (*p*) and visceral (*v*) layers of the cleft mesoderm respectively above and below them; the immediate lining of the cavity constitutes the mesothelium; *En*, entoderm; *N*, neural canal; *c*, notochord; *s*, *s*, cavities within the somites—really parts of the body-cavity; *a*, one of the paired primitive aortæ.

The fully-formed **serous membranes**, represented by the peritoneum, the pleura, the pericardium, and the tunica vaginalis, are all derived as **constrictions** from the common pleuro-peritoneal sac, or body-cavity, first formed, the subdivision of which into the above-mentioned special serous compartments occurs secondarily and at a much later period.

Bearing in mind the origin of the primary lining of the serous membranes, the claims of endothelium to near kinship with connective tissue must be admitted; likewise, the reasons for regarding endothelium as distinct in nature from epithelium will be appreciated. Inasmuch as the epithelium of the genito-urinary tract is derived indirectly from the mesoderm, it is related genetically to the endothelium of the abdominal serous membrane.

In the course of the differentiation and growth of the fibrous connective tissue, clefts appear within the ground-substance between the bundles of young tissue, which become the **lymph-spaces** of the

maturer stages. The formation of the **lymphatic vessels** takes place in a manner very similar to that by which the blood-channels are produced. The protoplasmic net-works established by the united processes of the connective-tissue corpuscles are at first solid; subsequently they acquire a lumen and become converted into a series of protoplasmic tubes, the nuclei of whose endothelial plates are derived from the proliferated nucleus of the original elements. The earliest **lymph-corpuscles** are, probably, migrated mesoblastic cells which have entered the young vessels. The additional coats of the larger lymphatic trunks are derived from the condensation and differentiation of the surrounding young connective tissue.

The **development of the lymphoid tissue** occurs at a relatively late period. The position of the future lymph-gland is indicated by a cleft or fissure which appears within the mesoderm and completely isolates the gland-area on all sides except that destined to become the future hilum, where the tissue devoted to the production of the gland and the surrounding mesoderm are continuous. The development of the lymphoid tissue is marked by increased numbers and greater compactness of the mesodermic elements; the supporting reticulum, the capsule, and other details of the adenoid tissue appear later.

The **development of the spleen** begins about the commencement of the third month, some time after the pancreas has become defined; a **condensation of the mesodermic cells,** lymphoid in character, within the posterior mesentery, or the **mesogastrium,** in the near vicinity of the pancreas, is the earliest indication of the future organ. The lymphoid aggregation first established is supplemented by the elements lying beneath the peritoneum, which differentiate into elongated spindle-cells especially devoted to the formation of the **trabeculæ** and **connective-tissue framework.** Numerous blood-vessels soon grow into the splenic tissue, the subsequent accumulations of lymphoid cells within the tissue around some branches of the arteries giving rise to the **Malpighian corpuscles.**

The history of the **development of the thymus body** demonstrates an origin markedly at variance with the character of the fully-formed organ, since, notwithstanding the pronounced lymphatic type of the tissue constituting almost the entire body when most complete, its structure in the earliest stages corresponds entirely to embryonal epithelium which is derived as the **direct outgrowth of the entoderm.** The first trace of the thymus body appears as a cylindrical bud of entodermic tissue springing on either side from the **third pharyngeal pouch,** or inner visceral furrow. The epithelial nature of the early thymus is for some time very evident, the original cell-

mass appearing also similar to the earliest stage of a glandular area; repeated division rapidly converts the at first simple cylindrical aggregation into a complex figure, in which an elongated main part bears numerous lateral branches. At a later period the surrounding **mesoderm** becomes richer in cells and more compact and grows into the original epithelial structure, the result of which invasion is the final complete atrophy and disappearance of the epithelial constituents, with the exception of the inconspicuous but constant **corpuscles of Hassall**, which alone bear witness to the primary epithelial nature of the organ.

CHAPTER IX.

MUCOUS MEMBRANES AND GLANDS.

ALL passages and cavities directly or indirectly communicating with the exterior of the body and the atmosphere are lined by mucous membranes.

These structures consist of two parts: the connective-tissue **stroma,** or **tunica propria,** and the **epithelial covering;** the outer surface of the connective-tissue layer is quite usually specialized to form an extremely delicate **basement-membrane, or membrana propria,** which thus separates the epithelium from the underlying tissue and forms a third constituent of the mucous membrane. The basement-membrane is often scarcely demonstrable as a distinct layer, while in certain organs, as many glands or the hair-follicles, it is highly developed.

FIG. 161.

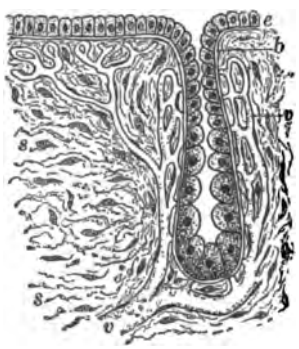

Diagram of a typical mucous membrane: *e*, epithelium of free surface continuing into the glandular depression to become the secreting cells; *b*, basement-membrane separating epithelium and connective-tissue stroma; *s*, *s*, fibro-elastic tissue of tunica propria; *v*, blood vessels forming net-works beneath epithelium and around gland.

The **epithelium** of mucous surfaces varies both in character and in arrangement, as already described in Chapter II. The proper substance or **stroma** of the mucous membrane consists of a felt-work of bands of fibrous connective tissue together with net-works of elastic fibres; these latter may be so plentiful that an especial elastic layer is formed, as in parts of the respiratory tract. Numerous connective-tissue cells lie between or upon the fibrous bundles, the flattened plate-like cells forming in many places partial linings for the interfascicular lymph-spaces found throughout this layer.

Not infrequently the surface of the connective-tissue stroma is beset with numerous elevations or **papillæ,** over which the epithelium extends. Such irregularities, when slight, may be present without impressing the free surface of the mucous membrane, since the epithelial layer completely fills the depressions between the elevations: when very pronounced, the papillæ or folds of the connective tissue produce such conspicuous sculpturings of the surface as the papillæ of the tongue or the rugæ of the vagina.

Mucous membranes may be invaded to a greater or less degree by **lymphoid cells,** as in many localities in the digestive tract; sometimes, as in the villi of the small intestine, the tissue assumes still more closely the lymphoid type, a delicate connective-tissue reticulum supporting the lymphoid cells.

The **membrana propria,** or **basement-membrane,** usually appears as a delicate homogeneous line beneath the epithelium. It must be regarded as a modification of the connective tissue, and when well developed, after suitable staining with silver, appears as a more or less complete covering of flattened, endothelioid cell-plates. The deeper layers of the mucous membrane fade away into the surrounding areolar tissue or into the adjacent submucosa; sometimes, however, the mucosa is limited by a delicate zone of involuntary muscle, the **muscularis mucosæ,** consisting often of two distinct, although delicate, layers of muscle-cells.

FIG. 162.

Plate-like endothelioid connective-tissue cells constituting basement-membrane.

Mucous membranes are usually provided with **glands,** which in their simplest type are depressed portions of the general mucous surface, lined with modified epithelium—the secreting cells. A single cell may constitute an entire gland, instances of such arrangement being found in the **unicellular glands** of the lower forms; the familiar goblet-cells are, in fact, such structures; it is, however, the more developed forms of secreting apparatus which the term "gland" usually represents.

Glands are of two chief varieties, **tubular** and **saccular,** each of these occurring as **simple** and **compound.** Simple tubular

FIG. 163.

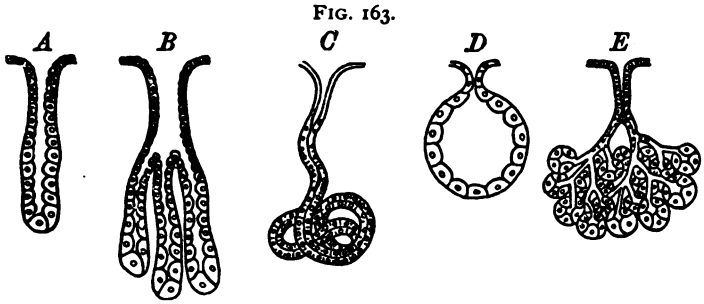

Diagram illustrating the forms of glands: *A*, simple tubular; *B*, compound tubular; *C*, modified (coiled) tubular; *D*, simple saccular; *E*, compound saccular, or racemose.

glands are frequent, the peptic glands and the mucous follicles of the intestines being well-known examples. **Compound tubular glands** vary in complexity, from a simple bifurcation of the fundus,

as in many pyloric or uterine glands, to the intricate arrangement of the tubules of the kidney or the testicle.

Simple saccular glands do not occur in the higher animals, but are conspicuous in the lower types, as in the integument of amphibians. **Compound saccular, or racemose, glands,** on the other hand, are represented in man and mammals by such important organs as the pancreas and the salivary glands.

In the least complex type of gland, the simple tubular, the **two fundamental parts** of all glands are distinguishable in their primitive form : these are the deeper actively secreting portion, the **fundus,** and the superficial division, or **duct,** through which the products of the secreting cells escape. Dilatation of the fundus of the primitive type produces the simple saccular gland ; division of the fundus and of part of the duct originates the compound tubular variety ; repeated cleavage and subdivision of the duct, with accompanying expansion of the associated terminal tracts, lead to the production of the compound saccular, or racemose, type.

The **tubular glands** may exist as perfectly straight cylindrical depressions ; more usually, however, the tubes are somewhat wavy or tortuous : when the torsion of the fundus reaches its highest expression, such modifications as the coiled sweat-glands result.

FIG. 164.

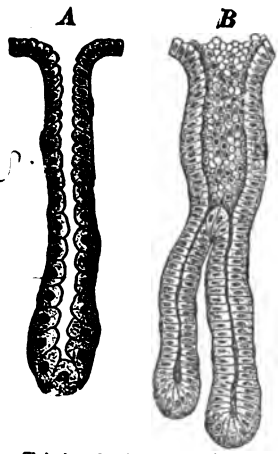

Tubular glands : *A*, simple tubular crypt from human small intestine ; *B*, compound tubular gland from pyloric end of human stomach.

Glandular epithelium is the direct derivative of the cells covering the adjacent mucous membrane, so modified and specialized as to adapt it to the requirements of the several parts of the gland. In simple tubular follicles the cells of the adjacent free surface pass into those lining the neck of the gland with little change ; cells of the increased size and spherical form become more pronounced towards the fundus, where the elements assume the characters of secreting epithelium. The cells lining the upper part of the duct of such glands not infrequently exhibit a distinctly imbricated arrangement ; this is well seen in the peptic glands.

The greater complexity of the **racemose glands** resulting from the system of freely branching excretory tubes renders the recognition of several parts desirable. These are, towards the ducts, proceeding from the terminal compartments, the **alveoli** or **acini,** the **intercalated** or **intermediate tubules,** the **intralobular tubes,** the **interlobular**

ducts, and the **excretory ducts,** which latter usually unite to form a single **common duct** of large size.

At the open end of the acinus the lining cells of the latter become flattened or cuboidal, and, together with the basement-membrane, are directly continuous with the similar structures forming the walls of the narrow **intermediate tubule;** the latter succeeds the acinus as the continuation of the narrow intercellular clefts of several adjacent acini, and, after a longer or shorter course as a delicate narrow-lumened canal, passes into the **intralobular tube.** The distinctive characters of the latter are its larger lumen and the columnar epithelium, many cells of which exhibit a distinct vertical striation throughout the peripheral zone next the basement-membrane. The branching intralobular tubes, on emerging from the lobular tissue, join to form the interlobular duct which occupies the connective tissue lying between and holding together the divisions of the glandular sub-

FIG. 165.

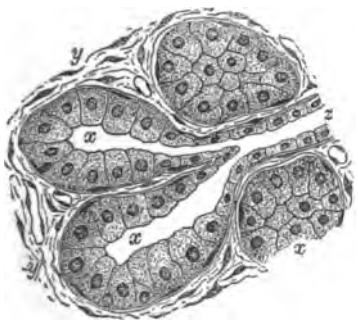

Section of racemose gland showing relation of glandular tissue to origin of duct: *x*, acini lined with secreting cells which are directly continuous with those of the intermediate tubule (*z*); *y*, interlobular connective tissue.

FIG. 166.

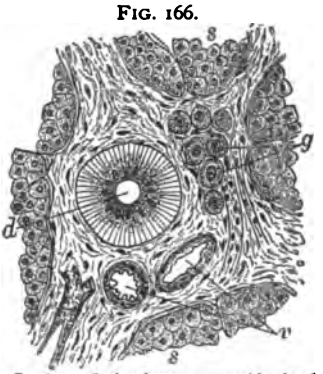

Section of the human parotid gland showing the interlobular tissue: *s*, *s*, secreting cells of surrounding acini; *d*, interlobular duct; *v*, blood-vessels within the fibrous tissue; *g*, group of ganglion-cells.

stance. The **interlobular ducts** are clothed with simple columnar cells, which form a passive lining to the canal for the conveyance of the secretions of the more active parts of the gland. Towards the free surface of the mucous membrane the interlobular ducts unite to form the chief, often single, **excretory duct** of large lumen, whose walls for a variable distance from the point of discharge are covered with epithelium similar to that covering the adjoining mucous surface; this is soon replaced, however, by the columnar cells which then continue into the smaller tubes. In the large ducts the subepithelial tissue is strengthened by net-works of elastic fibres.

The **saccules** or **alveoli** are limited by a basement-membrane

upon which rests a single layer of irregularly spherical or polygonal secreting cells; these latter do not entirely fill the acinus, but leave an intra-cellular cleft, in which the system of tubes for the conveyance of the secretions commences.

Glands are often divided into **serous** and **mucous,** a differentiation depending upon the peculiarities of the cells lining the acini as well as upon the character of their secretion. The cells of the **serous glands** are distinguished by being distinctly granular, generally spherical in form, readily and deeply stained with carmine, and by having conspicuous nuclei situated near the centre of the cells; the elements of the **mucous glands,** on the contrary, are distended,

FIG. 167.

Serous acini of human parotid gland; the deeply-staining granular cells are surrounded by the basement-membrane.

FIG. 168.

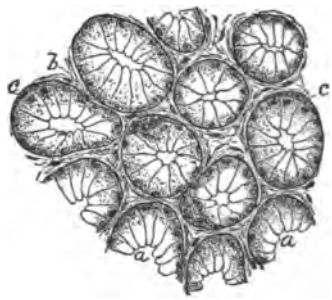

Mucous acini of human lingual gland: the secreting cells (*a*), being loaded with the slightly-staining secretion, appear clear and transparent; *c*, *c*, crescentic masses of granular cells—the demi-lunes of Heidenhain; *b*, interacinous connective tissue.

very clear and transparent, slightly stained with carmine, and have the nuclei displaced to the outer edge of the cells, not infrequently immediately beneath the basement-membrane. In the embryonal pre-functionating condition these two kinds of glands are identical, both as to mode of origin and histological characteristics; the variations and the conspicuous differences subsequently appearing depend on differences of physiological function and character of secretions, and not on structural differences in the original cells.

Fluids elaborated by the serous glands are thin and watery, appearing within the protoplasm of the secreting cells as minute dark granules; the general appearance of the cells depends upon the number of these granules stored up within their protoplasm. When a **serous gland** is in a **condition of rest,** the cells are loaded with granules, and when stained they appear larger, clearer, and coarsely granular; **after active secretion** the cells are exhausted and contain fewer granules, appearing, therefore, smaller, darker, and finely granular.

The **mucous glands** secrete a clear, viscid, homogeneous substance, or **mucine**, having little affinity for carmine, but staining deeply with hæmatoxylin. **During rest** the cells of such glands become loaded and distended with the mucoid secretion, while the nuclei are crowded to the periphery of the cells; under these conditions the cells lining the acini appear clear with well-defined outlines, and, on the sides next the basement-membrane, present a thin zone containing the displaced nuclei and granular protoplasm. **After prolonged secretion** the exhausted cells contain relatively little mucoid substance; hence the threads of the protoplasm are no longer widely separated, but are more closely placed; in consequence of these changes the cells assume appearances resembling those of the elements of the serous glands, being smaller, darker, and more granular than the cells of the quiescent mucous gland.

FIG. 169.

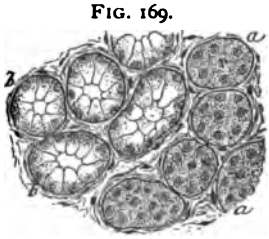

Lingual glands from tongue of cat: *a*, *b*, the serous and the mucous acini containing respectively the granular and the clear cells.

In the acini of mucous glands small crescentic groups of granular, deeply-staining cells are often seen lying between the clearer elements and the basement-membrane; these are the **crescents of Gianuzzi**, or the **demi-lunes of Heidenhain**, the significance of which has caused extended discussion. The recent researches of

FIG. 170.

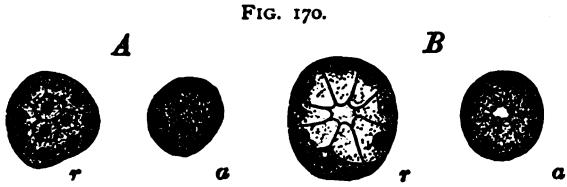

A and *B*, serous and mucous acini in different stages of functional activity: *r*, condition of rest, the cells being gorged with secretion; *a*, condition of exhaustion after great activity: following the discharge of the secretion the elements of the protoplasm become more closely placed, producing an appearance of increased granularity.

Küchenmeister, Solger, R. Krause, and others, have shown that these crescents are composed of cells identical with those filling the acini of the serous glands. The crescents, therefore, are groups of serous cells, compressed and displaced by the preponderating mucous elements, which add their albuminous secretion to that of the mucous gland. Glands containing the crescents are to be classed as mixed, or muco-serous.

The **vascular supply** of glands is always rich. The larger blood-vessels, conveyed by the submucosa, send off branches into the

mucosa to break up into capillaries which enclose the tubules and acini in close net-works, lying outside but in intimate relation with the basement-membrane, an arrangement favoring the passage of substances from the blood into the protoplasm of the secreting cells, which are thus placed between the blood-current on the one hand and the lumen of the gland on the other.

Numerous **lymphatic spaces** are contained within the connective tissue surrounding the acini and the tubules, some of the clefts being immediately beneath the membrana propria and in close relation with the gland.

The **nerve-supply** of glandular structures is often very rich. The nerve-trunks accompany the larger blood-vessels in the submucous tissue and give off numerous small bundles which follow the smaller arteries in their distribution to the mucosa, where they form delicate plexuses about the acini and the tubules immediately outside the basement-membrane. The exact mode of the final termination of the nerves and their relation to the individual secreting cells are still matters for investigation; whether the fibres pierce the basement-membrane to terminate among the glandular epithelium, while probable, must be regarded as still unproved.

FIG. 171.

Developing salivary gland from fifteen-day rabbit embryo. The ectodermic ingrowth has divided into secondary branches which terminate in slightly expanded club-shaped ends: *e*, epithelium of oral surface; *m*, young connective tissue of future tunica propria into which the epithelium grows.

The **development of glands** proceeds from the epithelial tissue of the young mucous membrane, the penetrating cylinder of epithelium representing ectodermic or entodermic tissue, except in those cases where the glands are formed in connection with the parts of the genito-urinary tract derived entirely from the mesoderm.

The **first trace** of the glands consists of a cylindrical **ingrowth of the epithelium** into the subjacent mesodermic tissue, both the tubular and the saccular glands alike starting as simple epithelial processes. Where, however, the structure is destined to become a gland of the racemose type, the branching cords of epithelial elements early indicate the nature of the future gland as distinguished from one of the compound tubular variety; since, in this case, the terminations of the epithelial masses soon become markedly expanded and club-shaped, from which dilatations the ultimate divisions or primary alveoli of the racemose glands are extended secondarily. The epithelial cords, at first solid, later acquire a lumen which extends as far as the terminal compartments of the gland. Sometimes, as conspicuously instanced by the liver,

the primary arrangement of the gland is modified by subsequent changes to such a degree that the original plan of its structure is recognized with difficulty. The sexual glands are so highly specialized that in their development they deviate materially from the mode of the formation of the typical secretory organs. Ordinarily the elaborating glandular cells are ectodermic and entodermic in origin, while the basement-membranes and supporting tissues are mesodermic.

CHAPTER X.

THE DIGESTIVE TRACT.

THE MOUTH.

THE **mucous membrane** of the oral cavity consists of the epithelial covering and the connective-tissue stroma or tunica propria; the deeper layers of the latter fade insensibly into the subjacent tissues which unite the mucous membrane with the surrounding deeper parts. The **epithelium** lining the entire oral cavity is of the stratified squamous variety, continuous with the epidermis on the one hand and with the covering of the pharynx on the other.

The **tunica propria** is composed of interlacing bundles of fibrous connective tissue containing elastic networks, and possesses numerous simple papillæ which encroach on the epithelial layer, but do not appear on the free surface of the mucous membrane. The latter is broken in many places by the openings of the ducts of the numerous glands which occupy the submucosa and deeper parts of the mucosa.

FIG. 172.

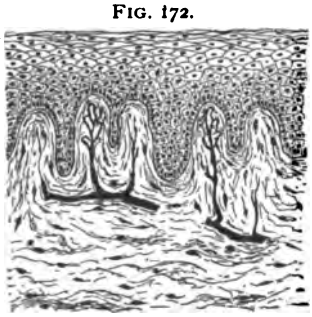

Section of oral mucous membrane of child; the surface of the fibrous tunica propria is broken by minute papillæ, which contain the endings of the blood-vessels and the nerves. The papillæ are covered by the stratified squamous epithelium.

In the transition of the skin on the lips, where the skin passes into the mucous membrane, the epithelium is greatly thickened, while the connective tissue layer decreases in thickness; the subepithelial papillæ here become very prominent. The hair-follicles disappear but the sebaceous glands still are present, especially near the angles of the mouth and in the upper lip. The mucous membrane covering the cheeks adheres tightly to the buccinator muscle, and possesses small papillæ; that covering the gum is dense, and contains numerous well-marked papillæ beneath the epithelium, the submucous tissue being closely united with the periosteum. The portion covering the hard palate is thin and firmly united to the periosteum, while that investing the soft palate, the uvula, and the fauces is much thicker, less dense, possesses numerous mucous glands, and, in many places, is so densely crowded with lymphoid cells that the entire mucous membrane assumes the appearance of adenoid tissue.

The oral mucous membrane is thickly beset with small mucous racemose **glands** in nearly all parts. These are especially well marked on the lips, the cheeks, the under surface of the tongue, and the soft palate, constituting, respectively, the labial, the buccal, the lingual, and the palatine glands; on the gums and the hard palate such structures are absent or present in very limited numbers. The acini are situated within the deeper layers of the mucosa, while the ducts pierce the superficial layers to open on the free surface. The squamous epithelium of the latter is continued within the duct usually as far as its first division. Small lateral isolated groups of acini, constituting accessory mucous glands, sometimes open into the long narrow excretory duct of the main glandular mass during its journey to the free surface.

The larger **blood-vessels** supplying the oral mucous membrane lie within the submucous tissue and give off branches which extend through the deeper layers of the mucosa to the superficial portions of the connective-tissue stratum; on reaching the outer boundary of the latter the arteries break up into rich subepithelial capillary net-works, or, where papillæ are present, enter the minute elevations to supply their apices with terminal capillary loops. The capillaries likewise enclose the acini of the oral glands.

The **lymphatics** begin in the irregular net-work of interfascicular spaces between the connective-tissue bundles of the tunica propria; these spaces unite to form definite lymphatics in the deepest layers of the mucosa, which in turn are taken up by the larger lymph-vessels of the submucous tissues.

Nerve-fibres, largely of the medullated variety, accompany the blood-vessels, and form a subepithelial plexus; special terminations —the end-bulbs—are found in the apices of some of the papillæ, while additional numerous tactile corpuscles occur on the lips.

THE TEETH.

In principle, and among many of the lower animals in fact as well, the teeth may be regarded as hardened papillæ of the oral mucous membrane.

The **teeth** are firmly retained within their appropriate sockets by the alveolar periosteum, the **peridentinal membrane**, which holds together the alveolus and the root of the tooth. The periosteum lining the alveolus is composed of dense fibrous tissue, whose fibres have a general transverse disposition: elastic tissue is almost wanting, nerves and blood-vessels being, however, numerous. At its **neck** the tooth is especially embraced by the thickened periosteum, which then becomes continuous with the periosteum covering the alveolar process of the jaw and with the gum.

The tooth comprises the **dentine**, the **enamel**, and the **cementum**.

The **dentine**, or **ivory**, principally contributes the bulk and the characteristic form of the tooth, completely enclosing a central pulp cavity, except where the narrow nutrient canal, admitting the blood vessels and nerves to the pulp, pierces the apex of the fang. The dentine is composed of a matrix or **ground-substance**, which, as that of bone, must be regarded as modified connective tissue, formed of bundles of fibrous tissue intimately united and subsequently impregnated with calcareous salts.

FIG. 173.

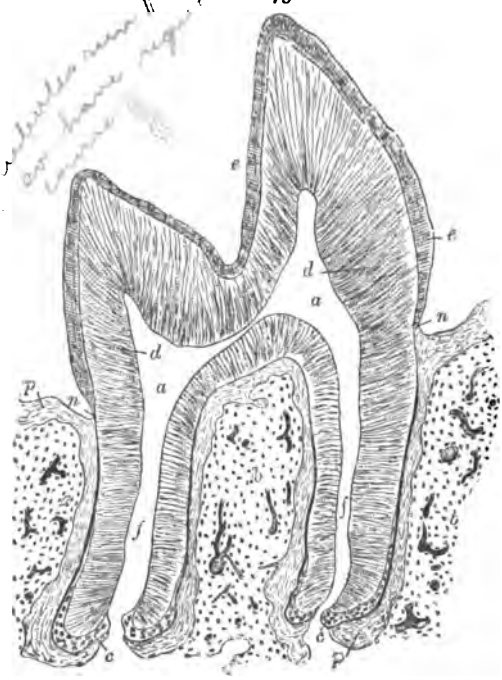

Longitudinal section of molar tooth of kitten: *a*, pulp-cavity, continued by canals (*f*) to apices of roots; *d*, dentine; *e*, enamel; *c*, cementum; *p*, alveolar periosteum; *n*, neck of tooth; *b*, osseous tissue of jaw.

Piercing the ground-substance and appearing under low amplification as a radial striation, the **dentinal tubules** extend the entire thickness of the dentine as minute channels; they are seen especially well in sections of the dried tooth in which the canals are filled with air. Starting from the pulp-surface with a diameter of 2.0–2.6 μ, the dentinal tubules pass in a slightly wavy and spiral course through the dentine, to terminate in irregular clefts, the **interglobular spaces**, situated at the juncture of the dentine with the enamel or the cementum.

FIG. 174.



Section of dried human tooth showing portions of enamel and dentine: *a*, ground-substance of dentine; *b*, branching dentinal tubules; *c*, terminal zone of tubules within the enamel (*d*).

The tubules give off numerous secondary canals along their course, by which means the adjacent tubules communicate; on approaching the enamel or the cement the tubules undergo repeated division, the resulting smaller secondary channels corresponding in their general direction with the larger canals.

The marked parallel curves described by the dentinal tubules produce optical effects which are appreciated as a coarse striation concentric with the outline of the pulp-cavity; these appearances, known as **Schreger's lines,** may be seen in sections with the unaided eye. That part of the dentinal matrix immediately surrounding the tubules is especially dense and resistant, and constitutes the so-called **dentinal sheaths** which may be isolated by acids. Within the tubules lie the delicate **dentinal fibres,** which are the modified processes of the connective-tissue cells forming the peripheral layer of pulp-cells. When cut across the tubules appear circular or slightly oval, and contain a minute dot, the dentinal fibre in transverse section. Want of uniformity in the calcification of the outer zone of dentine gives rise to the **incremental lines of Salter.**

The **interglobular spaces** are irregular stellate intercommunicating clefts situated at the outer margin of the dentine, traversed by some of the dentinal tubules. The walls of these spaces pre-

FIG. 175.

Interglobular spaces of dentine from dried human tooth: *i*, *i*, spaces into which certain dentinal tubules (*d*) open.

FIG. 176.

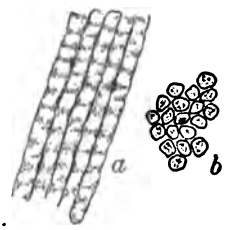

Section of enamel from dried human tooth: *a*, *b*, longitudinal and transverse views of enamel rods.

sent numerous minute spherical projections, the **dentinal globules,** produced during calcification of the dentine.

The **enamel** covers the exposed parts of the softer underlying dentine, and is composed of irregular 4–6-sided columns, the **enamel prisms,** closely placed and generally vertical to the surface of the dentine. After suitable isolation the enamel prisms appear slightly varicose in outline, the minute concavities producing the irregular dark bands often seen traversing the prisms. The prisms are held together by a delicate layer of cement-substance and grouped into

bundles which cross one another, producing the alternate dark and light radial **prism-stripes of Schreger.** The additional dark lines extending more or less parallel to the free surface of the tooth—the **stripes of Retzius**—are probably due to inequalities in growth and density. At birth, and for a variable time thereafter, the outer surface of the enamel is covered by a delicate but resistant cuticle, the **membrane of Nasmyth,** composed of uncalcified enamel and the remains of the enamel organ. This cuticle is soon worn away after the teeth are actively used. Next the dentine numerous clefts exist for a short distance between the enamel prisms; they communicate with the interglobular spaces and thus indirectly with the dentinal tubules.

The **cementum,** or **crusta petrosa,** invests the fang of the tooth and closely resembles in structure ordinary bone; the lamellæ extend parallel to the dentine, as do likewise the long axes of the bone lacunæ. Where the cementum reaches a considerable thickness, as at the apex of the root of the tooth, Haversian canals may exist, although usually these are wanting; perforating fibres of Sharpey are also present in small numbers. The **lacunæ** communicate with the dentinal tubules, while the protoplasmic processes of their contained bone-cells may come in contact with the filaments of the odontoblasts lying within the dentinal tubules.

FIG. 177.

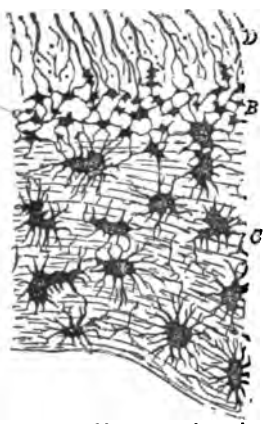

Section of human tooth at the junction of the dentine and the cementum: *D*, dentine with its tubules, which communicate with interglobular spaces (*B*) and with lacunæ of cementum (*C*).

The **pulp** consists of a matrix of soft embryonal connective tissue, in which numerous stellate and spindle cells form protoplasmic net-works by their anastomosing processes. At the periphery the connective-tissue elements are arranged as layers of elongated cylindrical cells perpendicular to the inner surface of the dentine, in contact with which they lie; these cells are the **odontoblasts,** being the representatives of the cells which were actively engaged in producing the dentinal matrix. The protoplasm of many of these cells is prolonged peripherally as delicate threads into the dentinal tubules, the processes becoming modified to form the stiff elastic **dentinal fibres**; centrally, the odontoblasts frequently are connected with the stellate connective-tissue cells.

The pulp is richly supplied with blood-vessels and nerves. The **arteries** run in the long axis of the tooth, breaking up into capillary net-works which are closest in the periphery. The **nerves** accom-

pany the larger blood-vessels as medullated fibres; these give off filaments which pass to the layers of odontoblasts, among which they extend as pale fibres. The ultimate distribution of these latter is still unsettled; the assertion that fine fibrillæ accompany the dentinal fibres into the tubules lacks confirmation.

FIG. 178.

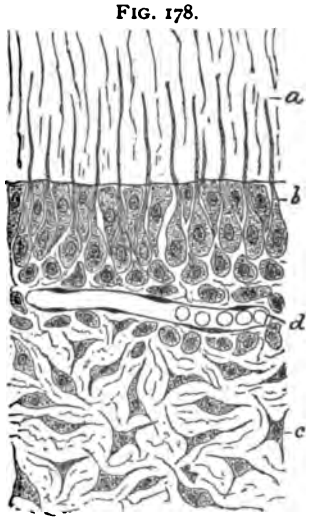

Section of young tooth of child, showing peripheral portion of pulp and adjoining dentine: *b*, pulp-cells, some of which send processes (*a*) within dentinal tubules; *c*, stroma of delicate connective tissue; *d*, blood-vessels.

Distinct **lymphatic vessels** have not been demonstrated within the pulp, although the clefts within the matrix between the connective-tissue fibres represent the lymph-spaces and are in close relation with the adjacent lymphatic channels.

DEVELOPMENT OF THE TEETH.

The teeth of man and the higher animals are really exaggerated papillæ, the peripheral parts of which have become specialized and have undergone calcification. The ectoderm contributes the enamel, while the dentine, cementum, and pulp are derived from the mesoderm.

A **linear thickening** of the primitive oral epithelium marks the earliest indication of the formation of the teeth; in man this band appears before the end of the sixth week (Röse), and is adherent to the under surface of the epithelial layer. Following the expansion of this ectodermic thickening a continuous lateral projection, the **dental ridge**, grows obliquely into the mesodermic tissue. The dental ridge continues to grow backward towards the mandibular articulation, forming an unbroken arch of ectodermic tissue connected with the under side of the oral epithelium. The line of this attachment is later marked on the oral surface by a longitudinal furrow, the **dental groove**, which has been long known, and which was formerly regarded as the initial step in the dental development.

FIG. 179.

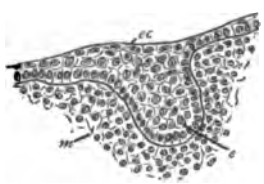

Section of jaw of rabbit embryo, showing thickening of ectodermic epithelium (*ec*) from which dental ridge (*e*) begins its growth into mesoderm (*m*).

While the dental ridge constitutes a shelf-like common epithelial invagination, the position and further development of the individual teeth are marked by **local thickenings** along the under surface of

the ridge. These secondary **dental bulbs** are the first indications of the enamel organs of the temporary teeth. After the establish-

FIG. 180.

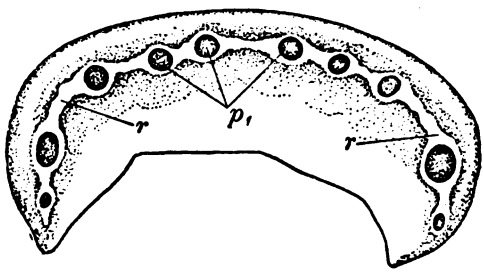

Model of jaw of human embryo of 40 mm.: *r*, *r*, arch of increased epithelium constituting dental ridge; *p*, local thickenings corresponding to positions of future enamel sacs. (After *Röse*.)

FIG. 181.

Section of jaw of rabbit embryo, showing dental ridge cut across: *ec*, oral ectoderm; *e*, epithelial outgrowth corresponding to future enamel organ; *m*, mesodermic tissue.

ment of these structures the ectodermic tissue composing the dental ridge atrophies and eventually disappears in the intervals between the individual teeth. The **enamel sacs** of the permanent teeth are formed at a later date from the remains of the dental ridge, those for the three permanent molars being derived from a special extension of the dental ridge which grows independently of ectodermic attachments.

FIG. 182.

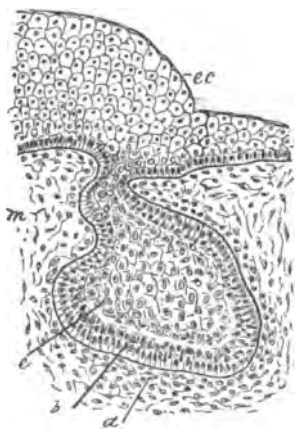

Section of jaw of rabbit embryo, showing later stage of enamel organ, which now exhibits differentiation into outer (*b*) and inner (*e*) cells: *m*, mesodermic tissue which at *a* has undergone already some condensation; *ec*, oral ectoderm.

The primitive **enamel organ** which grows from the dental ridge at first consists of a solid cylindrical process of epithelial tissue; soon, however, the extremity becomes club-shaped and slightly tortuous, and later distinctly expanded and flask-shaped. Coincident with these changes the surrounding **mesoderm** begins to exhibit proliferation and condensation of its elements, this differentiation marking the earliest stage in the formation of the important mesodermic **dental papilla**, which very soon becomes a conical mass of closely-aggregated mesodermic elements.

Along with the growth of the latter the now expanded end of the ectodermic plug becomes indented

or invaginated to form an epithelial cap, which embraces the mesodermic dental papilla, and, from its future important function, is known as the **enamel organ.** The enamel organ, however, subserves another important purpose, since its inner and outer layers grow towards the base of the dentinal papilla and invest the young mesodermic tissue with a two-layered envelope, the **epithelial sheath.** This structure plays an important *rôle* in determining the form of the future tooth, since the young dentine is deposited along its inner surface. Vestiges of this sheath appear as isolated epithelial nests. The enamel organ itself undergoes a differentiation into **three distinct layers:** the outer layer, directly continuous for a long time with the ectodermic cells of the oral cavity, is composed of one or two layers of low columnar or polyhedral cells; at the point where they are reflected to form the inner, invaginated part of the original epithelial sac, the cells become elongated and

FIG. 183.

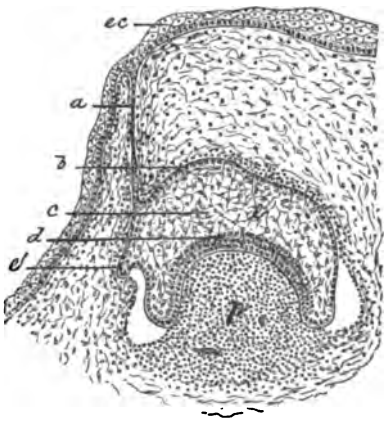

Section of jaw of cat embryo; the dental papilla is seen as a projecting conical mass (*p*) of condensed mesoderm, whose summit is enveloped by the invaginated enamel organ (*e*); *ec*, oral epithelium, still attached by the atrophic isthmus (*a*) with the enamel organ, whose outer (*b*), middle (*c*), and inner (*d*) layers are differentiated; *e'*, beginning of enamel organ for permanent tooth.

FIG. 184.

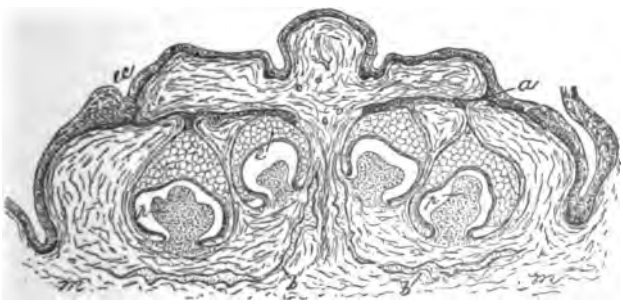

Section of jaw of cat embryo with four developing teeth slightly farther advanced than in the preceding stage: *ec*, oral epithelium; *a*, dental groove; *e*, enamel organ; *p*, *p*, dental papillæ; *m*, mesodermic tissue; *b*, *b*, bone.

distinctly columnar, constituting the inner layer of the enamel organ containing the beautiful **enamel cells.** The outer and inner layers

of the enamel organ are separated at first by the narrow zone of epithelial elements of the middle layer; the cells of the latter soon undergo characteristic changes, owing to an accumulation of fluid, resulting in the complete transformation of the cells, which become pressed together and reduced to thin plates, the tissue appearing as if composed of irregularly anastomosing connective-tissue fibres rather than of epithelial elements. The enamel organ retains for a considerable time its connection with the epithelium of the oral cavity, a thin atrophic cord of cells indicating the position of the former robust stalk. At the side of this attachment a lateral cylindrical projection early marks the beginning of the development of the **second enamel organ** for the permanent tooth.

FIG. 185.

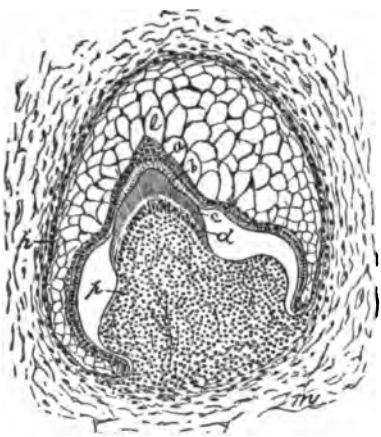

Section of developing tooth from cat embryo: *m*, mesodermic tissue condensed in dental papilla (*p*), at whose summit osteoblasts (*d*) are forming young dentine (*c*); inner layer (*a*) of enamel organ is engaged in producing layer of young enamel (*b*); *e*, middle, *h*, outer layer of enamel organ.

The columnar cells of the inner layer, the **adamantoblasts**, alone produce the enamel. This process consists essentially of a gradual deposition on the inner side of the enamel cells—that is, next the new dentine—of homogeneous prisms arranged vertically to the surface of the inner layer of the enamel organ. The layer of enamel increases by the addition of increments deposited from within out, the latest-formed enamel always lying immediately internal to the inner layer of the enamel organ. During the later stages the inner and outer layers are approximated at the expense of the intervening middle layer, which finally becomes reduced to an attenuated stratum. Subsequent deposition of lime-salts imparts to the enamel its remarkable hardness.

During the changes described in the enamel organ the central **dental papilla** is actively engaged in producing the dentine. The top and sides of the papilla are covered by a layer of elongated, columnar or pyriform connective-tissue cells, the **odontoblasts**, which are the immediate agents in causing the deposition of the dentinal matrix, the formative process being similar to that producing bone. The dentine is first formed at the apex of the papilla, and appears as a thin lamina of homogeneous matrix into which the delicate processes of the odontoblasts extend, becoming the **dentinal**

fibres; the canals left within the matrix to maintain the nutrition of the tissue constitute the **dentinal tubules**, the homologues of the lacunæ and canaliculi of bone. With the continued growth the sides of the papilla as well as the apex become covered by the layer of newly-formed dentine; the central part of the dental papilla remains, after all the dentine has been formed, as the **pulp-tissue**, into which the blood-vessels and nerves grow at a later period.

FIG. 186.

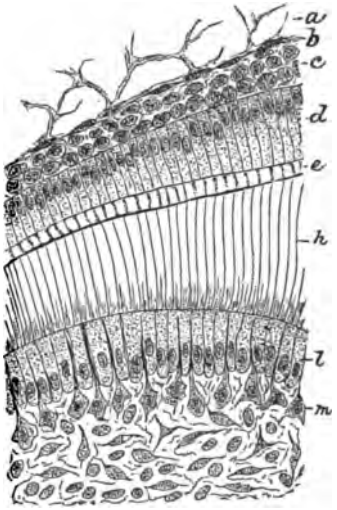

Section of developing tooth from cat embryo, portion of preceding figure more highly magnified: *m*, mesodermic elements constituting pulp-tissue; *l*, layer of odontoblasts engaged in producing dentine (*h*); *a* and *b*, cells of middle layer, *c* and *d*, cells of inner layer of enamel organ; *e*, zone of young enamel.

At first the newly-formed dentine is soft, the impregnation with lime-salts occurring subsequently; the layer of the soft, most recently formed matrix is readily distinguished in stained sections from the older calcified tissue. The **cementum**, wanting during fœtal life, is produced by the alveolar periosteum.

THE TONGUE.

The bulk of the tongue is composed of variously-disposed bundles of striated fibres of the lingualis, together with those of the accessory muscles, over the unattached surfaces of which the oral mucous membrane is reflected. The **muscular tissue** of the organ is arranged in bundles extending in three planes: (1) *vertically and slightly radially* (genio-hyoglossus, vertical fibres of lingualis and hyoglossus); (2) *transversely* (transverse fibres of lingualis); (3) *longitudinally* (lingualis superior and inferior, and styloglossus). A vertical median partition, the **septum lingualæ**, divides the muscular tissue into two halves; the inter-fascicular spaces are filled by delicate connective tissue and fat, in which lie embedded numerous small **lingual glands**. Many of the muscle-fibres find insertion in the deeper layer of the mucosa, into which their sarcolemma fades. Branched striped muscle-fibres are of common occurrence in the tongue.

The **mucous membrane** forms the most conspicuous part of the organ. That covering the sides and inferior surfaces of the tongue is thin, containing small papillæ and numerous mucous glands: on reaching the superior surface the mucous membrane greatly increases in thickness, and presents additional conspicuous irregularities, the

papillæ. The **papillæ** are of three kinds: the **filiform** or the **fungiform**, and the **circumvallate.**

The **conical papillæ** are widely distributed, occurring on of the upper surface tongue. They consi conical or cylindrical of the connective tissu mucosa, .5–2.5 mm. ir covered with a thick epithelium, the cells c as the most exposed pa papillæ, are partially by abrasion, the remai thelium presenting a ra face.

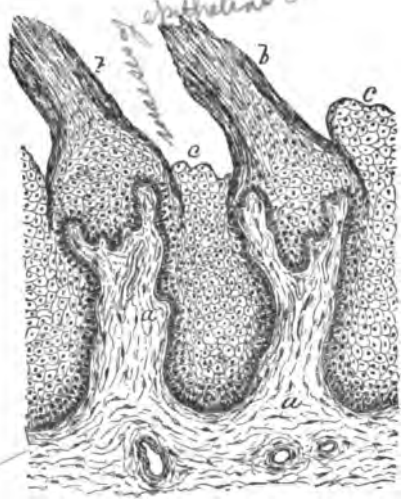

FIG. 187.

Section of human tongue showing conical papillæ: *a*, connective tissue of mucosa, which forms core of papillæ; *b*, *b*, partially abraded epithelium; *c*, masses of epithelial cells filling interpapillary recesses.

The **fungiform pap** likewise found on all the tongue, but they a in number, lower, and than the conical, appe isolated but distinct re The connective-tissue these papillæ are comp dense felt-work of fibro and bear secondary pa their upper surface, the epithelium completely enveloping t connective-tissue core.

The **circumvallate papillæ,** usually eight to ten in nur placed in two rows forn at the posterior part of th of the tongue. Each cc a large flattened fungifor surrounded by a deep fu a secondary encircling wall—an arrangement w suggested the name. T surface of the mucosa with minute secondary el which, however, are not on the free surface, bein by the thick stratum of epithelium.

FIG. 188.

Section of tongue of child, showing a fungiform papilla; the connective-tissue stroma is covered by the epithelium.

Lying altogether within the epithelium lining the sides of circular furrow, the **taste-buds** appear as inconspicuous ov

occupying almost the entire thickness of the epithelium. Additional taste-buds are found in the folds in the vicinity of the circumvallate papillæ, as likewise on some fungiform papillæ. At the sides of the

FIG. 189.

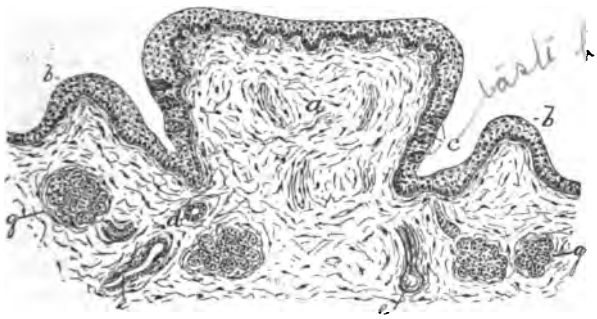

Section of circumvallate papilla from tongue of child: *a*, main central elevation, surrounded by the annular ridge (*b*) and the intervening deep furrow; *c*, taste-buds within the epithelium; *d*, ducts of neighboring glands (*g*, *g'*); *e*, blood-vessels.

tongue, just in front of the anterior pillars of the fauces, are groups of parallel folds containing a number of taste-buds; these folds constitute the **papillæ foliatæ,** which are highly developed in some of the lower animals, as in the rabbit.

FIG. 190.

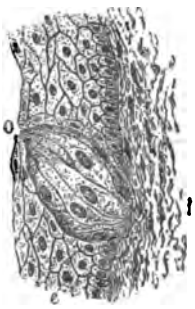

Taste-bud from circumvallate papilla of child. The oval structure is limited to the epithelium (*e*) lining the furrow, encroaching slightly upon the adjacent connective tissue (*f*); *o*, taste-pore through which the taste-cells communicate with the mucous surface.

The **taste-buds** are oval, flask-shaped bodies, embedded within the epithelium, occupying usually the entire thickness of the latter, with their long axes placed in general vertically to the free surface of the epithelium. Each taste-bud consists of an enveloping layer of greatly-elongated epithelial cells, the **cortical or tegmental cells,** which form a complete covering, except over a small area corresponding to the superficial pole of the bud; at this point a minute canal, the **taste-pore,** connects the interior of the bud with the surface of the mucous membrane.

Within the epithelial capsule lies a group of highly-specialized elements, the **gustatory cells.** These neuro-epithelial elements appear as spindle, rod-like, or forked cells, each being possessed of an oval nucleus situated about the centre of the elongated body. The peripheral or outer ends of these cells are usually provided with fine pointed extremities, some of which terminate in **stiff hair-like processes** projecting within the taste-pore almost as

far as the free surface. The inner or central ends of the gustatory cells are prolonged as slender nervous processes, which are often beset with minute swellings or varicosities. These processes end in close association, but not continuity, with the terminal axis-cylinders composing the intrabulbar ramifications of the fibres of the glossopharyngeal nerve, the nerve of the special sense of taste.

The **submucous and interfascicular tissue** of the tongue contains numerous glands, both of the mucous and of the serous type. The **mucous glands** resemble those of other parts of the oral cavity, being small racemose clusters of acini more or less filled with clear mucoid secretion. They are situated in the deeper layers of the submucous tissue, as well as between the bundles of the muscle-fibres, principally in the posterior part of the tongue, although a group of small mucous glands (Nuhn's) is found near the tip. The ducts of those at the root of the tongue are sometimes lined by ciliated epithelium.

The **serous glands** are limited to the immediate neighborhood of the circumvallate and of the foliate papillæ. The acini appear darkly granular and pour out a thin watery secretion well adapted to aid in producing gustatory impressions.

The **mucous membrane** covering the root of the tongue contains also much **adenoid tissue,** which occurs either as diffuse masses or as circumscribed irregularly spherical lymph-follicles, 1–5 mm. in diameter. The position of these follicles is frequently indicated by slight elevations of the mucosa, in the centre of which a minute pit leads into the interior of the lymphatic crypt. The epithelium lining such recesses is completely infiltrated with lymphoid cells, while the surrounding diffuse adenoid tissue contains several minute spherical masses of denser structure.

FIG. 191.

Salivary corpuscles from human saliva: *x*, group of corpuscles near epithelial cells; *y*, corpuscle which has burst, allowing granules to escape; *z*, salivary corpuscle highly magnified, showing granules and nucleus.

Among the formed elements observed in the saliva the so-called **salivary corpuscles** are conspicuous. These are spherical bodies, somewhat larger than the leucocytes, and possess a distinct nucleus and minute granules within the cell-contents; under high amplification these granules exhibit the agitation characteristic of the molecular or Brownian motion. The salivary corpuscles are derived from the adenoid tissue of the mouth, and are really escaped lymphoid cells, which, in consequence of the action of the saliva, become swollen by the imbibition of a fluid less dense than the tissue-juices; they thereupon exhibit a reaction similar to that seen when the colorless blood-cell is treated with water.

The **blood-supply** of the tongue is very rich, the vessels forming a superficial net-work in the mucosa, from which minute twigs ascend within the papillæ to terminate at the summit in close capillary plexuses.

The acini of the various glands are surrounded by capillaries, as are also the lymph-follicles through the adenoid tissue of which many minute vessels extend. The capillary net-works supplying the muscular tissue follow the general arrangement and direction of the muscular fibres, surrounding the latter by the characteristic rectangular-meshed net-works.

The **lymphatics** of the tongue are numerous; they are arranged as a superficial plexus within the submucous tissue, which receives the lymphatics from the bases of the papillæ; the latter vessels, in turn, take up the smaller trunks having their origin in the numerous interfascicular lymph-spaces within the central papillary connective tissue. The lymph-follicles at the root of the tongue are well provided with lymphatics, which surround the follicles and give off radicles to the adenoid tissue.

FIG. 192.

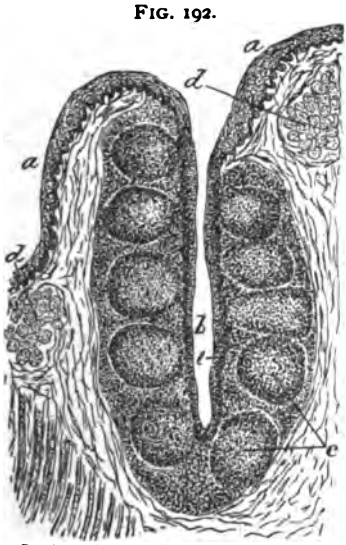

Section of tonsil of dog: *a*, epithelium of mucous membrane passing into central recess (*b*), where it becomes infiltrated with lymphoid cells (*e*); *c*, lymph-nodules embedded within diffuse adenoid tissue; *d*, neighboring mucous glands.

FIG. 193.

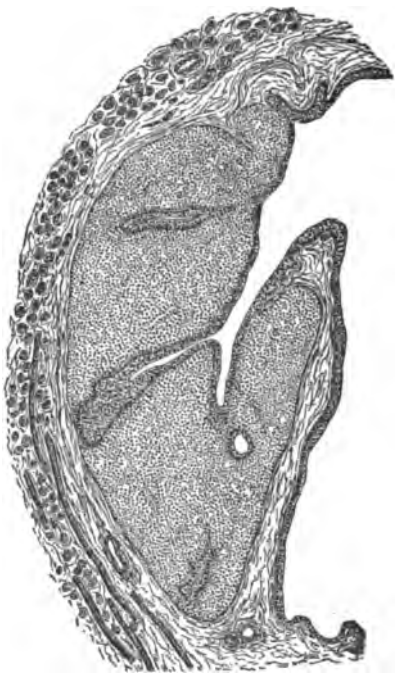

Section of tonsil of child; the epithelium of adjacent surface passes into the deep pits which extend into the adenoid tissue.

The **nerves** supplying the mucous membrane—the glosso-pharyngeal and the lingual branch of the trifacial—end either beneath the epithelium in the usual manner, or in close relation with the organs of special sense—the taste-buds. Numerous microscopic ganglia also occur along their course, especially in connection with the fibres of the glosso-pharyngeal nerve.

THE TONSILS.

The **tonsils** represent compound lymphatic glands, while considerable variation exists as to form and size, each organ consisting of an aggregation of from ten to eighteen **lymph-follicles,** closely resembling those found at the root of the tongue embedded within the surrounding **diffuse adenoid tissue.** The entire mass is separated from the adjacent structures on the attached borders by a fibrous **capsule,** and is covered with a reflection of the oral epithelium on the mucous surface, including the deep central pit on which the lymph-follicles abut. The **epithelium** covering the folds and depressions of these surfaces is completely infiltrated with lymphoid cells, so that the demarcation between the epithelium and the subjacent adenoid tissue is often obscure.

FIG. 194.

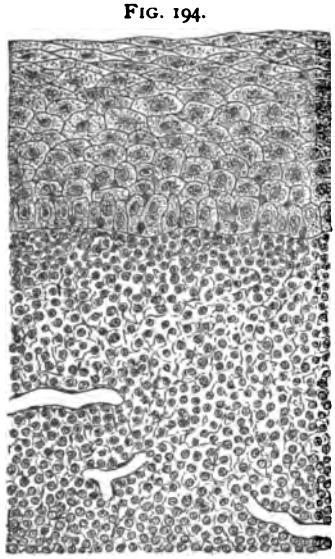

Section of child's tonsil, showing the details of the epithelium and part of the lymphoid tissue from preceding figure under higher amplification.

Numerous **mucous glands** occupy the immediate vicinity of the tonsils, into the crypts of which the glands pour their secretion to mingle with the shed epithelium and lymphoid cells occupying the recesses. Great numbers of the **escaped lymphoid cells** pass into the oral cavity to become salivary corpuscles, of which the tonsils are a most important source.

Blood-vessels and **lymphatics** occur in large numbers within the adenoid tissue; venous and lymphatic plexuses surround the organ receiving the radicles issuing from the interior. Lymph channels encircle the individual follicles, and afterwards communicate with the larger peripheral vessels.

Regarding the ultimate distribution of the **nerves** little is definitely known; fibres have been traced into the subepithelial plexus.

THE PHARYNX.

The pharynx consists essentially of a fibrous tunic, within which lies the mucous membrane with the submucous tissue, while without are arranged the fibres of the constrictor and other muscles; **three** coats, the **mucous**, the **fibrous**, and the **muscular**, are recognized, therefore, as forming its walls. The histological differences distinguishing the upper, or respiratory, from the lower, or digestive, portion of the sac depend largely upon variations within the mucosa, especially as to the character of the epithelium.

The upper, **respiratory division** of the pharynx is clothed with stratified ciliated columnar epithelium containing numerous goblet-cells, while the part situated below the level of the soft palate is covered with stratified squamous cells similar to those lining the oral cavity. The **tunica propria**, or stroma of the mucosa, is formed of a felt-work of fibrous bundles, together with a variable, in certain parts large, quantity of elastic tissue. The subepithelial surface of the mucosa, where covered by the squamous cells, is beset with numerous small **papillæ**; these, however, are wanting beneath the ciliated epithelium.

Small mucous **pharyngeal glands** occur in many places; they are especially numerous in the deepest layers of the mucosa in the immediate vicinity of the orifices of the Eustachian tubes, occurring less frequently towards the lower part of the pharynx. The mucous membrane contains a considerable quantity of **adenoid tissue** arranged as numerous lymph-follicles in the upper part of the cavity; these follicles closely resemble those found at the root of the tongue, existing isolated or in groups. A conspicuous aggregation of such structures lies on the posterior wall of the pharynx between the openings of the Eustachian tubes, constituting the **pharyngeal tonsil**, appropriately so named in view of the similarity of its structure to that of the faucial organs of like name. Some of the mucous glands here also open into the central crypt.

The **submucous tissue** unites the mucous membrane with the fibrous coat, whose dense felt-work of fibro-elastic bundles forms a structure frequently termed the pharyngeal aponeurosis. Its posterior part is greatly thickened and forms the **raphé** to which the constrictor muscles are attached.

The muscular coat is formed of the striped fibres constituting the constrictor and other muscles, with whose general arrangement the disposition of the muscular tissue agrees.

External to the muscular coat an irregular investment of **areolar tissue** attaches the pharynx to the surrounding structures.

The larger **blood-vessels**, **lymphatics**, and **nerve-trunks** take

their course within the submucous tissue, and send off branches to supply the mucosa in a similar manner as in the mouth. The **lymphatics** are exceptionally numerous in the vicinity of the lymph-follicles, around which they form net-works continuous with those of the nasal cavity, the œsophagus, and the larynx.

The **nerves** supplying the pharynx, derived from the cranial and sympathetic trunks taking part in the formation of the pharyngeal plexus, contain both medullated and non-medullated fibres, associated with minute ganglia. Small twigs are given off from the larger branches to terminate in the subepithelial tissue and among the acini of the mucous glands and the lymphatic follicles.

The walls of the digestive tract, from the œsophagus to the anus, are composed of four tunics—the **mucous**, the **submucous**, the **muscular**, and the **fibrous** or **serous**. The **muscular** coat, usually thickest and most rigid, is the most essential structure in **maintaining the form** of the tube. The **mucosa** is distinguished by the highly-specialized **secreting apparatus** which it contains, as well as by the **variations** and the **modifications of its surface**; the difference between the several divisions of the digestive tract is dependent largely upon the changes in the character of this tunic.

The **submucosa** loosely connects the mucous coat with the muscular, and affords space for the larger blood-vessels, the lymphatics, and the nerves, as well as for some few glandular structures and lymphoid masses.

The **fibrous** coat gives additional strength to the walls of the digestive tube, and presents a smooth external serous surface in those parts of the tract which receive a reflection from the peritoneum.

THE ŒSOPHAGUS.

The walls of the œsophagus comprise four coats—the **mucous**, the **submucous**, the **muscular**, and the **fibrous**.

The **mucous membrane** is a continuation of that of the pharynx, and corresponds closely with the latter in structure.

The **stratified squamous epithelium** rests upon the connective-tissue matrix, the tunica propria, the inner surface of which bears numerous small **papillæ** completely hidden by the thick overlying epithelium. The deeper layers of the mucosa are separated from the submucous coat by longitudinal bundles of involuntary muscle, the **muscularis mucosæ**; these muscular bundles, absent in the upper part of the œsophagus, first appear as irregular and interrupted groups, which become more numerous until, from the middle of the tube on, they form a continuous longitudinally-disposed layer.

The **submucous coat** is composed of loosely-united connective tissue, serving for the conveyance and support of the larger blood-

vessels, lymphatics, and nerves. Within the submucosa are placed likewise the acini of the **mucous glands**; these are rather more numerous on the anterior surface, their ducts piercing the mucosa and opening on the free surface of the mucous membrane, being lined throughout the greater part of their length by columnar epithelium. In the lower portion of the œsophagus, particularly about

FIG. 195.

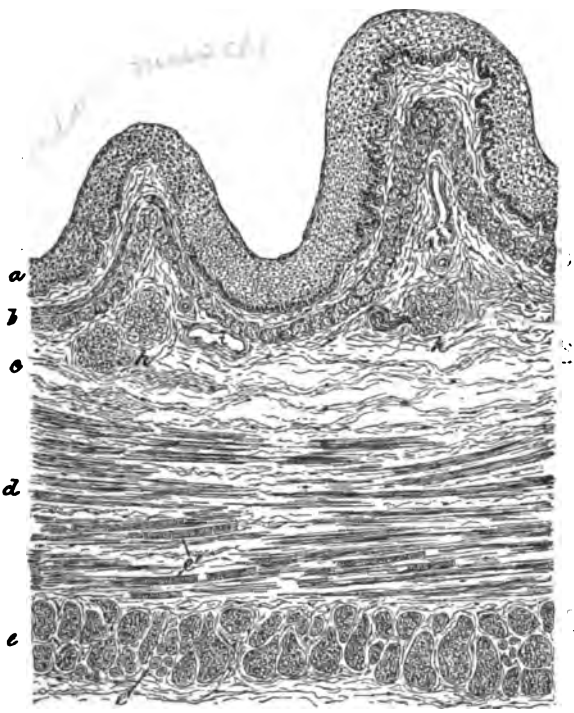

Section of human œsophagus: *a*, squamous epithelium of surface resting upon fibrous tissue of mucosa, the deeper part of which is occupied by muscularis mucosæ (*b*); *c*, submucous coat, containing glands (*h*); *d*, *e*, respectively circular and longitudinal muscular tunics; *e'*, *e'*, bundles of striped muscle-fibres.

the cardiac orifice, the mucous glands are very plentiful and lie within the mucosa.

The **muscular tunic** consists of two layers, an inner **circular** and an outer **longitudinal**, whose component bundles are held together by the connective-tissue septa which pass between the fasciculi in all directions. The character of the muscular tissue varies in the several portions of the tube. That contained within the wall of the **upper third** of the œsophagus is entirely of the **striated** variety, while the muscular tissue of the **lower third** is exclusively

non-striped or involuntary in character; in the **middle third both kinds exist,** the striated fibres gradually disappearing as the non-striped fibres increase. The latter extend highest in the circular coat and somewhat farther in the anterior than on the posterior wall. The last traces of voluntary muscle appear as short, isolated striped fibres among the surrounding fasciculi of non-striated tissue.

The **fibrous coat** envelops the muscular tunic externally, strengthening the tube and affording attachment to the surrounding areolar tissue connecting the œsophagus with neighboring organs. Considerable elastic tissue is found in this coat, the elastic fibres forming net-works intimately connected with the bundles of involuntary muscle.

The larger **blood-vessels** penetrate the outer coats and ramify within the submucous tissue, from which branches pass to supply the muscular and mucous tunics, the capillaries within the latter ending as net-works within the inner part of the tunica propria. The **lymphatics** of the deeper layers of the mucosa terminate in the larger vessels of the submucosa. Numerous **nerve-fibrillæ** pass from the submucous tunic into the mucosa to end beneath the epithelium.

THE STOMACH.

The stomach must be regarded as a dilated and specialized portion of the general digestive tube, its walls consisting of the **four coats** common to the other parts of the tract—namely, the **mucous,** the **submucous,** the **muscular,** and the **serous** or **fibrous** tunic.

The **mucous membrane** is covered by a **simple columnar epithelium,** the squamous cells of the œsophagus abruptly terminating at the cardiac orifice to be replaced by the columnar elements of the gastric epithelium, many of which are goblet-cells. The free inner surface of the stomach presents, in addition to the conspicuous folds or **rugæ,** minute inequalities and pits, which mark the openings of the gastric glands; the mouths of the latter show as minute **depressions,** between which the intervening portions of the mucosa extend as apparent elevations.

The **gastric glands** are of two kinds—the **peptic glands,** situated in the middle and cardiac thirds, and the **pyloric glands,** found in the pyloric third of the stomach. Both varieties are limited to the mucosa, extending in length the entire thickness of this coat.

The **peptic glands** are slightly wavy, simple tubular depressions, in which a **duct,** a **neck,** and a **fundus** are recognized. In exceptional cases the fundus is divided, while in nearly all it is tortuous or spiral, its extremity being often sharply bent at right angles to the general axis of the tube. The columnar epithelial cells of the ad-

ic mucous membrane pass into the ducts of the glands hange, becoming imbricated, and, towards the neck, more spherical in outline. At the irrowest part of the tube, the cells iboidal, and assume a columnar or rm as they approach the fundus. f or **central cells** bound the lumen

FIG. 196.

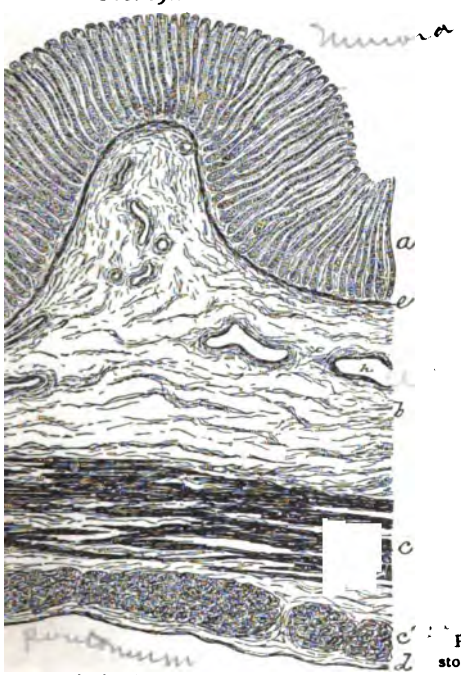

in stomach, showing general arrangement of its coats: aining the tubular peptic glands; *e*, muscularis ig the layer of glands from the underlying submucous d-vessels; *c*, *c'*, respectively the circular and longi- layers; *d*, the fibrous tunic covered with the peri-

FIG. 197.

Peptic gland from stomach of dog: *a*, wide mouth and duct which receive the terminal divisions of the gland; *b*, *c*, neck and fundus of the tubes; *e*, central or chief, *d*, parietal or acid, cells.

d and form the bulk of the glandular epithelium. Each s a spherical nucleus embedded within the granular pro- ıose exact condition depends upon the state of functional n addition to the chief or central cells, a second variety, **l or acid cells,** exists in the peptic glands. As indicated ne, the parietal cells are situated in the periphery of the diately beneath the basement-membrane, usually separated ımen by the intervening central cells. Minute lateral

intercellular clefts or canals in many places afford direct communication between the parietal cells and the lumen of the tube. The parietal cells are irregularly distributed from the fundus to the

FIG. 198.

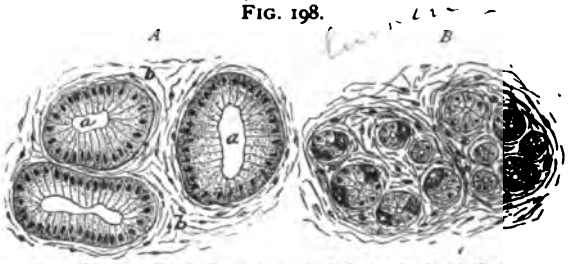

Transverse sections of peptic glands from stomach of dog: *A*, plane of section passes through ducts near free surface; *a*, lumen of glands; *b*, surrounding fibrous stroma of mucosa; *B*, plane of section passes through fundi near terminations of tubules; the sections of the latter are arranged in groups separated by connective tissue.

neck of the gland; but they are especially numerous in the vicinity of the neck. These cells are larger than those lining the lumen, polygonal or triangular in outline, and possessed of a pale, faintly granular protoplasm surrounding a round or oval nucleus. In preparations of human stomach, the parietal cells are not infrequently the most conspicuous and best defined, since the central cells are prone to disintegrate.

FIG. 199.

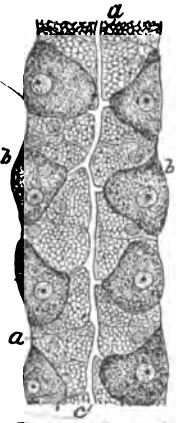

Portion of peptic gland of dog, highly magnified: *a*, *a*, the central or chief cells next the lumen (*c*); *b*, *b*, the parietal or acid cells connected with the lumen of the tube by short lateral branches which extend to the cells.

On approaching the pyloric ring, the simple tubular peptic glands are gradually replaced by the compound glands, until, near the intestinal opening, these alone are present.

The **pyloric glands** are characterized by the relatively long, wide ducts into which the several divisions of the body open; the tubular compartments are wavy and tortuous, and frequently end in slightly expanded extremities. The duct is lined by tall columnar epithelium, the cells becoming lower and broader as they approach the neck and towards the fundus. The cells contain finely granular protoplasm, and do not secrete mucus, but a thin albuminous fluid. *Parietal acid cells do not occur in the pyloric glands*, being confined to the true peptic glands.

The **gastric glands**, while very uniformly distributed through all parts of the stomach, are arranged in **groups**, the individual tubules which are separated by very delicate partitions of the connective

tissue, thicker layers of fibrous tissue enveloping the entire group. Numbers of **lymph-cells** are intermingled with the fibrous tissue of the mucosa; in the vicinity of the pylorus considerable patches of diffuse adenoid tissue lie around and among the ends of the gastric follicles and constitute the **lenticular glands.**

FIG. 200.

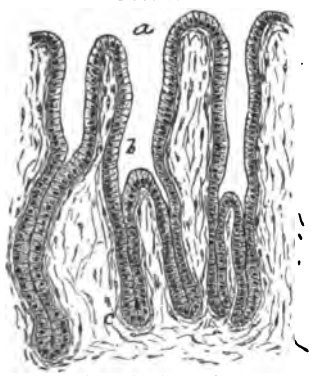

Section of pyloric glands from human stomach: *a*, mouth of gland leading into long, wide duct (*b*), into which open the terminal divisions; *c*, connective tissue of the mucosa.

—The **muscularis mucosæ** occupies the deepest layer of the

FIG. 201.

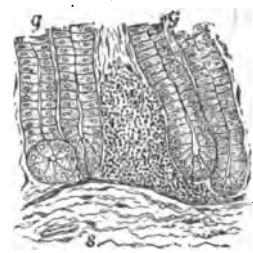

Section of pyloric region of human stomach, showing irregular mass of adenoid tissue lying between the gastric tubules (*g*, *g*) constituting a lenticular gland; *s*, submucous tissue.

tunica propria, and is composed of an inner circular and an outer longitudinal layer of non-striped muscle; the tissue of the muscu-

FIG. 202.

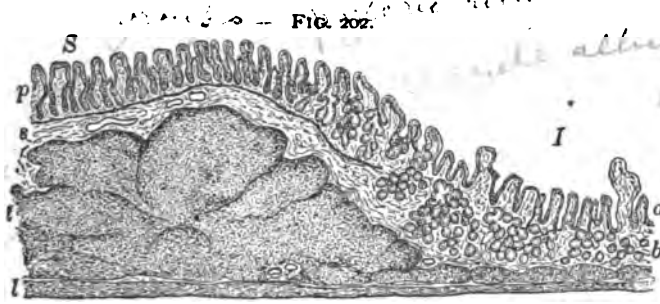

Longitudinal section of child's stomach passing through pyloric orifice: *S*, *I*, the gastric and the intestinal surface; *p*, pyloric glands, which gradually extend into the submucosa to become Brunner's glands (*b*); *a*, simple follicles of the intestinal mucosa; *s*, submucosa; *l*, the greatly thickened layer of circular muscle constituting the pyloric ring; *l*, longitudinal muscular tunic.

laris mucosæ extends within the interglandular septa, often as far as the free surface of the mucous membrane, beneath which the muscle-cells disappear.

The **submucosa** is a coat of considerable thickness, composed of a felt-work of fibro-elastic bundles of varying size, but so loosely interwoven that the mucosa may be shifted readily within con-

siderable latitude upon the underlying muscular tunic. The large prominent folds, or rugæ, of the stomach involve both the mucous and the submucous coat, the latter forming the connective-tissue frame-work of the elevation over which the mucosa with its glands is reflected. Within the mesh-work of connective-tissue bundles are supported the larger blood-vessels, lymphatics, and nerves.

The **muscular tunic** comprises two principal sheets of involuntary muscle, disposed as an inner circular and an outer longitudinal layer; towards the cardiac end of the stomach irregular bundles of oblique fibres constitute an imperfect third layer. The **pyloric orifice** is guarded by a fold of mucous membrane supported by the submucosa and strengthened by a conspicuous local annular thickening of the inner circular layer of muscle; the outer longitudinal muscular layer and the serous coat pass over into the intestinal wall without participating in the formation of this **gastro-duodenal valve.**

FIG. 203.

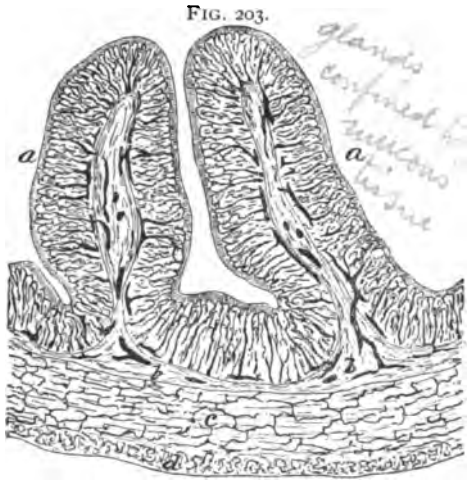

Section of injected stomach of cat: *a*, rugæ consisting of the mucosa and a core of submucous tissue (*b*); *c*, *d*, the circular and longitudinal layers of muscle; all the dark lines represent the blood-vessels filled with the carmine-gelatin mass; the larger trunks break up in the submucosa, sending twigs into the mucous and muscular tunics.

The **serous coat** is composed of bundles of fibrous connective tissue, together with rich networks of elastic fibres, while the peritoneal surface is covered with a single layer of the characteristic endothelial plates. The narrow areas included between the folds of the peritoneum along their lines of reflection are, of course, devoid of the serous covering; at these points the vessels and the nerves pass to and from the stomach.

The larger **arteries,** after penetrating the outer coats, divide within the submucosa into smaller branches, one set of which pierces the muscularis mucosæ to be distributed to the mucous membrane, while the other enters the muscular and serous tunics. The vessels supplying the mucosa form a rich **subepithelial capillary network,** as well as mesh-works surrounding the gastric glands, the capillaries lying immediately beneath the basement in close proximity to the glandular epithelium. The branches distributed to the outer

layers form long-meshed capillary net-works, from which the muscle-bundles and fibrous tissue derive their supply.

The larger **lymphatic trunks** accompany the blood-vessels and form a coarse plexus within the submucous tissue; a much closer net-work of smaller lymphatics occupies the deeper part of the mucosa, from which radicles ascend between the glands to end beneath the epithelium in slightly dilated **blind extremities.** Peripherally-situated lymph-vessels drain the masses of adenoid tissue. In addition to the lymphatics of the mucosa, the larger vessels of the submucosa take up those from the muscular coat.

The **nerves** of the stomach, after piercing the serous coat, take up a position between the circular and longitudinal muscular layers, in which situation they form a rich plexus, consisting of both medul-

FIG. 204.

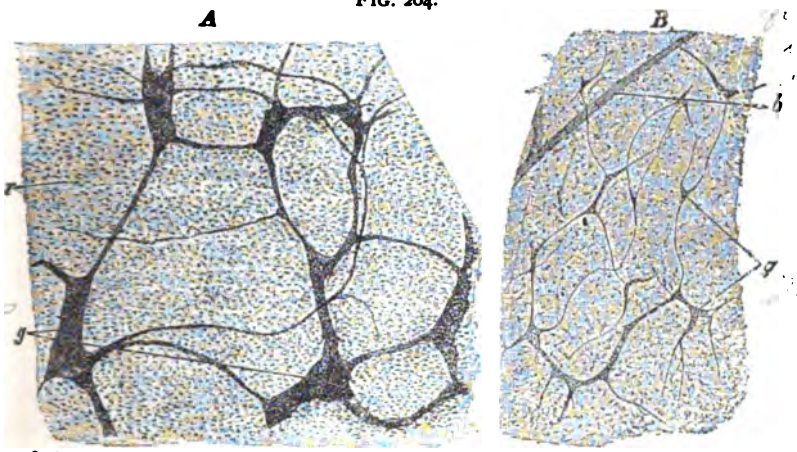

Surface views of nervous plexuses of stomach of young child. *A*, Auerbach's plexus: *g*, groups of ganglion-cells; *r*, underlying muscular tissue. *B*, Meissner's plexus: *g*, groups of ganglion-cells; *b*, blood-vessel. (After *Stöhr*.)

lated and pale fibres; at the nodal points of this net-work numerous microscopic ganglia are situated, the whole forming the intramuscular ganglionic **plexus of Auerbach.**

From this plexus fibres are distributed to the serous coat and to the longitudinal layer of muscle, as well as to the outer part of the circular layer. The intramuscular net-work is continued by numerous small bundles of fibres, which, after piercing the inner layer of circular muscle, and giving off lateral twigs to the inner part of the same, enter the submucosa to form there a second ganglionic plexus similar to the one lying between the muscular layers: this is the **plexus of Meissner.** The submucous plexus sends off numerous fibres into the mucosa, which are distributed beneath the epithelium

and to the gastric glands; the exact mode of termination of these nerve-fibrillæ within the mucosa, however, is still undetermined.

THE INTESTINES.

The four coats of the stomach are continued, with little modification, into the **mucous,** the **submucous,** the **muscular,** and the **serous** tunics of the intestinal wall; the variations characterizing the several divisions of this tube are dependent largely upon *modifications and specializations of the mucous membrane.*

The free inner surface of the small intestine is studded over with small cylindrical elevations—the **villi**—projecting into the intestinal lumen and bathed in the juices of the canal. In addition to the villi, which are found through the whole extent of the small intestine, the mucous membrane is thrown into transverse or oblique permanent folds—the **valvulæ conniventes**—which extend partially around the tube, and are most marked in the duodenum and the jejunum; these folds increase the area of the mucous surface, and are beset with villi the same as the surrounding parts of the mucosa. These projections, the villi and the valvulæ conniventes, are peculiar to the small intestine and serve to distinguish it from the large.

FIG. 205.

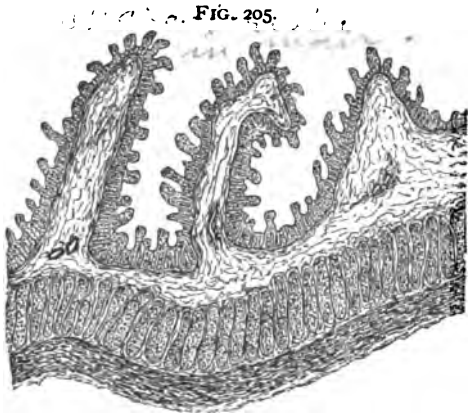

Longitudinal section of human small intestine, showing general relation of the folds constituting the valvulæ conniventes to the mucosa and submucous coat; the latter contributes the fibrous core over which the mucosa with its villi and glands extends.

The **mucosa** is covered by a single layer of columnar epithelium resting upon the basement-membrane. The prismatic cells contain finely granular protoplasm and oval nuclei, the latter being usually situated within the inner half of the cell. The outer free ends of the cells are invested by a peculiar cuticular zone, or **basilar border,** a well-defined continuous band exhibiting, in suitably preserved specimens, a fine vertical striation. The significance of these markings is still uncertain, especially in view of the fact that, after the action of such reagents as water, the border breaks up into rods resembling very coarse cilia; the striation is regarded by others as the expression of fine parallel canals.

Goblet-cells are numerous, many epithelial elements having become distended with mucoid secretion: in carmine preparations the cells appear as clear, oval breaks in the contour of the epithelium. While occurring throughout the entire digestive tube, the goblet-cells are especially numerous in the large intestine, where not infrequently the majority of the epithelial elements are in this condition. During certain stages of digestion the protoplasm of the epithelium may contain oil-drops taken up from the intestinal contents. **Migratory leucocytes** are also found in the intercellular clefts. The epithelium rests upon a membrana propria—the *endothelium of Debove*—composed of flattened connective-tissue plates.

FIG. 206.

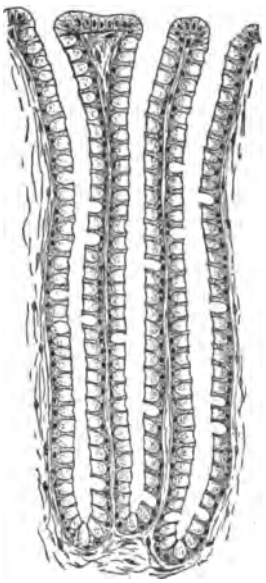

Simple tubular glands of large intestine of dog: the epithelial elements lining the follicles have become very largely converted into goblet-cells.

The **villi** consist entirely of the tissues of the mucosa, the epithelium extending over the projecting portions of the tunica propria to form a complete investment of the finger-like processes. The centre of each villus is occupied by the absorbent **chyle-vessel**, or **lacteal**, a slightly club-shaped lymphatic radicle, which ends blindly near the apex of the villus and whose walls are composed of a single layer of endothelium. The tissue surrounding the lacteal and forming the bulk of the projection approaches in character quite closely **adenoid tissue**, consisting of a fibrous reticulum holding many lymphoid cells within its meshes. The central lacteal lies enclosed within a **capillary net-work**, extending through the greater part of the villus and connecting the afferent arteriole and efferent veins. Immediately surrounding the lacteal, and in intimate relation with it, numerous delicate vertical bundles of non-striped muscle, derived from the underlying muscularis mucosæ, ascend towards the tip of the villus.

FIG. 207.

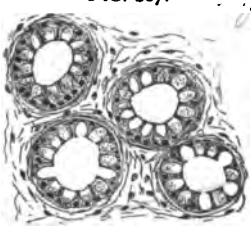

Transverse section of follicles of large intestine of dog: the individual tubules are separated by the fibrous stroma of the mucosa.

The components of the villus are held together by the common adenoid tissue, in whose interstices lie many **lymphoid cells** and, during certain stages of digestion, numberless **fatty granules**. At

such times the contents of the lacteals appear milky, in
of the emulsion formed
sorbed oil; during the
digestive inactivity the
tains the clear, straw-c
usually found within lyn
sels. The villi disappe
at the ileo-cæcal valve
present in the large intes

Among the structures
testinal wall usually i
"glands" two distinct g

FIG. 208.

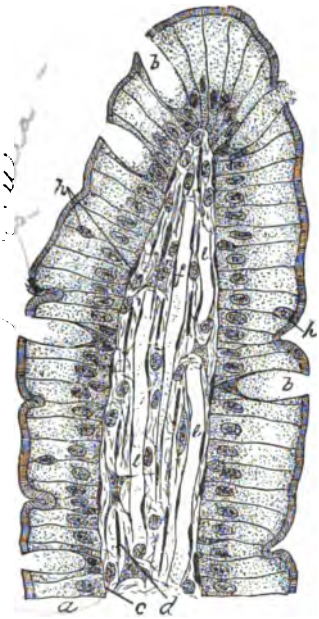

Longitudinal section of villus from intestine of dog, highly magnified: *a*, columnar epithelium containing goblet-cells (*b*) and migratory leucocytes (*k*); *c*, basement membrane; *d*, plate-like connective-tissue elements of core; *e*, *e*, blood-vessels; *f*, absorbent radicle or lacteal.

FIG. 209.

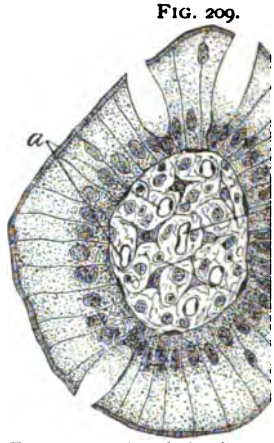

Transverse section of villus from in
a, *a*, blood-vessels; *b*, la

be recognized—the true and the false glands, the latter l
or compound lymph-follicles. These structures therefo
the appropriate headings:

Intestinal True-Glands.	**Intestinal Lymph-**
Glands of Lieberkühn.	*Solitary gland*
Glands of Brunner.	*Agminated gl*

The **follicles, crypts,** or **glands of Lieberkühn** a
merous, forming an almost continuous layer of simple
pressions throughout the intestines, large as well as sı
occupy nearly the whole depth of the mucosa, their wavy
approaching the muscularis mucosæ. The columnar ep
the free surface passes directly into the tubules to become t
secreting cells, many of which undergo mucoid dis

conversion into goblet-cells. Lieberkühn's glands lie between the bases of the villi, but are found upon the valvulæ conniventes, since the latter depend on the elevation of the submucosa for their formation, the mucosa being reflected over the projecting underlying tunic. In the lower part of the large intestine the glands of Lieberkühn increase in size, becoming longer and possessing wider mouths, their orifices appearing as minute pits.

FIG. 210.

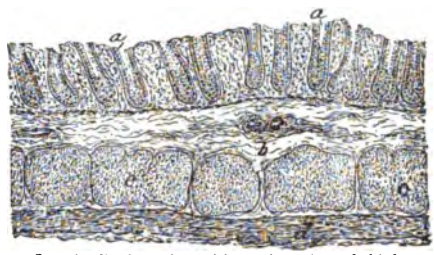

Longitudinal section of large intestine of child: *a*, *a*, simple tubular glands; *b*, submucous tissue; *c* and *d*, circular and longitudinal layers of muscle.

The duodenum, especially in its upper part, possesses an additional layer of true secreting structures in the **glands of Brunner.** These are the direct continuations and higher specializations of the pyloric glands of the stomach. In passing from the stomach into the intestine these tubules undergo repeated division, and, at the same time, sink deeper and deeper into the mucosa, finally reaching below the limits of this layer to take up *a position within the submucosa* of the duodenum, beneath the overlying layer of the follicles of Lieberkühn within the mucosa.

FIG. 211.

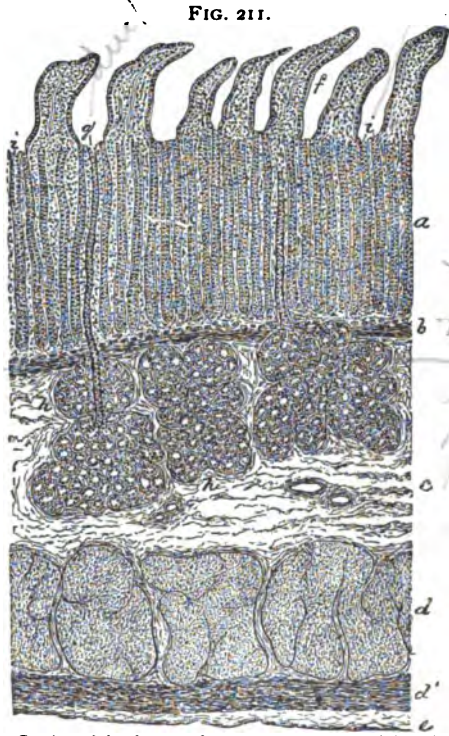

Section of duodenum of cat: *a*, mucosa containing the villi (*f*) and the follicles of Lieberkühn (*i*), and pierced by the ducts (*g*) of the glands of Brunner (*k*) within the submucosa (*c*); *b*, muscularis mucosæ; *d*, *d'*, circular and longitudinal layers of muscle; *e*, fibrous tunic.

Brunner's glands, or **the duodenal glands,** appear as groups of short, wide, tubular acini, disposed about long, slender ducts which pass from the submucous tissue through the mucosa to open on the intestinal surface between

or by means of the orifices of the follicles between the bases of the surrounding villi. The glands, owing to the rapid branching of their tubules, more closely approach the racemose type than the compound tubular to which they really belong, as shown in their direct derivation from the compound tubular pyloric crypts. The secretion of these duodenal glands is mucous and not serous, as shown by the investigations of Bensley.

FIG. 212.

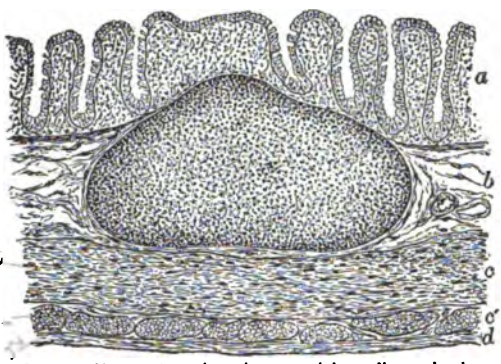

Section of human large intestine, containing solitary gland: *a*, mucosa; *b*, submucosa; *c*, *c'*, circular and longitudinal layers of muscle; *d*, serous coat.

The **solitary glands** are isolated lymph-follicles scattered through the entire intestine; they are, however, most abundant in the lower part of the ileum and in the first portions of the large intestine. They are situated primarily within the mucosa, although they frequently lie also within the submucous coat; when well

FIG. 213.

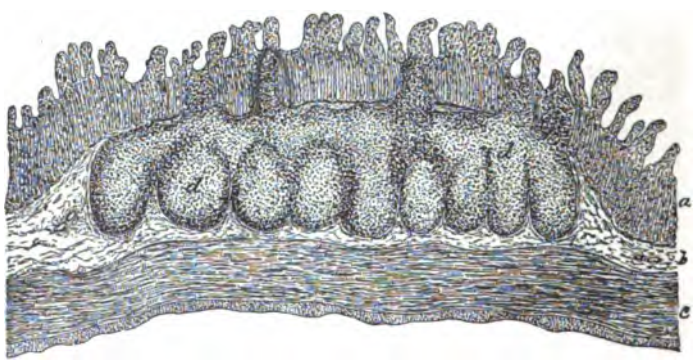

Section of small intestine of cat, showing a Peyer's patch (*d*, *d*) cut crosswise: *a*, *b*, *c*, respectively mucous, submucous, and muscular coats.

developed, they encroach upon the mucosa to such an extent that their inner pole slightly projects upon the free surface of the intestine. The **lymphoid tissue** is somewhat denser in the periphery of the follicle, beneath its limiting capsule, than towards the centre; but the

lymphoid cells are everywhere so closely packed that the supporting reticulum of connective tissue is masked. In the upper part of the duodenum numerous ill-defined masses of adenoid tissue occupy the mucosa between the follicles and represent the lenticular glands of the stomach.

The **agminated glands**, or **Peyer's patches**, are large, oval groups of closely aggregated lymph-follicles, held and blended together by diffuse adenoid tissue. These patches vary in size and number, and are usually limited to the lower two-thirds of the small intestine, reaching their highest development in the ileum, where they may attain a length of 9–11 cm.; between twenty and thirty patches generally are present, while they are relatively better developed in young than in old subjects.

The agminated glands appear first within the mucosa, but later encroach largely upon the submucous tissue. The lymph-follicles of which these patches are composed become somewhat pyramidal, owing to pressure, and lose much of their individuality, the demarcation into separate follicles being best preserved along the outer

FIG. 214.

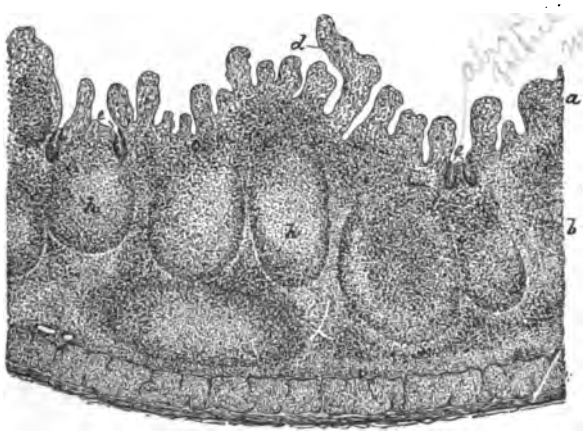

Section of small intestine of child, including a portion of a Peyer's patch: *a*, *b*, and *c*, mucosa, submucosa, and muscular coats; *d*, villi; *e*, *e*, atrophic follicles of the mucosa.

boundary, occupying the submucosa, within the mucosa the outlines of the follicles being lost in the general adenoid mass. Where the summits of the follicles impinge against the inner layer of the mucosa, the positions of the follicles are indicated by corresponding elevations of the mucous surface, at which points the villi are frequently pushed aside and the gland-layer more or less completely interrupted. In the **vermiform appendix** of some animals, and

in some cases also in man, the follicles form almost a continuous zone of adenoid tissue.

The **muscularis mucosæ**, like that of the stomach, occupies the deepest part of the mucosa and marks the outer boundary of the mucous layer. The muscular tissue comprises longitudinally-disposed bundles of muscle-cells, supplemented in some places by a more or less complete additional internal layer of circularly-placed cells.

The **submucosa** of the intestinal wall corresponds to the similar coat of the stomach, consisting of loosely-united bundles of fibro-elastic tissue, which support the larger vascular and lymphatic trunks, as well as a rich nervous plexus.

FIG. 215.

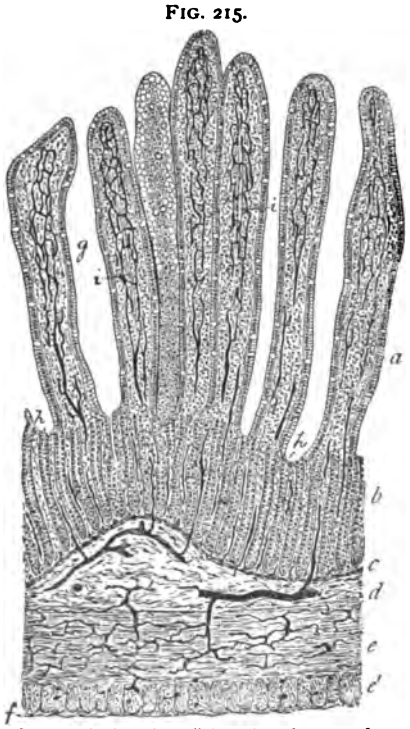

Section of injected small intestine of cat: *a*, *b*, mucosa; *g*, villi; *i*, their absorbent vessels; *h*, simple follicles; *c*, muscularis mucosæ; *d*, submucosa; *e*, *e'*, circular and longitudinal layers of muscle; *f*, fibrous coat. All the dark lines represent blood-vessels filled with the injection mass.

The **muscular coat** consists of two well-developed layers—the thicker **inner circular** and the less robust **outer longitudinal** stratum. These are separated by a thin layer of connective tissue, which externally becomes continuous with the enveloping areolar tissue and passes into the outer fibrous tunic of the serosa.

In parts of the large intestine—as the cæcum and the colon—the circular muscular coat is relatively thin, while the longitudinal layer is incomplete, the fibres of the latter being collected into **three flat bands**, 10–15 mm. wide; these longitudinal bands are much shorter than the other layers of the intestinal wall, which arrangement results in the characteristic **sacculation** of the large intestine. In the lower part of the rectum the circular muscular layer becomes thickened to form the **internal anal sphincter**, composed of involuntary muscle; the bands of longitudinal fibres spread out, and towards the lower end of the rectum form a thick, uniform layer.

The **blood-vessels** supplying the intestines follow the general arrangement of those of the stomach. The larger vessels pierce the serous and muscular coats, giving off slender twigs to supply the tissues of these tunics; upon reaching the submucosa the vessels form a wide-meshed net-work. Numerous branches then pass through the muscularis mucosæ to be distributed to the deeper as well as to the more superficial parts of the mucosa; narrow **capillaries** form net-works which surround the tubular glands, while beneath the epithelium wider capillaries encircle the mouths of the follicles. From this superficial capillary net-work the veins arise and, passing between the follicles, join the deeper venous plexus, which in turn empties into the larger veins of the submucosa.

In those parts of the intestine where **villi** exist, special additional arteries pass directly to the bases of the villi, where they expand into capillary net-works which run beneath the epithelium and around the central lacteal as far as the ends of the villi. These capillaries terminate in venous stems which descend almost perpendicularly into the mucosa, in their course receiving the superficial capillaries encircling the glandular ducts. Brunner's glands and the solitary and agminated follicles are supplied from the submucosa by vessels which terminate in capillary net-works distributed to the acini of the glands and to the interior of the lymph-follicles.

The **lymphatics** of the intestinal tract are very abundant. They begin as blind canals, whose slightly-dilated ends lie within the mucosa between the tubular follicles; in those parts of the intestine where villi exist, the centre of these projections is occupied by a lymphatic radicle, the chyle-vessel, or lacteal. All these vessels descend to join a rich plexus of lymphatic trunks situated within the deeper layers of the mucosa. Within the **submucosa** an additional net-work of still larger channels exists, the two sets of vessels freely communicating through numerous anastomoses. The accumulations within these net-works are carried off by lymphatic trunks which pierce the muscle and pass off between the two layers of the peritoneum into the adjacent mesenteric glands, in their course taking up the vessels carrying the lymph collected from the muscular tissue. Many vessels of the submucous net-work, as well as the larger lymphatic trunks, are provided with valves, whose position is usually indicated by dilatations in the contour of the vessel.

The **nerves** distributed to the intestines are arranged almost identically as those of the stomach; they are composed largely of non-medullated fibres, derived from the trunks which pass within the mesentery from the large abdominal sympathetic plexuses. After giving off branches to the serous coat, the nerves pierce the longitudinal muscular tunic to form the rich intramuscular **plexus of Auer-**

bach. This is composed of a rich net-work of delicate, pale fibres, at the nodal points of which microscopic ganglia exist; after supplying the longitudinal and outer part of the circular muscular coats, the fibres obliquely pierce the latter tunic to gain the submucous tissue, where they form the **plexus of Meissner,** which closely resembles Auerbach's nervous net-work within the muscularis, possessing, however, smaller ganglia and somewhat closer meshes. From the plexus of the submucous tunic fibres pass into the mucosa to form net-works about the glands and to send fibrillæ into the villi. The ultimate distribution of these fibres must be regarded as still undetermined.

THE LIVER.

Although the liver in its development corresponds to a **compound tubular gland,** a type which is permanently retained in many lower vertebrates, in the adult condition of the mammalian organ this character is largely masked in consequence of the fusion of the tubes in the formation of the cords of cells.

FIG. 216.

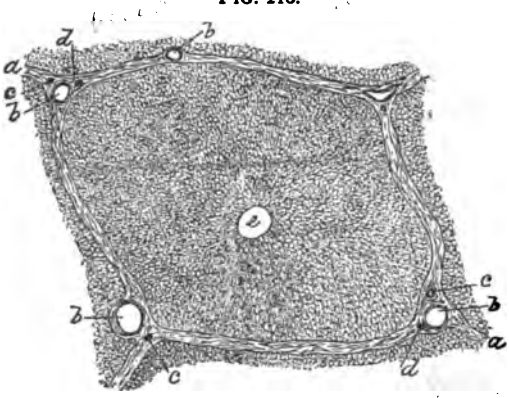

Section of liver of hog, showing very diagrammatically the lobules: *a*, interlobular connective tissue; *b*, *c*, branches of portal vein and of hepatic artery; *d*, bile-ducts; *e*, intralobular vein.

The **fibrous tissue** enveloping the exterior of the liver is prolonged into the interior of the organ through the transverse fissure, in company with the blood-vessels and the bile-ducts. The demarcation of the individual lobules depends upon the development of this interlobular connective tissue, known as the **capsule of Glisson;** when well developed, as in the liver of the hog, the lobules are defined with great distinctness, being completely surrounded and separated from their neighbors by the connective tissue. In the human liver, on the contrary, the interlobular connective tissue is very scanty, this deficiency producing poorly-defined lobules, the boundaries of which are scarcely indicated by the irregular areas of connective tissue occupying the spaces between the approximated surfaces of three or more hepatic lobules.

The **arrangement of the blood-vessels** is so important in determining the general construction of the lobule that an early con-

FIG. 217.

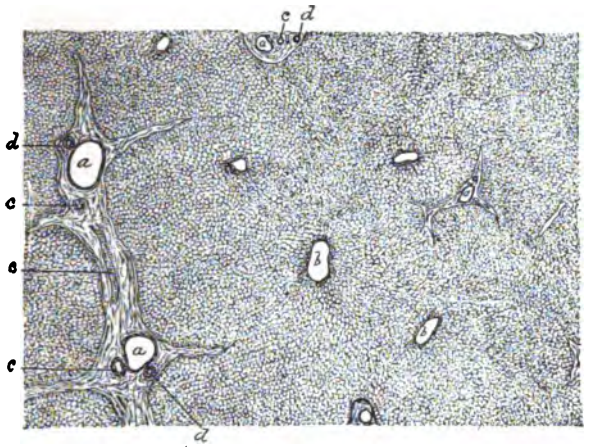

Section of human liver, showing general arrangement of lobules: *a*, interlobular (portal) vein; *b*, intralobular (hepatic) vein; *c*, hepatic artery; *d*, bile-duct; the boundaries of the lobules are imperfectly defined by the irregular areas representing the poorly-developed capsule of Glisson.

sideration of the vascular supply is necessary to an understanding of the structure of the lobule.

The **interlobular vessels,** situated between the lobules at their periphery, are continuations of those passing through the transverse fissure; they are the **portal vein,** the **hepatic artery,** and the **bile-duct.**

The **portal vein,** the largest of the interlobular vessels, gives off numerous branches, which enter the lobule at the periphery and break up into twigs, forming a rich, freely anastomosing **intralobular capillary net-work.** The meshes of this net-work are somewhat elongated and trapezoidal in form, the smaller end of the spaces being directed towards the centre of the lobule, an arrangement produced by the convergence of the capillary net-work to the centrally placed **intralobular vein,** a branch of the hepatic.

The **meshes** of this lobular capillary net-work are occupied by the

FIG. 218.

Diagram of the structure of the liver: *P. V.*, the portal or interlobular vein, which breaks up into the capillary net-work of the lobule; *H. V.*, central intralobular vein, a branch of the hepatic; *H. A.*, hepatic artery, supplying nutrition to the interlobular structures and terminating in the lobular capillary net-work; *B. D.*, the interlobular bile-duct which takes up the bile-capillaries at the periphery of the lobule.

secreting hepatic tissue, comprising the **liver-cells**, the **bile-capillaries**, the minute channels through which the bile elaborated within

FIG. 219.

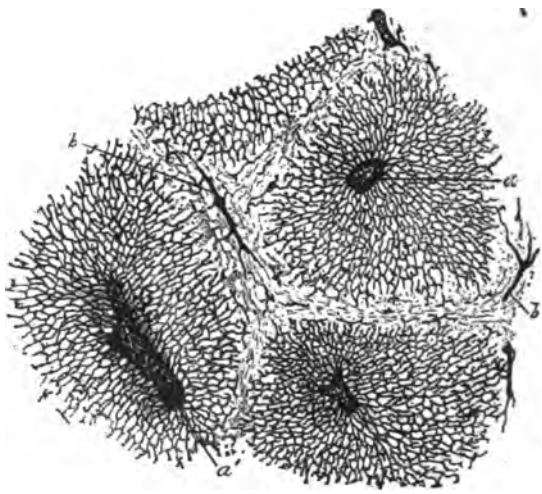

Section of injected human liver, the capillaries having been filled from the central vein (*a*); *b*, branches of portal vein.

the lobule is carried off, together with lymph-radicles and a very small amount of delicate **areolar tissue.** The **liver-cells** are irregular polyhedral elements (17–25 μ) in whose finely granular protoplasm, devoid of cell-membrane, one or more round nuclei lie embedded. Numerous oil-drops of various sizes, as well as pigment-granules, very commonly are present within the

FIG. 220.

Hepatic cells isolated from human liver: *a*, oil-drops; *b*, slight concavity produced by blood-vessels

FIG. 221.



Section of uninjected human liver: *a*, cords of liver-cells lying between the blood-channels (*b*).

protoplasm. The variations in the apparent granularity of the cell depend, as in other glands, upon the condition of functional activity

the nearer complete exhaustion, the less emphasized are the granules and the smaller and darker the cells.

The meshes of the **capillary net-work** are usually only sufficiently wide to accommodate a few liver-cells, in consequence of which arrangement almost every hepatic element is bounded directly on at least one side by a capillary blood-vessel, a relation conducive to free interchange between the blood and protoplasm of the cells. With few exceptions every liver-cell exhibits a **slight concavity** on one border, which denotes the position of contact and impression by the blood-vessels.

FIG. 222.

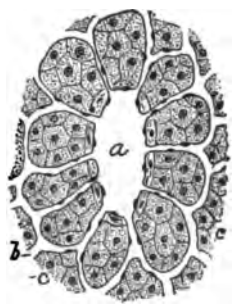

Section of centre of lobule of human liver: *a*, intralobular vein, into which the capillaries (*b*) converge; *c*, hepatic tissue.

In uninjected organs the hepatic tissue appears made up of irregular, branching, and anastomosing **cords of cells**, which form close net-works, the intervening clear clefts being the lumina of the blood-capillaries. According to Disse's studies, the liver-cells do not lie immediately in contact with the capillaries, but are separated from the latter by delicate **perivascular lymphatic channels** which envelop the blood-capillaries.

In livers still retaining their primitive type of the tubular gland the bile-capillaries appear as minute ducts placed centrally within the cords of the hepatic cells, the biliary passages representing lumina of tubular acini lined with secreting glandular epithelium. In man, however, the liver-cells are often bordered on all sides, except on that lying next the blood-vessels, by the delicate **bile-canaliculi**, the latter never interposing between the cells and the blood-channels.

FIG. 223.

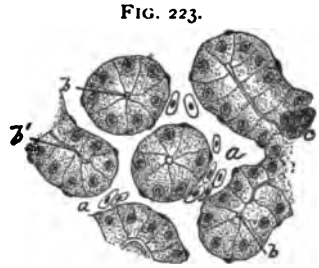

Section of liver of frog, exhibiting tubular character of gland: *a*, blood-channels containing corpuscles; *b*, lumina of hepatic cylinders which correspond to bile-capillaries; *c*, pigment-cell.

The **bile-capillaries** exist as narrow (1–2 μ) clefts between adjacent liver-cells, maintaining about the same diameter throughout the lobule; at the periphery the **intercellular channels** pass into the larger, though still small, **interlobular bile-ducts.** The hepatic cells between which the bile-capillary takes its course become replaced at the periphery of the lobule by the low epithelium of the bile-duct, the basement-membrane present in the latter fading away into the delicate connective tissue holding together the cords of liver-cells.

The existence of a distinct independent wall to the bile has been the subject of much conflicting testimony; ac some, these vessels out distinct walls own, while other regard the existenc cate special wall co a homogeneous st membrane as e The presence of membranous wall s tionable; when it that the bile-capill represent lumina **fied tubular gla** seems to be no gre sity for or probabi existence of a me limit the lumen of tubule than in the case of other glands. The direct t tion of the secreting hepatic cells into the epithelium o duct at the marg lobule further op assumption of suc membrane, while e of livers in which lar type of the a tained fails to s structures within t of the tubes.

FIG. 224.

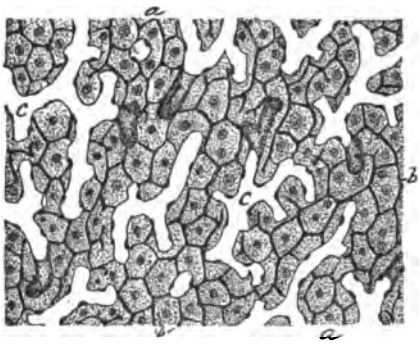

Section of rabbit's liver in which the bile-capillaries (*b*) have been injected and appear as dark lines between the cells: *c*, blood-channels.

FIG. 225.

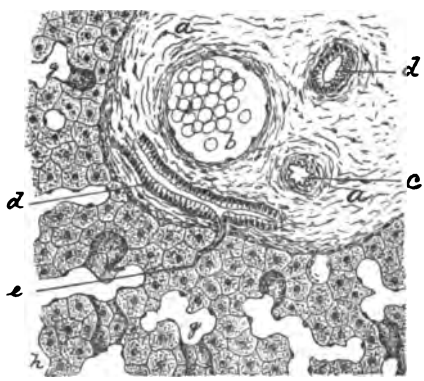

Section of liver of dog, including portion of lobule and interlobular connective tissue (*a*); *b*, portal vein; *c*, hepatic artery; *d*, bile-ducts; *e*, small peripheral bile-vessel; *g*, blood-channels; *h*, hepatic tissue.

Emerging from at the periphery t the adjacent interl nective tissue, the ducts empty into ones, which bear th of the hepatic bl company. The **int bile-vessels** gra crease in size, ow repeated union of the smaller tubes, until the larger trunk form the hepatic duct. While the **walls** of the smaller consist of **columnar epithelium** strengthened by fib nective tissue mixed with elastic fibres, those of the lar

comprise an **outer fibrous adventitia** and an **inner mucous membrane.** The latter, in addition to the columnar epithelium, consists of the tunica propria, containing many elastic fibres and some delicate bundles of involuntary muscle, irregularly disposed as circular and longitudinal bundles. Small **mucous glands** also occur within the mucosa of the larger canals and of the hepatic duct. The interlobular bile-ducts may be distinguished from blood-vessels of the same size by their lining of **columnar epithelium.**

FIG. 226.

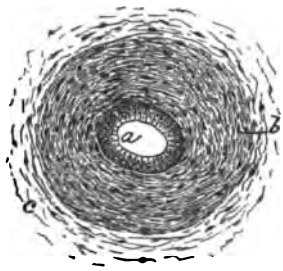

Transverse section of large bile-duct from human liver: *a*, epithelial lining; *b*, fibro-muscular coat; *c*, surrounding areolar tissue.

The **blood-vessels** of the liver, as already described, are of primary importance in determining the arrangement of the hepatic tissue. The blood brought by the interlobular branches of the portal vein passes into the lobule at the periphery by the numerous twigs; these, on entering the lobule, form a closely anastomosing **intralobular capillary net-work,** which converges to a central intralobular vein. The central vessel is vertically placed with regard to the general plane of the capillary net-work, and empties into the adjacent **sublobular veins,** which are branches of the hepatic vein, lying within planes generally at right angles to those of the portal vessels.

The **hepatic artery** has directly nothing to do with the elaboration of the especial products of the organ, its particular province being to supply the blood for the **nutrition** of Glisson's capsule and of the interlobular structures, including the blood-vessels and the bile-ducts. Minute arterial twigs are distributed to the walls of these tubes, where they end in delicate capillary net-works, which, in turn, at the periphery of the lobule, pour their contents into the intralobular net-work of the portal vein.

The **lymphatics** of the liver constitute a superficial and a deep system. The **superficial** lymphatics accompany the branches of the arteries supplying the capsule, and form a close-meshed subserous net-work within the capsule.

The interlobular blood-vessels are accompanied by numerous lymphatics, whose ramifications and anastomoses constitute the **deeper plexus.** The presence of lymphatics within the parenchyma of the liver is still a matter of dispute. According to Disse, the lymphatic channels exist throughout the lobule as perivascular canals, surrounding the capillaries and separating them from direct contact with the secreting cells.

The main **nerve-trunks** of the liver enter at the transverse fissure in company with the blood-vessels and the lymphatics. The fibres consist largely of the non-medullated, together with a smaller number of the medullated variety. These nerves run within the interlobular connective tissue in company with the hepatic artery. They may be traced with certainty to the periphery of the lobule; regarding the exact mode of their ultimate distribution, however, nothing is definitely known. Minute ganglia occur along the interlobular trunks.

The **gall-bladder,** or **bile-sac,** possesses walls composed essentially of the same tissues as those of the larger bile-ducts, these consisting of a **mucous membrane** supplemented by oblique bands of involuntary muscle and an **outer fibrous coat.** The mucosa is thrown into minute **folds** or **rugæ,** which unite and interlace to form a network of ridges and give to the surface of the mucous membrane a reticulated appearance.

The blood-vessels, the lymphatics, and the nerves form net-works within the mucosa, which usually terminate in the superficial or inner layers of the tunica propria.

THE ACCESSORY DIGESTIVE GLANDS.

These include the **salivary glands**—the parotid, the submaxillary, and the sublingual—and the **pancreas.** While in their quiescent, immature condition all are similar, after full functional development is attained the variation in the character of their secretions leads to the recognition of **two** groups—the **serous** and the **mucous** salivary glands. Those of the **serous type,** regarded as the **true salivary glands,** are represented in man and mammals by the parotid gland and the pancreas. The **mucous glands** are well represented in man and many animals by the sublingual, although the presence of serous acini places this organ, strictly considered, within the category of the mixed glands.

The **muco-serous** or **mixed glands** are exemplified by the submaxillary of man and many mammals (as apes, guinea-pig, etc.); in other animals (as dog or cat) this gland is entirely mucous, while in certain others (as the rabbit) it is a true serous gland.

THE SALIVARY GLANDS.

The **parotid** is a compound saccular or **racemose gland,** enveloped in a general fibrous **capsule** from which stout connective-tissue **septa** penetrate the organ, dividing the gland into **lobes.** These latter are subdivided by fibrous partitions into numerous **lobules,** each of which, in turn, is composed of groups of the **ultimate saccules** or **acini.**

The large **excretory duct** of the parotid gland, or **Stenson's duct,** contained within the interlobular connective tissue, is composed of a fibro-elastic **tunica propria,** lined by a simple **low columnar epithelium,** and strengthened externally by fibrous tissue. Passing into the smaller ducts, the **salivary tubes,** the cylindrical epithelium becomes slightly taller, and exhibits a distinct vertical radial striation in its outer zone. On entering the intralobular divisions of the ducts, or **intermediate tubes,** the columnar epithelium is replaced by low flattened cells, which finally pass into the dilated terminal compartments, becoming directly continuous with the secreting cells lining the acini.

FIG. 227.

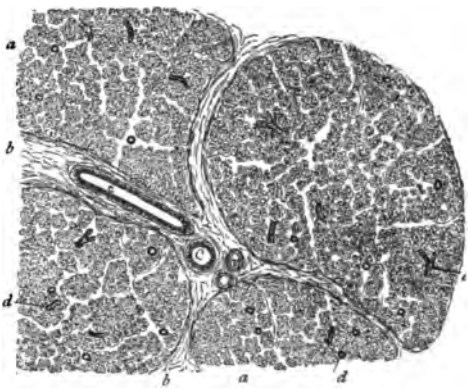

Section of human parotid gland, exhibiting general arrangement of lobules (*a*); *b*, interlobular connective tissue containing large ducts (*c*) and blood-vessels (*v*); *d*, intralobular ducts.

The **acini** are limited by the basement-membrane, the prolongation of that of the smaller ducts, and almost completely filled by the irregularly polyhedral **glandular epithelium,** the narrow intercellular cleft which remains representing the commencement of the lumen of the system of ducts. The appearance of the cells of the acini varies with the **stages of secretion;** when quiescent and filled with the serous secretion, the cells appear larger, clearer, and coarsely granular, while after functional activity and in the exhausted condition they are smaller, darker, and finely granular, the threads of the protoplasm lying closely packed, and not, as when the gland is at rest, separated by the intervening particles of stored-up secretion.

FIG. 228.

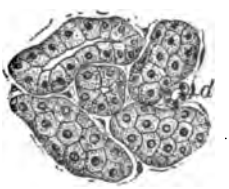

Section of human parotid gland, including several acini: *d*, cut intralobular duct.

The **sublingual gland** possesses the general arrangement already considered in connection with the parotid gland, its peculiarity being the absence of the intermediate division of the duct, the intralobular or "mucous" tubes passing at once into the acini.

The cells lining the saccules are encountered in all stages of secretion. **During rest** the majority are clear, being filled with homogeneous viscid mucus. After the discharge of this secretion, fol-

lowing **prolonged activity,** the cells appear smaller, dark and granular, and closely resemble the elements of the serous glands, since the mucoid substance separating the particles of the cell protoplasm has been removed, thereby allowing the displaced protoplasmic granules once more to approach closely.

Not all the cells in the acini are of the same nature, since quite usually small **crescentic groups** of granular cells lie immediately next the basement-membrane at the periphery of the acinus, where they have been crowded by the larger mucus-filled elements. These crescentic groups constitute the **demilunes of Heidenhain** or the **crescents of Giannuzzi,** which are aggregations of cells belonging to the serous type, similar to those of the parotid acini. The submaxillary is, therefore, a muco-serous or "mixed" gland. The excretory tube of the sublingual gland, or the **duct of Bartholin,** consists principally of a fibro-elastic tunica propria, within which is a single layer of low columnar cells, while outside extends a supplementary layer of fibrous tissue.

FIG. 229.

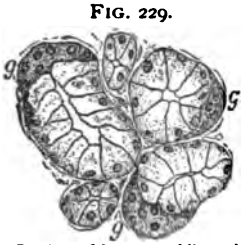

Section of human sublingual gland: among the clear cells lining the mucous acini are nests (*g*, *g*) of granular elements which constitute the demilunes of Heidenhain.

The **submaxillary gland** is a mixed gland, certain lobules being composed of acini of the serous type, while neighboring divisions contain those of the mucous variety.

The excretory channel, or the **duct of Wharton,** resembles that of the parotid gland, dividing into the smaller tubes lined by striated "rod" epithelium, passing thence into the intermediate tubules, with low cuboidal cells, which lead into the serous acini filled with dark granular cells on the one hand, or into those filled with mucous cells and granular crescents on the other.

The **vascular supply** of the salivary glands is very rich; while the arrangement of the blood-vessels in the several glands presents unimportant differences, their distribution is according to the same general plan.

The larger arteries accompany the excretory ducts of the glands within the interlobular fibrous septa, where they give off branches which pass between the lobules and later penetrate the tissue of the lobules to end in rich capillary net-works enclosing the acini. The capillaries lie immediately outside the basement-membrane in proximity to the secreting cells. The veins follow the general course taken by the arteries.

The **lymphatics** are represented by indefinite interfascicular clefts between the acini, which are taken up by definite lymph-vessels

situated within the interlobular connective tissue, the larger trunks accompanying the main blood-vessels.

The **nerves** distributed to the salivary glands constitute a rich supply, composed of both medullated and pale fibres. From the larger trunks of the interlobular net-works, along the course of which minute ganglia occur, smaller branches enter the lobules and extend between the acini. Regarding the ultimate distribution of the many fibres passing to the glandular tissue little is definitely known, notwithstanding the laborious investigations undertaken with a view to solve this difficult problem. The nerve-fibres may be traced to the basement-membrane of the acini, around which net-works are formed; as to the further fate of the fibrillæ, however, little can be regarded as proved. While an intimate relation between the nerves and the secreting cells may be assumed as undoubtedly existing, no direct continuity between these structures has been established, notwithstanding the already-published assertions and elaborate descriptions of such connections.

THE PANCREAS.

The **pancreas** is, as aptly described by its German name, "Bauchspeicheldrüse," the **abdominal salivary gland,** belonging to the **serous type,** and closely corresponding in structure and in the nature of its secretion to the parotid gland.

FIG. 230.

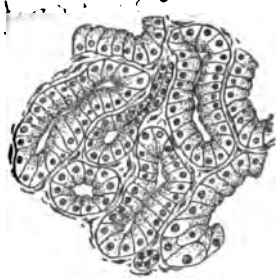

Section of human pancreas, including several acini and two ducts: the cells present a central granular and a peripheral clear zone.

The **connective-tissue framework** of the organ divides the glandular tissue into lobes, which are subdivided by septa into the lobules, these, in turn, being composed of groups of acini. The laminated fibrous connective tissue constituting the walls of the **pancreatic duct** is clothed by a single layer of **columnar epithelium.** The branches of the main duct divide at once into the long **intermediate tubules,** the intralobular ducts, or salivary tubes, being wanting; it follows that the vertical striation of the epithelium lining these tubes, so conspicuous in sections of the parotid gland, is absent in the pancreas.

The cylindrical cells of the larger ducts gradually pass into the lower cuboidal and flattened plates lining the intermediate tubules. The **acini** of the pancreas are more tubular than those of the parotid gland, while the **secreting cells** suggest more strongly the cylindrical or pyramidal type than those of the salivary gland; these cells are further characterized by the presence of a zone, next the

lumen of the acinus, containing numbers of highly refracting particles, while the peripheral outer half of the cells contains the nucleus and is comparatively free from the granules. The relations, however, between the clear and granular zones of the pancreatic cells are not constant, but vary with the condition of functional activity. During the earliest stages of digestion, when the cells are filled with secretion, the granules occupy almost the entire cell, the clear zone being confined to a narrow belt most removed from the lumen; towards the close of a period of functional activity, on the contrary, the granules occupy the smaller part of the cell, while the clear zone is expanded to a broad peripheral area; during fasting the clear and the granular zones about equally divide the cells.

On examining sections of pancreas under low amplification, certain **round** or **oval areas** appear lighter and less dense than the ordinary tissue of the organ. These peculiar areas, the **bodies of Langerhans** or **interlobular masses,** seem to be composed of groups of small, imperfectly-developed acini, among and about which ramify rich capillary net-works, whose frequently tortuous course and lobulated arrangement recall somewhat the glomeruli of the kidney. These **areas** possibly represent groups of special cells concerned in the elaboration of some particular pancreatic ferment.

FIG. 231.

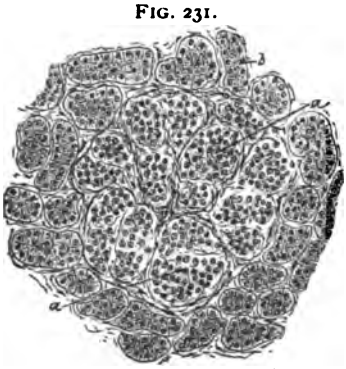

Section of human pancreas, exhibiting one of the areas (*a*) of immature gland-cells; *b*, the usual acini.

The **blood-vessels** of the pancreas are distributed very similarly to those of the salivary glands. The larger arterial branches run within the interlobular connective tissue, sending off vessels which pass between the lobules and supply the glandular parenchyma with twigs. These latter enter the lobules and form net-works which enclose the individual acini within the capillary reticulum. The capillaries lie beneath the basement-membrane in close relation with the glandular epithelium. The veins accompany the arterial trunks within the connective tissue.

The **lymphatic vessels** also accompany the arteries, lying between the lobules and receiving as tributaries the lymph-radicles originating within the lobule between the acini. The larger **nerve-trunks** are confined to the connective tissue between the divisions of the gland, in which situation many accompanying microscopic ganglia also are found. The ultimate termination of the nerve-fibres,

as in the case of the salivary glands, is still undetermined; the fibrillæ are traceable to the basement-membrane of the acini, but their further accurate disposition remains undecided.

The **development** of the digestive tract and its appendages involves all **three blastodermic layers,** the mesoderm and the entoderm, however, being the ones participating to the greatest extent. The epithelium of the mucous membrane, together with that of the glandular structures connected therewith, is the direct derivative of the entoderm, with the exception of that lining the oral cavity anterior to the fauces and the salivary and oral glands, the epithelium of which parts originates from the ectodermic invagination. For a short distance within the anus, likewise, the ectoderm contributes the cells lining the gut. As already pointed out, the enamel and the dentine are also products respectively of the ectoderm and of the mesoderm.

The **formation of the gut-tract** consists essentially of a process of folding off and closing together of the ventral body-plates, which are composed of the entoderm united with the visceral layer of the mesoderm. The tube thus formed begins in the cephalic region of the embryo as a blind, somewhat dilated pouch, the **primitive pharynx,** which for a short time is separated from the primary oral recess, or **stomodæum,** by a partition, the **pharyngeal plate,** consisting of the opposed ectoderm and entoderm; after the rupture of this plate the gut-tract communicates directly with the exterior through the oral cavity. A somewhat similar process takes place at the lower part of the primitive digestive tube, whereby the anus becomes established. For a considerable time the gut communicates with the cavity of the umbilical vesicle through its duct. The several divisions of the **primary digestive tube,** its wall consisting of epithelial lining and supplementary mesodermic tissue, undergo differentiation and acquire distinctive characters, which, however, depend largely upon the differentiation of the embryonal epithelial layer.

FIG. 232.

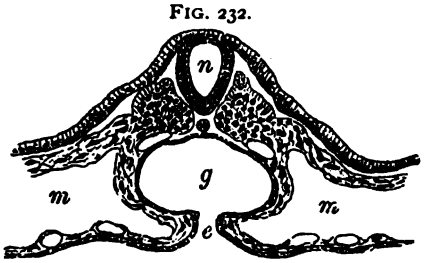

Transverse section of nine-day rabbit embryo, showing formation of primitive gut (*g*) by approximation of ventral plates composed of visceral layers of mesoderm and entoderm (*e*); *m*, *m*, body-cavity bounded by parietal and visceral sheets of mesoderm; *n*, neural canal.

The division of the tube into particular regions begins with the **stomach,** which as early as the fourth week in the human embryo is distinguishable as a spindle-shaped enlargement. With the subsequent rapid increase in the size of the organ, the tissues constituting

its walls also become augmented by many new elements, the mesodermic cells differentiating into a narrow looser zone next the entoderm, which later becomes the **submucosa,** and a broader, more compact stratum, representing the future **muscular tunic.** The entodermic cells, at first arranged as a single layer, soon undergo local proliferation, the resulting groups of cells disposing themselves as minute **cylindrical masses,** which are the earliest traces of the **peptic glands.** These increase in length and later encroach upon the underlying mesoderm. In the young gland six to eight **tubular divisions** communicate with a single duct, but as development advances the ducts divide, with a corresponding diminution in the number of terminal compartments connected with each. The **pyloric glands** appear about the same time as do the peptic, or at about the tenth week of fœtal life, the cells acquiring their characteristic form and appearance during the later stages. At first and during a considerable period the cells lining the peptic glands are all of the same variety; later certain elements become distinguished by the accumulation of **coarse granules** within their protoplasm; these constitute the **acid** or **parietal cells,** usually appearing towards the close of the fourth month of fœtal life.

FIG. 233.

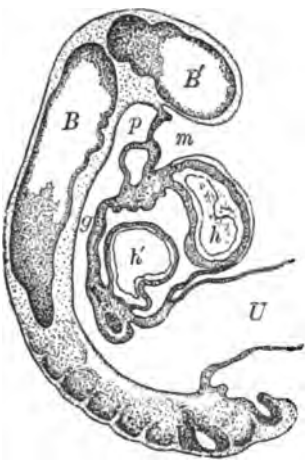

Sagittal section of nine-day rabbit embryo: *B*, *B'*, neural canal and brain vesicles; *m*, ectodermic invagination which contributes the lining of anterior part of future oral cavity; *p*, primitive pharynx, the blind upper end of the primitive gut (*g*) lined with entoderm, in this stage separated from ectoderm by septum; *U*, umbilical duct connecting gut with umbilical vesicle; *h*, *h'*, arterial and venous segments of young heart; delicate endothelial tube seen lying within primitive muscular walls.

The **intestinal divisions** of the primitive gut also depend for their distinctive characters on the differentiation of the entodermic epithelium and of the adjoining mesoderm, which together constitute the mucosa. The **villi,** distinguishable by the tenth week, are at first relatively short and thick and less numerous than later, when additional projections are developed. It is of interest to note that in the early stages **villi** appear in **both** the large and the small intestine, these structures subsequently atrophying and disappearing in the large gut while they increase in size and importance in the remaining parts of the tube. Coincidently with the formation of the villi the entodermic epithelium sends outgrowths into the mesoderm between the villous projections; these, at first solid, cylinders represent the early stages of the **simple tubular glands;** with the gen-

eral increase in the thickness of the young mucosa these structures lengthen and obtain their lumen. The **lower ends** of the glands throughout the period of their growth are the seats of active cell proliferation and the points at which the division of their fundi commences in the production of the compound tubules. The **endothelium** covering the serous surfaces of the intestinal tract is the direct descendant of the differentiated mesoderm, the mesothelium, lining the body-cavity.

The **development of the accessory glands** of the digestive tube, including the liver, the pancreas, and the salivary glands, follows the same general plan. The epithelial covering of the primitive mucous membrane sends cylindrical masses of entodermic or ectodermic elements, as the case may be, into the surrounding mesoderm; the originally single cord of cells very soon undergoes division, a richly-branched system of epithelial tubes early representing the future gland. The **liver** originates as a ventral outgrowth of the intestinal epithelium into the septum transversum; very soon this branches, the **two hepatic diverticula** following so closely upon the stage of the single outgrowth that the latter is sometimes overlooked. The **walls** of the distal ends of the diverticula soon become greatly thickened, which areas of entodermic epithelium represent the earliest traces of the hepatic tissue. Regarding the details of the further stages in the growth of the more complicated livers opinions do not agree; it is probable, however, that the hepatic cords of the mammalian organ are attributable to the same general plan of development as are other tubular glands, the complicated arrangement of the secreting tissue resulting from incomplete separation and subsequent fusion of the cell-cords. The invasion of the epithelial areas by the blood-vessels breaks up the entodermic tissue into the cell-nests which occupy the intercapillary spaces. Two forms of **liver-cells** are present during the greater part of fœtal life, large polyhedral elements, and small round cells, the latter disappearing shortly after birth; the relation between the two varieties is not clearly established, but the small cells are probably younger stages of the larger. **Multinucleated cells** of considerable size also occur within the blood-vessels of the embryonal liver; these are probably connected with the development of red blood-corpuscles before birth. The lining of the bile-vessels and of the interlobular bile-ducts, together with the hepatic cells, is a derivative from the entoderm, while the connective tissue and blood-vessels, as well as the tissues of the walls of the bile-vessels other than the epithelial lining, are contributions from the mesoderm.

The **pancreas** appears as three diverticula, one dorsal and two ventral, which extend from the duodenum into the primitive mesen-

tery. The organ first lies parallel to the sagittal axis of the body, afterwards changing its position so as to lie transversely, resulting in the approximation and subsequent fusion of the originally distinct rudiments as well as the ducts. The presence of more than one pancreatic duct in certain animals is explained by the persistence of the embryonal condition. The tubular acini of the organ are developed in a manner similar to that in which those of the other salivary glands are formed: the cylinders of entodermic cells send off branches, which, in turn, give rise to secondary buds, the lumen of the original diverticulum extending into the terminal compartments of the gland. The ingrowth of the surrounding mesoderm establishes the division into lobules and supplies the interlobular connective tissue.

CHAPTER XI.

THE URINARY ORGANS.

THE KIDNEY.

lney is a highly-developed compound tubular gland, com-
›yramidal lobules which correspond in number with the
læ and the primary pyramids: in the adult, however, their
s is lost, since
ıe blended to-
n laying open
organ by a
ıl section,
ons are ap-
the **cortex**
:dulla. The
'eadily distin-
the periph-
lar zone em-
ɛ outer third,
medulla ap-
ially striated
›ies the re-
wo-thirds of

ɛr surface of
la, next the
ients a num-
ninences, or
whose apices
ırge terminal
tubules or
ducts. Each
lla is the cul-
oint of a sys-
ling and sub-
ıbules, which

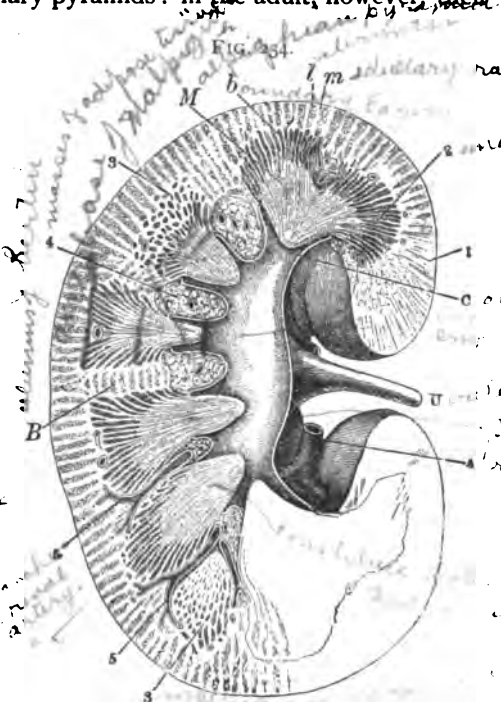

Longitudinal section of human kidney, exhibiting general relations of macroscopic details: *A*, renal artery; *U*, ureter; *C*, one of the calices into which a papilla projects; 1, cortex containing labyrinth (*l*) and medullary rays (*m*); 2, medulla; *M*, Malpighian pyramids, some obliquely cut at 3; *b*, boundary layer; *B*, columns of Bertin; 4, masses of adipose tissue; 5, branches of renal artery. (After *Henle*.)

form a **pyramidal mass,** the base of which corresponds
ace of the organ, while its apex is the papilla. These
tracts constitute the **lobules** of which the kidney is com-

posed. In the adult human organ all traces of such divisi usually disappeared; during fœtal life, however, the lobule tinctly seen, a condition which is permanently retained in the lower animals.

The **medulla** is occupied by 8–18 striated conical **Ma pyramids,** the apices of which correspond to the papillæ, w bases occupy the line of juncture between the cortex and the

FIG. 235.

Section of human kidney, including cortex and portion of medulla, showing general arrangement of tissues. Cortex (*C*) is imperfectly subdivided by bundles of parallel tubules constituting the medullary rays (*m*); between these lies the labyrinth (*l*) containing the Malpighian bodies (*x*); in places (*x'*) the glomerulus has fallen out, leaving the empty capsule; *b* and *v*, sections of blood-vessels.

Each pyramid alternating light **striæ,** these being respecti uriniferous tub the blood-vesse masses of the c tending betwee of the Malpigh mids as far as t constitute the **of Bertin,** and ersed by the lar vessels.

At certain poi their bases the st Malpighian pyr continued into t as slender, tape dles of parallel which form the **lary rays,** or p **of Ferrein.** penetration of t dles the corte divided into th **ullary rays labyrinth,** the propriately so r account of the great tortuosity of the component uriniferou The dark-red points irregularly studded over the labyrinth the position of the **Malpighian bodies.** In sections p the free surface the medullary rays appear as groups of tul rounded by the labyrinth on all sides.

The blood-vessels of the labyrinth are enveloped in c tissue, which latter represents the **interlobular tissue** glands and the boundaries of the primary lobules. The

parenchyma of the organ is held in place by the **interstitial connective tissue**; this is present between the tubules in most parts of the kidney in very small quantities,—the immediate vicinity of the Malpighian bodies and the papillary region of the medulla being exceptions, since considerable amounts of the interstitial tissue are present in these localities. The connective tissue of the kidney becomes condensed at the periphery of the organ, where it forms a **fibrous investment**, over which, in addition, the special **capsule** extends.

The **Malpighian bodies** are situated exclusively within the cortex, and are limited to the labyrinth. They consist of **two parts**—a spherical mass of convoluted capillary blood-vessels, the **glomerulus**, or the **Malpighian tuft**, and the surrounding expanded extremity of the uriniferous tubule, the **capsule of Bowman**. The glomerulus is supplied by an **afferent artery**, which divides into several branches; each of these breaks up into numerous **capillaries**, which are united by delicate connective tissue into groups or lobules. The blood escapes from the convoluted capillaries of the glomerulus by the **efferent vessel**, which passes out by the side of the entering artery.

FIG. 236.

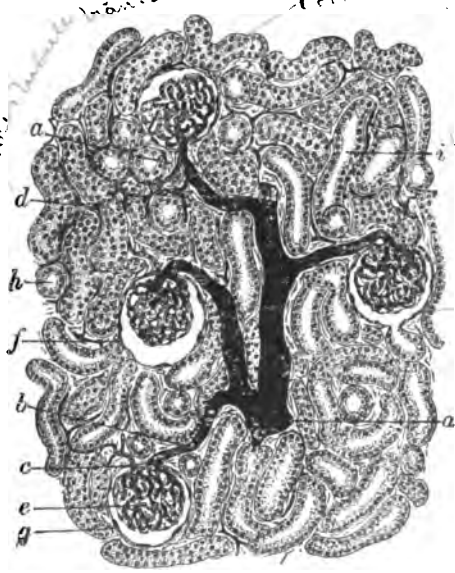

Section of human kidney partially injected: *a*, interlobular artery giving off afferent twig (*b*); *c*, efferent vessel passing into intertubular capillaries (*d*); *e*, convoluted capillaries of glomerulus; *f*, outer layer of Bowman's capsule, the nuclei of whose cells show at *g*; *h*, uriniferous tubule in transverse section, *i*, in oblique section

The **glomerulus**, as usually seen in sections, seems to lie within the capsule, the blood-vessels having apparently pierced the latter to gain entrance. The vessels, however, really are outside the cavity of the capsule, since one surface of this structure has been pushed in before the advancing tuft during its development. The masses of convoluted capillaries are closely invested by the **reflected portion** of the capsule, which likewise dips in between the vascular lobules of the glomerulus. The invaginated portion becomes continuous

FIG. 237.

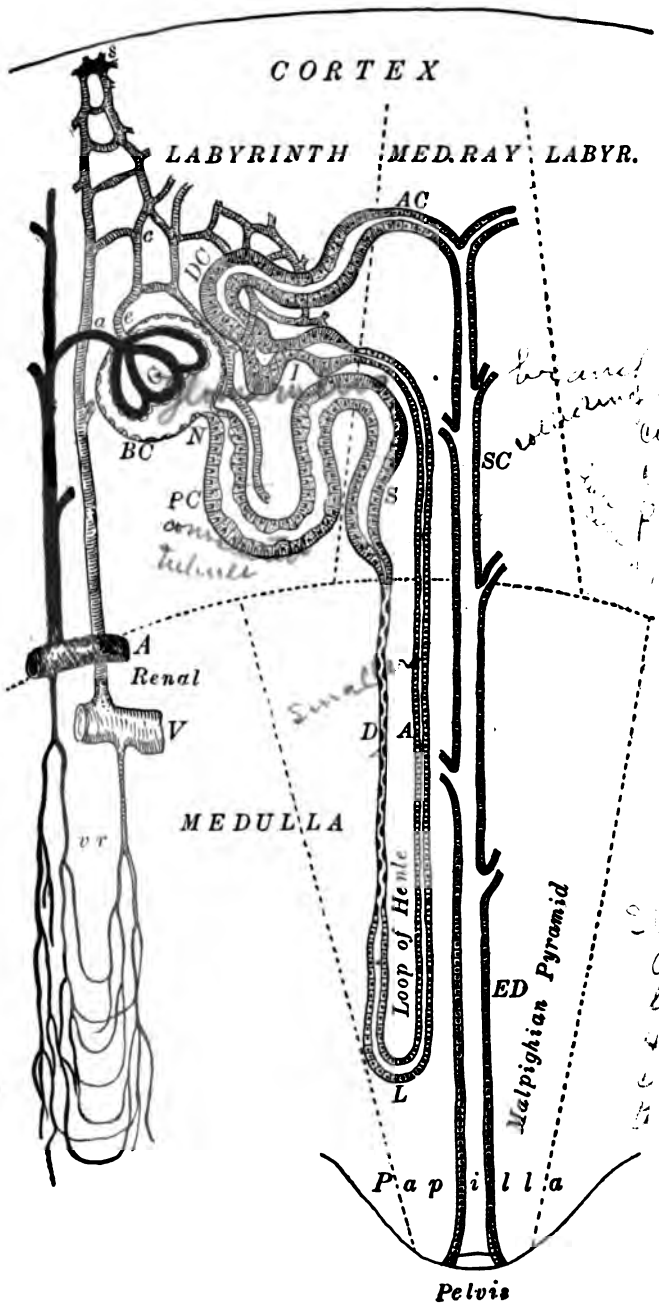

Diagram of the kidney, showing the course of the uriniferous tubules and of the blood convenience the medulla is represented as greatly shortened. The various divisions of Bowman's capsule, neck, proximal convoluted, spiral, descending and ascending limb Henle's loop, irregular, distal convoluted, arched collecting, straight collecting, and ex*are indicated* by their initial letters: *a*, *e*, and *c*, respectively the afferent, efferent, *blood-vessels*; *s*, stellate vein; *v r*, vasæ rectæ.

r layer of the capsule at the **stalk** of the glomerulus, at he vessels and the capsule are intimately united.

iferous tubule begins within the labyrinth as the **le of Bowman.** A greatly constricted **neck,** situated of the Malpighian body opposite the position of the , leads into the first or **proximal convoluted tubule,** acterized by its considerable size and tortuous course. labyrinth, to which it has thus far been confined, the the medullary ray and passes towards the medulla as avy **spiral portion**; on reaching the medulla a marked i the size of the tubule takes place, the reduced tube he medulla as far as the papillary zone as the **descend-Henle's loop,** the narrowest part of the entire urinifer- The spiral tubule is practically the beginning of the mb of Henle's loop, and takes the place of this arm in y ray, into the constitution of which, strictly regarded, ter.

reaching the loop itself the tubule becomes slightly ing a diameter which is retained throughout the **loop ding limb**; on again reaching the cortex, the ascend- ers the medullary ray as its second constituent until it ters the labyrinth, to become, for a short distance, the **irregular tubule.** The succeeding second or **distal portion** resembles very closely the proximal part of ossessing a similar size and tortuous course. The uri- le finally leaves the labyrinth as the **arched collecting** ter, for the third time, the medullary ray as the **straight ibe.** In consequence of the frequent union of canals of the collecting tubes rapidly increase in diameter as they nedulla, until, in the papillary layer, the narrow tubules the large **excretory ducts,** or **tubes of Bellini,** whose ne free surface of the papillæ are recognizable by the

A certain number of tubules probably do not form ule, but pass directly to become the collecting canals

oregoing it will be seen that the

contains:

- *Malpighian bodies*—glomeruli and capsules;
- *Constricted necks of tubules;*
- *Proximal convoluted tubules;*
- *Irregular tubules;*
- *Distal convoluted tubules;*
- *Arched collecting tubules.*

Medullary ray contains:
- *Spiral tubules;*
- *Ends of arched collecting tubules;*
- *Straight collecting tubules.*

Medulla contains:
- *Descending limbs of Henle's loops;*
- *The loops;*
- *Ascending limbs of the loops;*
- *Collecting tubules of all sizes.*

While the **labyrinth** is characterized by the irregular and tortuous course of its tubules, the **medullary ray** and the **medulla** are distinguished by the longitudinal, generally parallel arrangement of their components.

The **wall** of all parts of the tubule consists of the basement-membrane and the lining epithelium; the variations in the character of the latter are so numerous that it is desirable to consider each portion of the tubule in detail.

1. The **capsule**, the expanded and invaginated blind termination of the uriniferous tubule, is lined with a single layer of large, flattened epithelium, resembling endothelial plates. This covers, likewise,

FIG. 238.

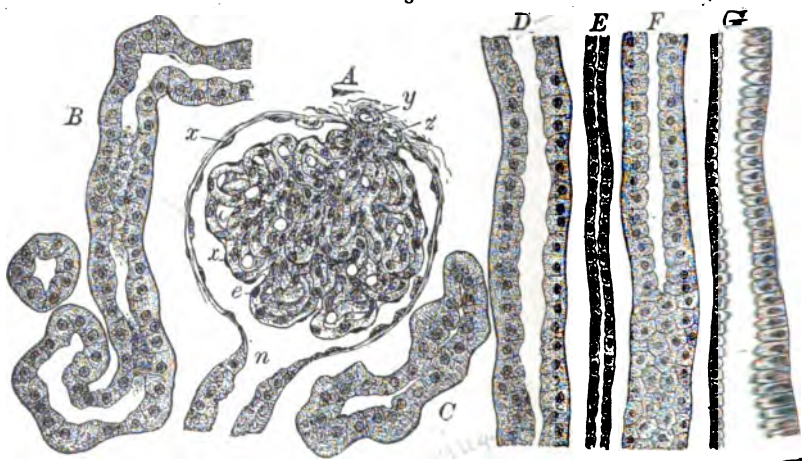

Portions of the various divisions of the uriniferous tubules drawn from sections of human kidney: *A*, Malpighian body; *x*, squamous epithelium lining the capsule and reflected over the glomerulus; *y*, *z*, afferent and efferent vessels of the tuft; *e*, nuclei of capillaries; *n*, constricted neck marking passage of capsule into convoluted tubule; *B*, proximal convoluted tubule; *C*, irregular tubule; and *F*, spiral tubules; *E*, ascending limb of Henle's loop; *G*, straight collecting tubule.

the portion reflected over the glomerulus. In ordinary preparations the presence of the cells is indicated by the delicate spindle nuclei seen in profile; the numerous nuclei seen within the tissues of

:lude those of the walls of the blood-vessels and of the
ıe, as well as those of the capsular epithelium.
eck the flattened epithelium abruptly becomes cuboidal
ssumes the character of the lining of the convoluted
existence of ciliated epithelium at the neck or within
:he mammalian kidney has been asserted, but not satis-
ished; in many of the lower animals, however, as in
s, the presence of cilia is readily demonstrated, as is like-
ıce of tubules opening directly into the peritoneal cavity.
-shaped orifices—the **nephrostomata**—represent a
nce of the primitive type of excretory organ, in which
ss directly from the body-cavity to the outer surface.
›ximal convoluted tubule is clothed with low co-
›oidal cells, whose granularity and transparency vary
of secretion, as do likewise the thickness of the epi-
ıe size of the lumen of the canal. The outer zone of

IG. 239.

›f amphiuma: the peritoneal
s one of the nephrostomata
ed cells; *d*, glomerulus sur-
; *u*, uriniferous tubules; *v*,
red blood-cells.

FIG. 240.

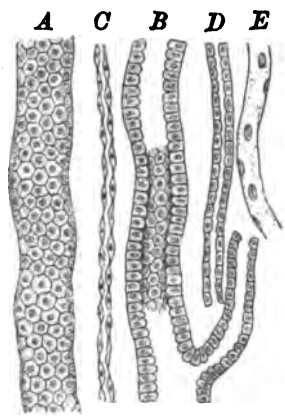

Portions of the constituents of the medulla from the human kidney: *A*, *B*, collecting tubules; *C*, *D*, descending and ascending limbs of Henle's loop; *E*, blood-vessel.

, next the basement-membrane, presents more or less
ertical striation distinguishing rod-epithelium. The
f the individual cells is not sharply marked, their
ng indistinctly defined.
helium of the **spiral tubule** closely resembles that of
portion, consisting of similar low columnar elements
nular protoplasm but less marked striations.

5. The conspicuous diminution in diameter which marks t sage of the spiral tubule into the **descending limb of Henle** is accompanied by a change in the character of the lining epitl The low columnar cells are replaced by flattened, transparent whose nuclei, thicker than the bodies of the cells, encroach u lumen of the tubule as minute spindle-shaped projections; si latter are situated often on opposite sides of the tube, its lu section appears as a wavy channel.

6. Shortly before reaching the loop, at a point within scending limb corresponding with the increased diameter tubule, the epithelium becomes polyhedral, possessing fi nuclei and faint striations; the lumen is distinct in this although narrow. character is retained epithelium through **loop** and the **asc limb** as far as the s ing portion of the tu

FIG. 241.

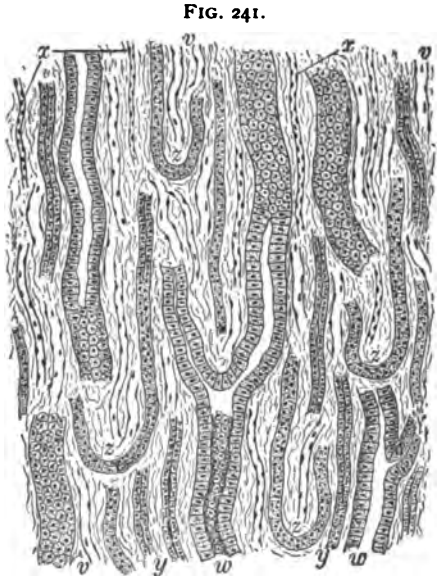

Section of medulla of human kidney: *w*, large collecting tubules; *x* and *y*, descending and ascending limbs of Henle's loops; *z*, loops of Henle; *v*, blood-vessels.

7. The **irregular** is distinguished by it and uncertain lume its distinctly striate thelium; the thickr the latter and, quently, the size canal vary with th ditions of secretion.

8. The lining of t **tal convoluted** resembles that of the mal, the epithelium granular, indistinctly rated into individua and presenting a s outer zone; the lur the canal depends upon the thickness of the lining cells, which changes with th tional activity of the secretory elements.

9. The succeeding segment, the **arched collecting tubul** tains low cuboidal, transparent cells, which, with slight alte become the epithelium of the **straight collecting tubule.**

10. Passing into the medulla, the cells of the **collecting tu** become markedly columnar, which form they retain with incr distinctness throughout the remainder of their course. The

excretory ducts, or **tubes of Bellini**, in the papillary region present a beautiful example of simple columnar epithelium in the tall, transparent, and clearly-defined cells with which they are lined. These cells, the largest epithelial elements within the kidney, are defined from one another with great distinctness, and possess oval nuclei situated somewhat nearer their outer boundaries.

FIG. 242.

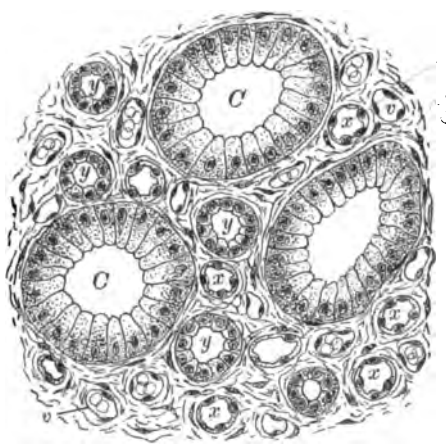

Transverse section of papillary region of medulla of human kidney, more highly magnified: *C*, large collecting tubules; *x* and *y*, descending and ascending limbs of Henle's loops; *v*, blood-vessels.

The **blood-vessels** within the kidney are very plentiful. The **renal artery**, entering at the hilum, passes through the sinus within the submucous tissue which occupies the space between the wall of the pelvis and the neighboring parenchyma; during its course through the sinus several small twigs are given off for the nutrition of the structures in the immediate vicinity. Before entering the glandular tissue the renal artery breaks up into a number of large branches, which traverse the parenchyma through oblique channels within the interpyramidal tracts, or columns of Bertin, to gain a position at the **juncture of the cortex and medulla** corresponding to the bases of the Malpighian pyramids. At this point they bend sharply to form a series of horizontal **arches**, from which two sets of vessels spring—the ascending **interlobular cortical arteries** and the **arteriæ rectæ** of the medulla.

The straight **cortical branches**, passing towards the free surface of the organ, give off short, curved lateral twigs to supply the **afferent vessels** of the glomeruli. These branches divide into groups or lobules of convoluted capillaries; the latter, in turn, join to form the slightly smaller **efferent vessels**, which carry off the still arterial blood from the Malpighian bodies. The efferent vessels soon break up into **capillary net-works** which surround the tubules of the labyrinth and the medullary ray. These net-works are taken up by the **interlobular veins** which accompany the arteries, and pass to the pelvis, where they aid in forming the large renal veins. The vessels collecting the blood from the **peripheral zone** of the cortex

converge to certain points, where they form the **venæ stel** these veins afterwards pass into the labyrinth and follow the lobular vessels.

FIG. 243.

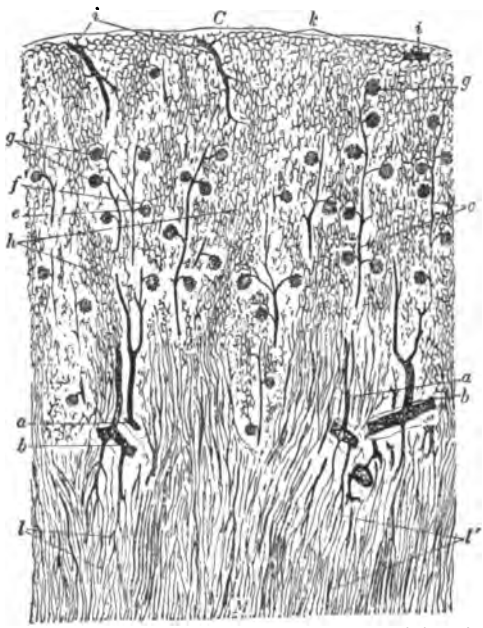

Section of injected kidney of dog, showing general disposition of blood-vessels: *a* and *b*, large arterial and venous branches situated at junction of cortex (*C*) and medulla (*M*), which break up into ascending interlobular twigs (*c*) and descending straight vessels (*l*, *l'*); *e*, *f*, afferent and efferent vessels of glomeruli (*g*); *h*, intertubular capillary net-works; *i*, peripheral venous trunks, which collect the blood from subcapsular net-works (*k*).

The arteries s ing the medulla as straight vessel **arteriæ rectæ,** undergo repeated ion to form rich lobular net-works ing as far as the p where the orifices excretory ducts a rounded by capi The blood with medulla is collec the **venæ rectæ,** accompany the sponding arterie empty into the veins situated a juncture of the and the medulla. **large venous** t pass obliquely t the medulla, alon the arteries, to re pelvis, where the with their fellows the **renal veins.**

The **lymphat** the kidney are arranged as **two sets** of vessels; a **superfici** tem ramifies within the deeper layers of the capsule, while a of **deeper channels** passes in company with the blood-vess the interior of the organ to communicate with the numerou phatic clefts and spaces which exist within the intertubular con tissue.

Regarding the ultimate distribution of the **nerves** of the l little is known with certainty beyond the fact that they en parenchyma in company with the blood-vessels, around whi form net-works of non-medullated fibres; the nerve-fibres ha traced between the tubules, where they form meshes imme outside the membrana propria. The ultimate distribution fibrillæ and their relations to the secreting cells are still uncer

THE RENAL SINUS AND THE URETER.

The greater part of the **renal sinus** is occupied by the dilated, pouch-like expansion of the upper extremity of the excretory duct of the kidney, the **ureter,** embracing the **pelvis** and its subdivisions, the **calices,** and the **infundibula.** These cavities, together with the protruding portions of the renal papillæ, are invested by a membranous structure consisting of three coats, the **mucous,** the **muscular,** and the **fibrous.** The **mucous coat** is covered with stratified squamous epithelium, which comprises relatively few layers of cells, and is frequently termed "transitional," in view of the rapid change

FIG. 244.

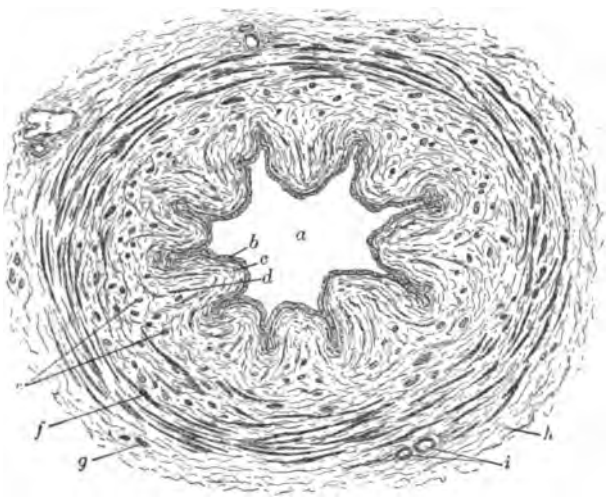

Transverse section of human ureter: *a*, irregular lumen, lined by mucous membrane, which consists of epithelium (*b*), tunica propria (*c*), and submucous tissue (*d*); *e*, *f*, longitudinal and circular bundles of muscular tunic; *g*, additional longitudinal muscular bundles; *h*, fibrous tissue; *i*, blood-vessels.

from the columnar elements of the deep layer to the squamous ones of the superficial stratum. The **tunica propria,** or stroma of the mucous membrane, consists of a felt-work of fibro-elastic bundles, contains probably no well-defined glands, and passes insensibly into the inconspicuous submucous tissue. The **muscular coat** is arranged as an **inner longitudinal** and an **outer circular layer** composed of bundles of involuntary muscle cells. On the papillæ the circular bundles are especially well developed, enclosing the renal tissue somewhat as a sphincter. The outer **fibrous coat** consists of irregularly-placed bundles of connective tissue, which connect the organ with the surrounding structures. The walls of the **ureter**

proper contain the same layers that are found in the pelvic portion of the tube; the **muscular tunic,** however, is somewhat better developed, and in the lower part of the ureter is augmented by an additional imperfect **external longitudinal layer,** although the latter is represented in places by only a few scattered bundles of non-striped muscle.

THE URINARY BLADDER.

The **bladder** is composed of the same coats that are found in the ureter, the **mucous,** the **muscular,** and the **fibrous,** together with the **serous surface** in those parts of the organ which possess a peritoneal covering. The **epithelium** of the bladder corresponds to that lining the ureter and the renal pelvis, being of the stratified squamous "transitional" type. The mucous membrane at the base of the bladder contains occasional small **glands;** minute **lymph-follicles** are also found within the mucosa. The **involuntary muscle** is arranged in three general layers, an **inner** and an **outer longitudinal** enclosing a **middle circular** stratum; the bundles composing these tunics are, however, so irregularly disposed that the layers are very imperfectly defined. At the base of the organ the inner longitudinal muscular bundles increase in size, while those of the augmented circular layer constitute the **internal vesical sphincter.**

FIG. 245.

Section of human bladder: *a*, squamous epithelium covering the folds of the tunica propria; *b*, submucous tissue; *c*, *d*, irregularly-disposed circular and longitudinal bundles of non-striped muscle; *e*, fibrous tissue of serous coat.

The **blood-vessels** of the ureter and the bladder supply the muscular and mucous coats with rich capillary networks, the one situated within the mucosa of the bladder being especially rich. The **lymphatics** have much the same distribution as have the blood-vessels, networks being found within the deeper layers of the mucosa, as well as more sparingly within the muscular tissue. The **nerves** supplying

the ureter and the bladder are largely composed of sympathetic filaments comprising both medullated and non-medullated fibres. The fibres pass into the mucosa as far as the epithelium; but whether they penetrate between the epithelial cells is still undetermined. Numbers of **microscopic ganglia** are situated along the course of the nerves of the bladder, this organ affording in smaller animals a favorable situation for studying ganglion-cells and nerve-fibres, as well as involuntary muscle cells.

THE URETHRA.

The **urethra,** both male and female, consists of a **mucous coat,** strengthened by a variable **muscular tunic** and by **fibrous tissue.**

The **female urethra** is lined throughout by a **stratified squamous epithelium,** which rests upon a basement-membrane covering the numerous small papillæ with which the surface of the tunica propria is beset. These **papillæ** are especially plentiful and well developed near the termination of the canal, in the vicinity of the meatus. The **tunica propria,** or stroma of the mucosa, is composed of interwoven bundles of fibrous and elastic fibres, the superficial layers of which, particularly in the vicinity of the internal orifice, are infiltrated with lymphoid cells. Small **tubular glands** are sparingly present. The **muscular tunic** is well developed and arranged as an **inner longitudinal** and an **outer circular layer** of non-striped muscle. The intermuscular connective-tissue lamellæ contain many elastic fibres.

The **male urethra** is lined with epithelium, the character of which varies in the different portions of the canal. In the **prostatic part** the epithelium resembles that lining the bladder, being of the **transitional** variety; this passes gradually into the **stratified columnar** type of the investment of the **membranous part,** which in turn gives place to a single layer of **simple columnar** cells in the **penile** portion. The **fossa navicularis** is lined with **stratified squamous** epithelium continuous with that covering the glans. In places the tunica propria bears papillæ, which are particularly well developed within the navicular fossa. The small tubular **glands of Littré** are found through the entire urethra. Inner **longitudinal** and outer **circular** bundles of non-striped muscle surround the prostatic portion, extending over the membranous part to be lost on the spongy. In addition, the fibres of the **compressor urethræ** muscle contribute a distinct muscular investment for the **membranous portion,** which fades away at either border over the penile and prostatic segments. The anterior part of the penile division is destitute of muscular tissue. Outside of the muscular layer a variable **fibrous tunic** gives additional firmness and strength to the canal. The walls

of the urethra are liberally supplied with **blood-vessels,** which form rich venous net-works beneath the epithelium. The larger **lymphatics** lie in the submucosa, where they receive the radicles accompanying the blood-vessels within the mucosa. The **nerves** which bear the blood-vessels company find their endings within the superficial sub-epithelial layer of the mucosa.

The Development of the Urinary Organs. In tracing the history of the formation of these structures the genesis of **three distinct divisions** must be considered—the development of the kidney and ureter, that of the bladder, and that of the urethra.

The permanent kidney is preceded in the embryo by an important although transient excretory organ, the **Wolffian body**; the products of this organ are carried off and emptied into the primitive intestinal canal by its excretory tube, the **Wolffian duct.** All parts of the Wolffian body and the duct consist of **mesodermic tissue** alone, these structures arising essentially as outgrowths from the primitive peritoneal lining into the surrounding mesoderm. The mesothelial evaginations so originating constitute the **primary tubules** of the Wolffian body, from which numerous secondary canals are derived; the subsequent development of blood-vessels in intimate relation with the tubules produces the **primitive Malpighian corpuscles** of the fœtal organ.

FIG. 246.

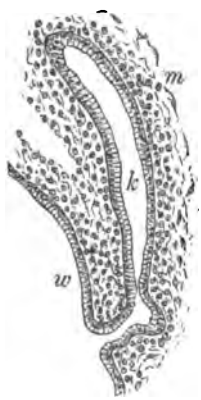

Sagittal section of eleven-day rabbit embryo, showing earliest stage of development of kidney as outgrowth (*k*) from Wolffian duct (*w*) into surrounding mesoderm (*m*).

The first step in the **development of the kidney** consists in a **dorsal outgrowth** from the Wolffian duct near its cloacal end; this diverticulum grows forward and parallel with the Wolffian duct until its extremity reaches a position behind and somewhat above the caudal end of the Wolffian body. The primary **kidney-tube** now expands at its upper end, the dilated portion subsequently undergoing peripheral cleavage into a number of **tubular compartments.** Coincidently with the growth and differentiation of the epithelial evagination from the Wolffian duct, the mesodermic tissue into which the expanded extremity of the diverticulum makes its way becomes greatly condensed. The fundamental structures in the development of the kidney and the ureter are now distinctly defined. The narrow, elongated portion of the outgrowth from the Wolffian duct becomes the **epithelial lining of the ureter,** while the expanded terminal part forms **that of the pelvis** and **of the uriniferous tubules.** The connective and vascular tissues are derived from

the surrounding mesoderm, the epithelium of the kidney and of its duct alone being the immediate product of the evagination. The formation of the **collecting tubes** and the **uriniferous tubules** follows the division and subdivision of the compartments into which the primitive pelvis and calices separate, the entire elaborate system of tubules resulting from the extension and branching of the primary canals. The surrounding mesodermic tissue early differentiates a limiting zone or **primitive capsule,** which defines the form of the developing kidney and opposes the growth of the tubules in a straight direction, thereby inducing the marked tortuosity accompanying the subsequent increase in the length of the uriniferous canals. The invagination of the termination of the tubule and the simultaneous devel-

FIG. 247.

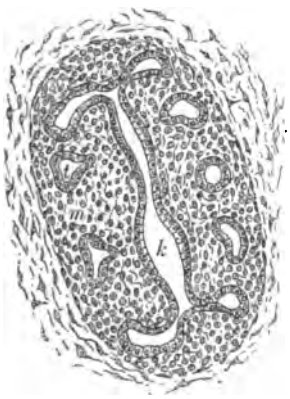

Sagittal section of fifteen-day rabbit embryo: the developing kidney presents an oval mass of condensed mesoderm (*m*) into which the tubular compartments (*t*) of the divided primitive renal pelvis (*k*) extend.

FIG. 248.

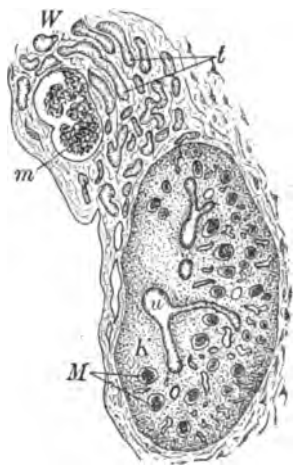

Sagittal section of 30 mm. cow embryo: *K*, developing kidney, containing Malpighian bodies (*M*) and tubules; *u*, part of renal pelvis; *W*, atrophic Wolffian body; *m*, glomerulus of primary Malpighian body; *t*, degenerating tubules of the organ.

opment of groups of capillary blood-vessels in intimate relation with them give origin to the characteristic **Malpighian bodies.** The **epithelium** of all parts of the uriniferous tubules, of the renal pelvis, and of the ureter is derived directly **from the outgrowth from the Wolffian duct;** the interstitial connective tissue, the blood-vessels, and other structures are contributed by the surrounding condensed mesoderm. Since, as has been already stated, the entire Wolffian body, including its duct, is a product of the mesoderm, the epithelial evagination and its derivatives must be referred likewise to the middle blastodermic layer, *all parts of the urinary*

tract as far as, but not including, the bladder being, therefore, of mesodermic origin.

The **development of the urinary bladder** is connected with the history of the **allantois.** The latter grows out of the hind gut as a diverticulum which reaches conspicuous dimensions, in many embryos appearing as a large, flask-shaped sac; in man, however, the allantois is never free, but grows as a stalk in close relations with the other structures passing through the umbilical opening. The portion of the allantoic canal lying **within** the embryo becomes differentiated into **three divisions:** the much larger **middle segment** greatly dilates and essentially constitutes the **bladder;** the **outer division,** extending from the bladder to the umbilicus, forms the atrophic **urachus,** while the narrow **inner portion** establishes communication between the bladder and the uro-genital sinus and assists the latter in forming the **urethra proper.** The primitive ureter, which at first opens in company with the Wolffian duct into the uro-genital sinus, changes the position of its exit until the tube finally assumes its permanent relations and opens into the bladder. The epithelium lining the allantois is a direct extension of the **entoderm** of the primary gut; the allantoic derivatives, including the bladder and the urethra, therefore, are **clothed with entodermic cells;** the muscular and connective tissues of their walls, however, are contributions from the mesoderm.

The short **female urethra,** extending from the bladder to the upper part of the vestibule, the representative of the **uro-genital sinus,** corresponds with the primary vesical canal, and is the **urethra proper.** In the **male subject** this passage is supplemented and greatly lengthened by the approximation and closure of the folds by which the sinus is converted into the narrow canal extending to the end of the penis. The male urethra, therefore, consists of **two** morphologically distinct divisions: the **urethra proper,** which includes that portion of the adult canal lying between the neck of the bladder and the uterus masculinus or sinus pocularis, this division being the strict homologue of the female urethra; and the remaining part of the canal, or **supplementary urethra,** which represents the closed and extended uro-genital sinus.

CHAPTER XII.

THE MALE REPRODUCTIVE ORGANS.

THE TESTICLE.

THE testicle is a highly-developed compound tubular gland. The parenchyma of the organ is enclosed within a fibrous capsule of especial thickness and strength, the **tunica albuginea,** which becomes greatly thickened on the posterior aspect of the testicle to form a dense connective-tissue mass, the **mediastinum,** or the **corpus Highmori.**

From the mediastinum stout fibrous **septa** radiate to the periphery, thus dividing the organ into a number of irregular **pyramidal compartments** or **lobules,** in which the seminiferous tubules are contained. The **tunica albuginea** consists of a dense fibrous felt-work of bundles of fibro-elastic tissue; the looser, inner layers support numerous blood-vessels, constituting the **tunica vasculosa.** The outer surface of the albuginea, through the greater part of its extent, is covered by the visceral layer of the **tunica vaginalis,** which supplies a serous investment to much of the testicle, as well as to a portion of the epididymis.

FIG. 249.

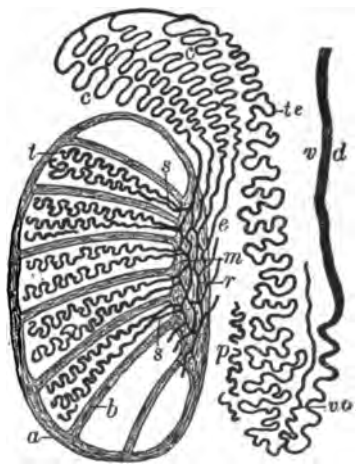

Diagram illustrating the course and the relations of the various constituents of the testicle and the epididymis: *a*, tunica albuginea; *m*, the mediastinum; *t*, convoluted, *s*, straight, portions of seminiferous tubules; *r*, rete testis; *e*, vasa efferentia; *c*, coni vasculosi; *te*, tube of epididymis; *vd*, vas deferens; *va*, vas aberrans; *p*, paradidymis.

The testicle lies behind and outside the serous sac, the latter becoming invaginated by the testicle during its descent into the scrotum; that part of the posterior border of the testicle included between the reflected folds of the tunica vaginalis is devoid of serous covering, and affords a position for the entrance and escape of the blood-vessels, the ducts, the lymphatics, and the nerves.

The **seminiferous tubules** may be conveniently divided into three portions: (1) the tortuous **convoluted tubules,** whose windings contribute the bulk of the lobule, (2) the **straight tubes,** situated in the apices of the pyramidal lobules, and (3) the **tubules within the mediastinum,** which by their union form the **rete testis.**

The seminiferous tubules terminate in the mediastinum, from which situation the seminal canals are continued by intermediate vessels connecting testicle and epididymis; these intermediate tubules are the **vasa efferentia** and the **coni vasculosi.** The former arise from the rete testis, while the latter are the progressively tortuous continuations of the vasa efferentia terminating in a mass, the

FIG. 250.

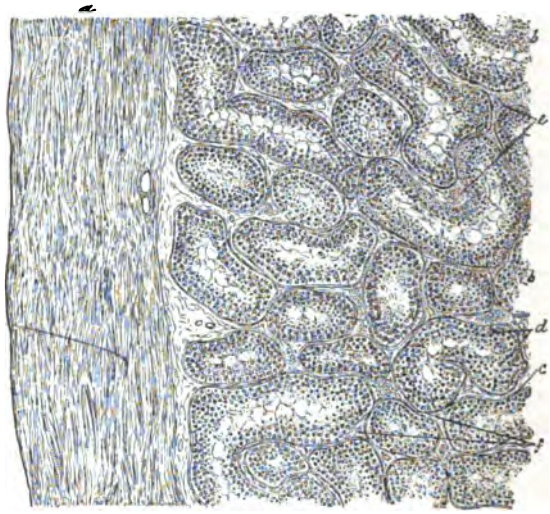

Section of human testicle, including portion of tunica albuginea, exhibiting general arrangement and structure of tubules: *a*, tunica albuginea; *b*, seminiferous tubules cut in various directions; *c*, basement-membrane; *d*, secreting cells; *e*, groups of interstitial cells; *f*, intertubular connective tissue.

globus major, which represents the sum of the tortuous coni vasculosi. These last-named canals unite to form the main tube of the epididymis, which is sufficiently convoluted to include its entire length of twenty feet within the inconsiderable bulk of the epididymis.

The **seminiferous tubules,** 130–140 μ in diameter, possess walls which are composed of several layers of flattened endothelioid connective-tissue plates, applied to which a thin basement-membrane

inside the latter lies the lining of epithelial cells. The pre-
ıaracter of the cells within the tubule depends upon the
on of **functional**
:y of the organ ; the
: differences distin-
ıg the elements with-
resting gland from
found in the active
depend largely upon
frequency within the
, and the almost uni-
presence within the
of cells actively en-
in karyomitotic divis-
The different tubules,
er, exhibit great vari-
in the exact stage
se changes, adjacent
and, in fact, parts of
ne one, often present-
ıe extremes of the
ide by side.

FIG. 251.

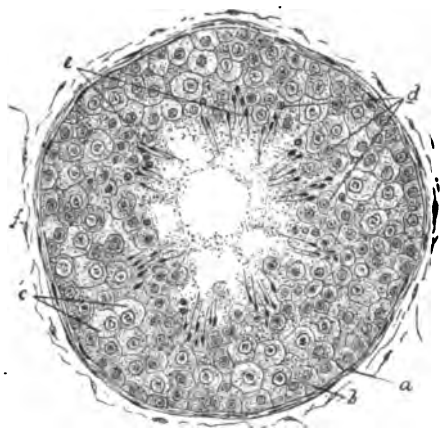

Transverse section of seminiferous tubule from human testicle : *a*, membrana propria ; *b*, zone of parietal cells ; *c*, mother-cells undergoing division ; *d*, daughter-cells, or spermatoblasts ; *e*, partially-developed spermatozoa ; *f*, surrounding intertubular connective tissue.

t the basement-
rane of the seminiferous tubule lies a layer of low cuboidal
ted **parietal cells**; this peripheral zone contains cells of
inds: (1) the **sustentacular cells**, or **Sertoli's columns**,
take no part in the formation
e generative elements, and (2)
permatogenic cells, which pro-
elements intimately related to the
ıpment of the seminal filaments.
the outer, peripheral layer, in
ınally active organs, an irregular
l zone contains many elements with
transparent nuclei and chromatin
s, indicating the progress of cell-
ın; these are the **mother-cells**,
rivatives of the spermatogenic cells
outer zone, and, in turn, the parents
ımerous progeny of smaller **daugh-
ells.** The latter constitute the
natids, from the metamorphosis
ıich the spermatozoa are later directly derived. The inner
of the tubule is frequently occupied by fan-shaped groups of

FIG. 252.

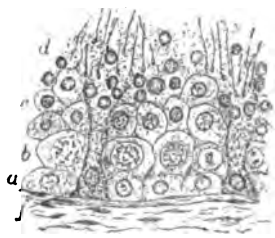

Section of testicle of dog, including part of seminiferous tubule : *a*, zone of parietal cells containing sustentacular elements (*f*) ; *b*, mother-cells ; *c*, daughter-cells ; *d*, free nuclei of spermatoblasts and developing spermatozoa.

developing spermatozoa, embedded within the inner end of the supporting cell of Sertoli.

Spermatogenesis varies among the different classes of vertebrate animals; the account here given refers to man and the higher mammals.

The originally round **spermatids** promptly exhibit a tendency to elongate and to become pyriform; several such cells, with partially-formed spermatic filaments, are often crowded together by the pressure of the surrounding elements, and, in consequence, come to lie in close relation and in intimate union with the centrally projecting protoplasm of the sustentacular cells. Such appearances, probably

FIG. 253.

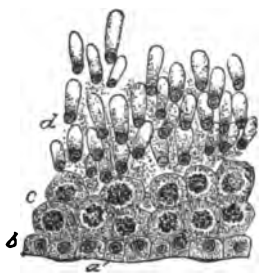

Section of testicle of musk-rat, exhibiting early stage of spermatogenesis: *a*, membrana propria; *b*, zone of parietal cells; *c*, mother-cells; *d*, spermatoblasts developing into spermatozoa.

FIG. 254.

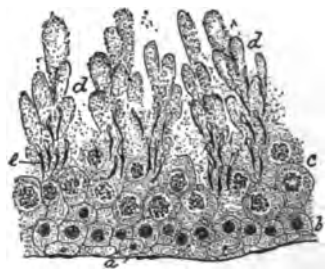

Section of testicle of musk-rat, showing later stage of spermatogenesis: *a*, membrana propria; *b*, zone of parietal cells; *c*, mother-cells; *d*, fan-shaped masses of elements concerned in producing spermatozoa (*e*).

partly the result of mechanical forces, at present are regarded as indicating an important *rôle* on the part of the **sustentacular cells** in the production of the spermatozoa, an assumption seemingly warranted by recent investigations. Coincidently with the changes in the general form of the spermatoblasts, the nuclei undergo modifications of great consequence in the development of the future spermatic elements.

The views concerning the genetic relation of the parts of the original cell to those of the resulting spermatozoon are still at variance. According to Henle, La Valette St. George, and many others, the nucleus of the daughter-cell gives rise to the head, while from the protoplasm are differentiated the middle-piece and the tail. On the other hand, Kölliker has always held, as likewise have Biondi and Niessing, that the nucleus undergoes a complicated metamorphosis, producing not only the head, but also the entire spermatozoon, the protoplasm becoming part of the granular débris in which the groups of developing spermatozoa lie embedded.

Critical study convinces that the nucleus, together with the centrosome of the spermatoblast, is the chief factor in the formation of the spermatozoon. Without attempting a detailed account of the complicated cycle, these changes may be briefly stated to consist in the increase and accumulation of the nuclear chromatin in a manner resulting in the **differentiation of the nucleus** into two zones,—an **outer,** which stains deeply and is rich in chromatin, and an **inner,** which appears clear and is devoid of chromatin. Coincidently with these changes the **nucleus escapes** from the protoplasm of the daughter-cell to take up its position, in company with other free nuclei, within the granular remains of the extruded cell-protoplasm. Subsequently the **chromatin** becomes especially condensed and accumulated at the inner border of the darker outer half of the nucleus; from this zone of chromatin a delicate **projection** or spine grows into, and, later, through, the inner clear half of the nucleus; this outgrowth is the first indication of the future tail of the spermatic element. As the result of the localization of the chromatin within the central part of the nucleus, the latter now exhibits **three** zones: an **outer clear cap** at the fore-pole, a narrow **middle zone filled with chromatin,** from which the developing tail-fibre extends, and an **inner clear area** which reaches as far as the hind-pole and is pierced by the tail. In these three nuclear zones the divisions of the future mature spermatozoon are indicated: the outer clear cap becomes the homogeneous head, the middle chromatin band produces the tail and the middle-piece,

FIG. 255.

Section of testicle of musk-rat, displaying still later stage of spermatogenesis: spermatozoa are now well advanced and form radially-arranged masses (*d*); other letters as in preceding figures.

FIG. 256.

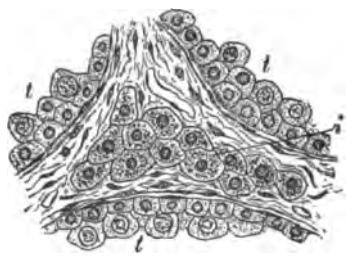

Section of human testicle, including parts of three tubules (*t*) and intervening connective tissue; within the latter lies a group of interstitial cells (*i*).

and the inner clear zone forms the delicate hyaline envelope investing the middle-piece and the tail.

Embedded within the loosely laminated intertubular connective tissue, groups of polyhedral nucleated cells occur in greater or less profusion; these **interstitial cells** are present within the testicle of man and of mammals generally. But within the interstitial tissue of the boar's testicle they are found in remarkable abundance. The elements, evidently epithelial in nature, are arranged in groups or cylinders in the interstices between the seminiferous tubules, and represent the remains of the epithelial structures of the fœtal Wolffian body.

With the termination of the convoluted division of the seminiferous tubules the secreting tissue of the gland ends, since the continuation of the seminal canals, effected by the straight tubes and those forming the rete testis, represents the beginning of the elaborate system of **excretory ducts** extending from the testicle to the urethra.

On arriving at the **straight canals** the seminiferous tubules become reduced in size (20–30 μ), as well as in number, the thick epithelial lining of the convoluted division being replaced by a single layer of **low columnar cells.** The short narrow **tubuli recti** occupy the apices of the pyramidal lobules, and enter the mediastinum, where they open into the irregular canals of the rete testis. The latter vary in size from mere clefts to channels approaching in diameter that of the convoluted tubules; they are lined by a single layer of **flattened epithelial plates.**

FIG. 257.

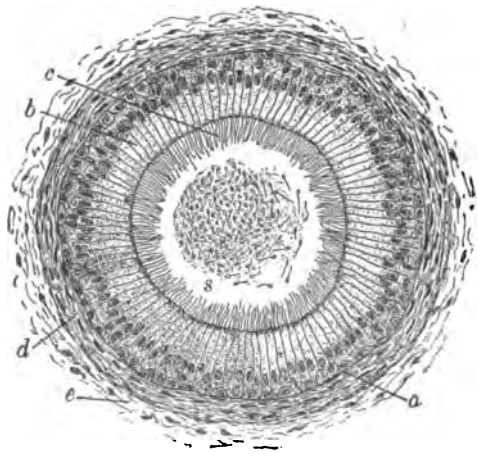

Section of tubule of human epididymis: *a*, membrana propria; *b*, columnar cells crowned with zone of long cilia (*c*); *d*, layer of non-striped muscle; *e*, intertubular areolar tissue; *s*, masses of spermatozoa occupying lumen of tube.

Beginning at the upper end of the rete testis, the further course of the seminal canal is effected by the ten to fifteen **vasa efferentia,** which, by their progressively increasing convolutions, form as many conical lobules, the **coni vasculosi,** the aggregate of which makes the **globus major**

of the epididymis. The vasa efferentia and coni vasculosi possess a **stratified columnar epithelium,** the inner cells bearing long cilia; this epithelium rests on a robust basement-membrane, outside of which lies a fibrous coat strengthened in many places by a circular layer of involuntary muscle.

FIG. 258.

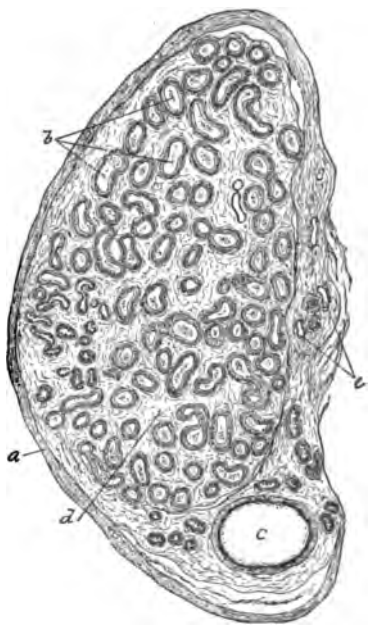

Section through lower part of epididymis of child, showing general structure: *a*, fibro-serous envelope; *b*, sections of convoluted tube of epididymis; *c*, vas deferens; *d*, intertubular tissue; *e*, blood-vessels.

The greatly convoluted **tube of the epididymis** has a similar wall, composed of **stratified ciliated columnar epithelium,** a well-marked membrana propria, augmented by fibrous tissue, and a ring of plain muscle; this muscular layer gradually thickens on approaching the vas deferens, in whose wall it becomes a tunic of considerable thickness.

The structure of the **spermatic duct,** or **vas deferens,** closely repeats the arrangement of the tube of the epididymis. A **stratified non-ciliated columnar epithelium,** separated from the tunica propria by a well-defined basement-membrane, covers the mucosa; outside of the latter lies a submucous layer of laminated connective tissue, which is embraced by the **muscular tunic,** consisting of an inner circular and an outer longitudinal layer.

The **ampulla** possesses the same coats as the vas deferens, although in the former the several layers are somewhat thinner. The **seminal vesicle,** likewise, consists of a mucous coat, lined by **stratified columnar epithelium,** a submucous and a muscular tunic. Small, often branched, **tubular glands** occur within the mucous membrane of the ampulla and the seminal vesicle. The **ejaculatory duct,** formed by the union of the vas deferens and the duct of the seminal vesicle, contains a single layer of **columnar epithelium,** supported by the fibrous tunica propria; a thin submucosa, together with a slightly developed inner circular and an outer longitudinal stratum of muscle, completes the wall of the duct.

Connected with the epididymis are certain **atrophic appendages**

which represent the remains of fœtal organs. Such structures are the **paradidymis** and the **stalked** and **sessile hydatids.**

The **paradidymis,** or the **organ of Giraldès,** consists of irregular tubules lying among the convolutions of the epididymis, which are the atrophic remains of the **tubes of the Wolffian body.** They are lined with low columnar or cuboidal epithelial cells, often ciliated, and are surrounded by an envelope of vascular connective tissue. The tubules of the paradidymis are usually closed, and frequently contain small quantities of albuminous fluid.

The **pedunculated** or **stalked hydatid,** common to both sexes, probably represents a part of the atrophied duct of the **pronephros,** the anterior segment of the Wolffian body. The **sessile** or **unstalked hydatid,** on the contrary, is limited to the male subject, and is the slightly expanded proximal end of the rudimentary **Müllerian duct.** These sacs are lined generally by cuboidal cells, and often contain a clear fluid.

The **blood-vessels** of the testicle, branches of the spermatic artery, are distributed to the mediastinum and to the loose inner layer—the **tunica vasculosa**—of the albuginea, including its prolongations, the septa. From the vessels coursing within these robust fibrous structures smaller twigs enter the connective tissue and pass between the individual tubules, around which they form rich **intertubular capillary net-works.** The corresponding **veins** accompany the arteries.

The **lymphatics** form a **superficial** capsular net-work, consisting of vessels situated within the tunica albuginea, and a **deeper** intertubular plexus, the radicles of which closely surround the seminiferous canals. The superficial and the deep lymphatics anastomose to form within the mediastinum larger vessels, which, uniting with those of the epididymis, constitute one of the elements of the spermatic cord.

Regarding the distribution of the **nerves** little is definitely known further than the penetration of bundles of mixed fibres between the seminiferous tubules, around which they form plexuses; the ultimate termination of the end-fibres is unknown.

THE SEMEN.

The **semen** as ejected consists of the secretion of the testicle diluted with that of the seminal vesicles and of the prostate gland, together with the fluid derived from Cowper's glands and the mucous membranes traversed. The **secretion proper** of the male sexual gland consists almost entirely of spermatozoa; these show active movement in the concentrated fluid within the epididymis, but after the dilution normally effected by the admixture of the secretions

mentioned, the marked vibratile movements of the seminal
s are most characteristic.

spermatozoa are minute highly-specialized elements, each
h bears at one end a long **cilium** of exceeding delicacy:
ffering greatly as to details of form and of size
vertebrated animals, the mammalian sperma-
ossess in common **three** more or less dis-
lefined parts,—the **head**, the **middle-piece**,
tail.

human spermatic filament possesses an
ngth of 50–60 μ, of which the head con-
3–5 μ, the middle-piece
hile the remaining 43–49 μ
o the tail.

ead varies in form accord-
he side examined; when
its broadest surface it is
ped, the broader end of
l being directed anteriorly,
: smaller end being con-
with the middle-piece.
profile, the head is con-
ıvex, and terminates in a
unded anterior extremity.

FIG. 259.
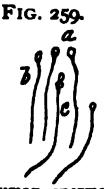
Human spermatozoa as usually seen: *a*, from the broader surface; *b*, from the side; *c*, element with remains of spermatoblast adhering to middle-piece.

FIG. 260.

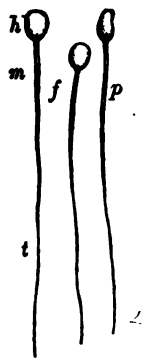

Human spermatozoa highly magnified: *h*, *m*, *t*, respectively head, middle-piece, and tail; *f*, elements seen from the broader surface; *p*, from the side.

atly diminished **middle-piece** is connected with the posterior
the head, and on the other hand fades away into the long
caudal filament. After the action of certain reagents the
ɔiece splits up into a number of fibrillæ of great tenuity (Bal-
in spermatozoa not entirely matured spiral fibrils are some-
ɔserved in this part of the element. The centre of the sper-
ament is occupied by the delicate **axial fibre,** which connects
l with the middle-piece and extends through the middle-piece
tail. Immediately behind the head, at the beginning of the
re, lies a minute nodule, the **end-knob**; this body probably
ıts the equivalent of the centrosome of the spermatoblast.
the middle-piece the axial fibre is ensheathed by a delicate
ɔe.

haracteristic **vibrations** of the spermatic filaments may con-
r a long time after ejaculation: when suitably prepared, and
vorable conditions, these cells retain their vitality for many
ıd even days. Human spermatozoa, mounted under cover-
and protected from evaporation, have been observed by the
o exhibit distinct vibratile motion after the lapse of over nine
After death these elements may continue to vibrate for forty-

eight hours, or longer, within the fluids of the seminal tract. Cells capable of such tenacious vitality even under the less favorable conditions outside the body, exhibit still greater endurance when aided by the favorable conditions for prolonged life afforded by the normal female generative tract; in these organs the spermatozoa no doubt often retain their powers of fecundation for weeks.

These elements successfully resist the destructive action of ordinary reagents, as well as putrefactive changes; this capability is owing, probably, to the union of the albuminous with the calcareous matters, which latter the spermatozoa contain in large quantity.

The seminal fluid as ejaculated contains several constituents recognizable by microscopical examination. In addition to the spermatozoa there are usually seen spherical or cylindrical masses consisting of a clear, hyaline, glassy substance derived from the seminal vesicles; numerous small, pale, delicate granules of an albuminous nature; a few round or oval nucleated cells, whose finely granular protoplasm often contains fat-granules; cylindrical epithelial cells, and the characteristic **prostatic concretions** or amyloid bodies, which are yellowish in color, spherical or triangular in form, and concentrically striated. These concretions appear to be composed of an albuminous substance in combination with a second which corresponds to lecithin (Fürbringer, Posner).

On standing for twenty-four hours the semen separates into an upper clear fluid and a thicker, opaque lower stratum; the former contains few morphological elements, while in the lower layer these are very abundant. Subsequently, after prolonged standing, two varieties of **crystals** are frequently encountered, those composed of ammonio-magnesium phosphate and the so-called **spermatic crystals.** According to Fürbringer, the latter are formed probably by the action of the semen on the prostatic secretion: since these crystals are found almost constantly, after death, in the fluid of the prostate, and not within the contents of the seminal vesicles, they are more appropriately termed **prostatic crystals.** They occur usually as prisms or pyramids, colorless, or of a slight amber tint, and break readily on slight pressure.

THE PENIS.

The penis consists of three somewhat flattened cylindrical masses of erectile tissue, the **corpora cavernosa** and the **corpus spongiosum,** capped by the conical **glans,** all of which are held together by connective tissue and enveloped by the skin and subcutaneous tissue.

The two **cavernous bodies** are enclosed within a stout fibrous envelope, the **tunica albuginea,** which reaches a thickness of about

1 mm., and is composed of closely interwoven longitudinal bundles of white fibrous tissue, intermingled with well-developed elastic fibres. Within this common investment each body is surrounded by an **individual sheath** of circularly-disposed bundles, which, in the mid-line, takes part in forming the pectinate septum; in other places the sheaths contribute the trabeculæ belonging to the enclosed erectile tissue.

FIG. 261.

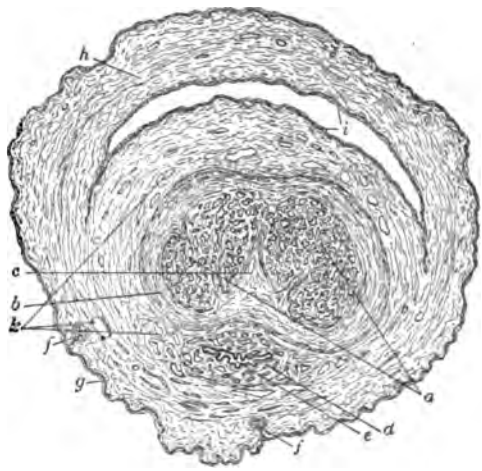

Section of penis of child near end: *a*, corpora cavernosa; *b*, fibrous envelope of same; *c*, imperfect septum; *d*, corpus spongiosum; *e*, urethra; *f*, sebaceous glands; *g*, epithelium of skin; *i*, that lining the sac of prepuce; *h*, section of latter; *k*, blood-vessels.

The **trabeculæ** spring from all parts of the investing fibrous tunics, including the septum, and pass inward, joining with their fellows on all sides to form a framework, the basis of the cavernous tissue, which occupies the entire cavernous body. While the trabeculæ are stouter and larger near the periphery than in the centre, the included spaces, on the contrary, are larger near the middle and smaller at the circumference of the cavernous bodies; towards the anterior end of the penis the spaces become generally larger. In addition to the white fibrous tissue composing their principal part, the trabeculæ contain elastic fibres and unstriped muscles, together with the blood-vessels which the larger bands support. The interspaces of this spongy structure are **cavernous venous channels**, which form an intercommunicating system of canals throughout the cavernous body. These spaces, lined with endothelium, and communicating on the one hand with the arteries and on the other with

FIG. 262.

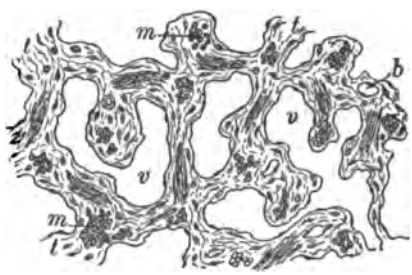

Section of erectile tissue of human penis: *v*, blood-spaces lined with endothelium; *t*, fibrous trabeculæ containing bundles of non-striped muscle (*m*) cut in various directions; *b*, blood-vessels.

the veins, during erection become enormously distended, with a corresponding reduction in the thickness of the intervening trabeculæ.

The **corpus spongiosum** in its structure resembles closely the cavernous bodies, being limited by a fibrous tunic from which spring the trabeculæ of the cavernous tissue enclosing the venous spaces. The **fibrous envelope** is less developed than in the case of the cavernous bodies, while the proportion of elastic fibres is greater, peculiarities resulting in less unyielding rigidity in this part of the penis during erection. The fibrous **trabeculæ** of the spongy body are thinner but more uniform in diameter, and the enclosed spaces possess greater similarity in size, although somewhat smaller than the corresponding channels of the corpora cavernosa; their long axis generally coincides with that of the penis. The **erectile tissue of** the corpus spongiosum is continued into the glans, the spaces, however, becoming somewhat reduced and provided with finer trabeculæ. Immediately **around the urethra** a zone of condensed fibrous tissue intermingled with a quantity of unstriped muscle occurs, in addition to which a small amount of muscular tissue frequently exists within the fibrous tunic of the spongy body, as well as within the larger trabeculæ.

The smaller divisions of the **arteries** of the cavernous bodies, branches of the internal pudic, are supported by the larger bands of fibrous tissue; from these situations the arteries pass into the capillary vessels, which, as a rule, communicate with the blood-spaces of the erectile tissue; these spaces, in turn, are drained by the venous radicles, which empty into veins escaping at the roots of the penis or into the dorsal vein. Not all the capillaries, however, open into the cavernous spaces, since those destined for the nutrition of the tissues at once terminate in the veins, thus establishing a direct circulation, which forms the chief course of the blood during the passive condition of the penis. As a compensative provision for the great expansion of the trabeculæ during erection, the arterioles are often so long that they present marked tortuosity, sometimes protruding as twists and loops into the undistended cavernous spaces; in recognition of this peculiarity these vessels have been named the **helicine arteries.**

In addition to the usual channel of the blood into the spaces by means of the capillary vessels, a direct communication exists between the arterioles and the larger spaces at the circumference of the cavernous bodies (Langer). The arrangement of the vascular supply of the corpus spongiosium and of the glans is identical with that above described, all the blood, however, being conveyed into the spaces through the capillaries.

The masses of **erectile tissue,** enclosed within their respective

sheaths, are enveloped in the general areolar tissue supporting the larger blood-vessels, nerves, and lymphatics, the whole being covered in by the investing integument. The **skin of the penis** is attached over its body by loose subcutaneous tissue, allowing of free movement and great distention; it is distinguished by its dark color, thinness, freedom from fat, and, throughout the greater part of its extent, absence of hairs. At the margin of the prepuce the skin assumes the character of a true mucous membrane, becoming delicate, rosy, and moist; the base of the glans is generously supplied with modified sebaceous follicles, the **glands of Tyson**, sometimes called **glandulæ odoriferæ**, on account of their peculiar secretion; partially inspissated accumulations of the latter, together with abraded epithelial scales, constitute the **smegma.** Upon the glans the integument is very intimately and immovably united to the fibrous tunic of the spongy tissue, and contains large **papillæ** in which rich **vascular loops** and **special nerve-endings** are situated; the skin in this situation is free from glands.

The **lymphatics** of the penis consist of a **superficial** and a **deep set**: the former extends beneath the integument as a subcutaneous net-work, whose principal vessels accompany the larger blood-vessels in their course and terminate in the superficial inguinal glands, while the latter passes from the cavernous and spongy bodies, along with the deep veins, to the deep lymphatic glands within the pelvis. The lymphatics begin in the interfascicular clefts within the larger trabeculæ and the dense fibrous laminæ which constitute the sheaths of the erectile masses; delicate radicles continue the lymph-channels from the clefts to the larger lymphatic vessels.

The **nerves** of the penis include trunks derived both from the cerebro-spinal and from the sympathetic system, those from the latter being contributed by the hypogastric plexus; the **sympathetic fibres** are distributed entirely to the erectile tissue of the cavernous and spongy bodies. The **sensory and motor nerves** are obtained from the dorsal and superficial perineal branches of the pudic nerve, and terminate within the skin and the mucous membrane. **Special nerve-endings,** represented by numerous examples of the simple and compound **genital corpuscles,** as well as by the **corpuscles of Vater,** are found in the integument of the glans and of other parts of the penis: the structure of these peculiar bodies has been considered in Chapter VI.

THE PROSTATE GLAND.

The prostate body is a compound tubular gland. The outer surface of the organ is invested by a stout **fibrous covering,** the continuation of the contiguous fascia, beneath which lies an

inner envelope of **involuntary muscle.** From the latter **muscular septa** penetrate in all directions between the acini of glandular tissue; immediately surrounding the urethra a thick muscular layer also exists.

The **prostatic acini** may be regarded as highly developed urethral glands, which they closely resemble, opening by a dozen or more ducts on the free surface of the urethra. Of these ducts two of especial size empty on either side of the urethral crest, and, repeatedly subdividing, communicate with the numerous closely-packed acini constituting the **central lobe.** The other divisions of the gland are simpler in structure, since they contain tubular alveoli, much less closely placed, which open into a slightly wavy duct.

FIG. 263.

Section of human prostate, exhibiting general disposition of acini: *a*, fibrous envelope; *b*, groups of tubular acini; *c*, sections of prostatic ducts; *e*, interacinous fibro-muscular tissue.

The **epithelium** lining the alveoli is short columnar in character, and frequently possesses more than a single row of cells, smaller spherical or pyriform elements filling up the interstices between the outer ends of the somewhat tapering cells next the lumen. The nuclei of the epithelial elements are situated eccentrically, lying nearer the ends of the cells directed towards the basement-membrane. These cells in elderly subjects not infrequently contain pigment.

In addition to the fibrous and elastic connective tissue among the acini of the gland, bundles of **involuntary muscle** pass in all directions between the alveoli, and in many places constitute almost the entire tissue separating the adjacent acini. While present in all parts of the gland, the quantity of muscle varies in different parts of the organ; it is poorest in the central lobe, where the acini are best developed, and richest in the upper part of the posterior post-urethral division and in the extreme fore part of the organ. In the lowest part of the posterior segment the involuntary muscle is supple-

mented by connective tissue in forming the interalveolar partitions. The layer of involuntary muscle surrounding the urethra is continuous behind with the vesical sphincter, and in front with the muscular envelope of the membranous portion of the canal.

On either side of the urethral crest, which occupies the posterior surface of the prostatic portion, a depression marks the position of the **prostatic fossa,** into which open the orifices of the twelve to twenty prostatic ducts. These recesses are lined with a continuation of the **stratified squamous epithelium** which covers the adjacent urethral mucous membrane; these cells, however, are soon replaced

FIG. 264.

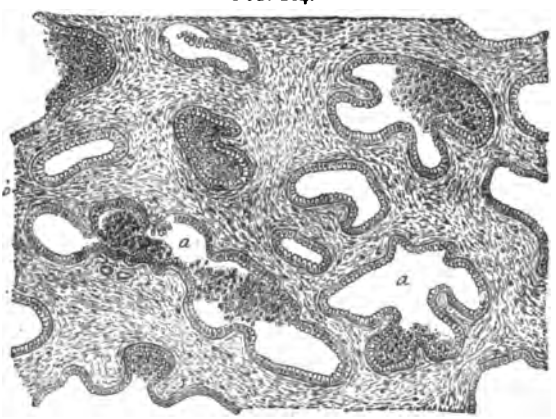

Section of human prostate more highly magnified: *a*, some of the tubular acini lined with columnar cells; *b*, muscular tissue of the intertubular septa.

within the ducts by others of the columnar type. As has already been pointed out, the **sinus pocularis,** or **uterus masculinus,** occupying the anterior part of the urethral crest, is to be regarded as homologous with the cavity of the vagina and the uterus, the layer of involuntary muscle belonging to the especial wall of the diverticulum corresponding to the uterine muscular tissue, while the small tubular glands present within the mucous membrane lining the sinus are the homologues of those of the uterus. The prostate itself, which is developed as a thickening of the urinary tract, cannot be regarded in any sense as homologous with the uterus, notwithstanding the apparently close relations with the sinus pocularis, since these relations are secondary and attained in the course of its subsequent growth.

The **blood-vessels** of the prostate gland, branches of the adjacent vesical, hemorrhoidal, and pudic arteries, pass into the interior of the organ within the larger connective-tissue septa, where they break into

smaller twigs, which follow the ducts into the lobules, the capillary vessels then forming net-works about the individual alveoli. The veins on emerging from the deeper parts of the gland form a rich plexus within the fibrous envelope about the base and sides of the organ.

The **lymphatics** originate within the connective-tissue septa as interfascicular clefts; these unite with definite channels, which, in turn, form the larger lymphatic trunks accompanying the veins in their course to the neighboring deep lymph-glands.

The **nerves**, derived principally from the hypogastric plexus, are composed of both medullated and non-medullated fibres, and pass along the stouter connective-tissue trabeculæ towards the glandular compartments; their ultimate mode of termination is still uncertain. Corpuscles of Vater have also been observed along the course of the more superficial nerve-trunks.

The **secretion** of the prostate gland—the **prostatic fluid**—is a thin, opalescent, slightly acid liquid, usually containing epithelial cells and granules. The dilution of the secretion of the testicle seems to be an important use of this fluid; and when so mixed, on standing for some time the thin rhombic prostatic or **Charcot's crystals** make their appearance.

Within the ducts or acini of the prostate gland additional small, irregularly round, laminated bodies, the **prostatic concretions**, often occur; these are constant in advanced age, but they are found often also in young subjects; these accumulations seem to be albumino-calcareous in nature and present a concentric lamination.

THE GLANDS OF COWPER.

Cowper's glands are two small racemose structures, whose rounded, somewhat flattened masses, 10–13 mm. in diameter, lie beneath the anterior part of the membranous urethra. Each gland is composed of several small lobes, which pour out their secretion through the long excretory duct into the posterior part of the bulbous portion of the urethra, where a minute orifice marks the termination of the tube. The **lobules** composing the gland are held together, as well as enveloped, by a common investment of fibrous connective tissue containing some involuntary muscle.

The **acini** are occupied by clear **low cylindrical cells**, resembling in character and in secretion those of a mucous gland. The **epithelium** lining the **small ducts**, into which the acini directly open, consists of elements cuboidal in form; these cells are gradually replaced by taller columnar ones as the urethra is approached. In addition to the epithelium and delicate connective tissue, the walls of the ducts are strengthened by bundles of unstriped muscle.

Cowper's glands secrete a **clear, viscid fluid,** regarding the use of which little is known with certainty.

The **blood-vessels** supplying Cowper's glands, derived usually as branches of the artery of the bulb, pass between the lobules, in company with the ducts, supported by the intervening connective tissue; the capillaries form net-works around the individual acini. **Lymph-spaces** occur within the fibrous envelope and within the larger masses of connective tissue penetrating the organ.

The **nerves** are branches from the pudic nerve: regarding their termination little is definitely known.

CHAPTER XIII.

THE FEMALE REPRODUCTIVE ORGANS.

THE OVARY.

THE ovary is attached to the posterior surface of the broad ligament along its shorter straight border, the sides and convex edge of its flattened oval mass being invested by the serous covering continuous with the peritoneum of the adjacent surfaces. The **serous membrane** reflected over the organ is modified both in appearance and in structure, since the usual shining smoothness of its surface is replaced by dulness, and the flat endothelial plates are supplanted

FIG. 265.

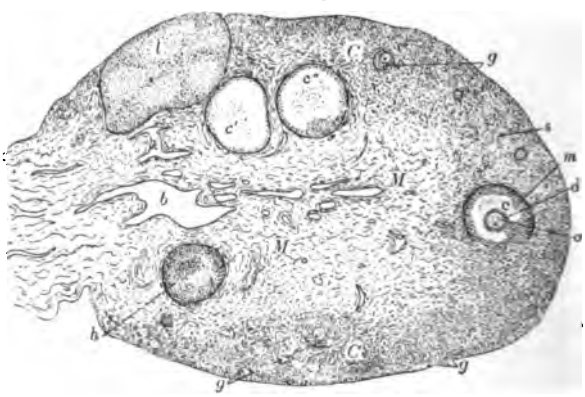

Section of ovary of cat: *C*, cortex containing peripheral zone of Graafian follicles (*g*) in various stages of development; *c*, well-advanced follicle exhibiting ovum (*o*), discus proligerus (*d*), and membrana granulosa (*m*); *c'*, *c''*, other large follicles, from which ova are absent; *h*, peripheral section of large follicle which membrana granulosa seemingly fills; *s*, ovarian stroma; *l*, corpus luteum; *M*, medulla containing many vascular channels (*b*).

by the low columnar cells which constitute the **germinal epithelium**. The transition of the latter into the usual peritoneal covering is indicated by a distinct demarcation around the attachment of the ovary.

The ovary is divided into two parts, the **cortex** and the **medulla**, the boundaries of which are somewhat conventional and by no means sharply defined. The **cortex** includes the peripheral zone, containing the Graafian follicles and the ova, and occupies approximately the outer third of the organ, while the **medulla** embraces the re-

maining central portions of the ovary, in which the blood-vessels are conspicuous constituents.

The bulk of the organ consists principally of the **stroma**, together with the contained blood-vessels and the Graafian follicles.

The **ovarian stroma** is a peculiar form of connective tissue distinguished by the great number of its spindle-cells, which, while distributed through all parts of the organ, are especially closely packed in the cortex, particularly near the periphery.

The cortical stroma, arranged in variously-directed bundles, is greatly condensed immediately beneath the germinal epithelium, the zone of condensed tissue appearing as a distinct peripheral layer, the so-called **tunica albuginea**; the latter, however, does not represent an independent structure, as does the sheath bearing the same name in the testicle, but only a peripheral band of the stroma of especial density.

FIG. 266.

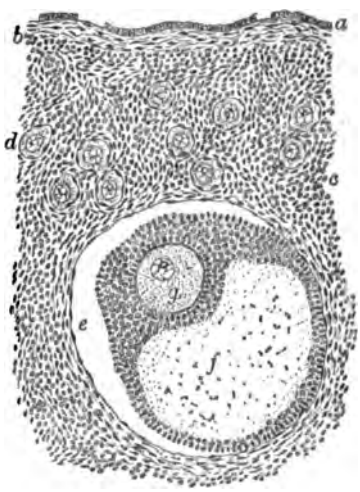

Section of human ovary, including cortex: *a*, germinal epithelium of free surface; *b*, tunica albuginea; *c*, peripheral stroma containing immature Graafian follicles (*d*); *e*, well-advanced follicle from whose wall membrana granulosa has partially separated; *f*, cavity of liquor folliculi; *g*, ovum surrounded by cell-mass constituting discus proligerus.

The most important constituents of the cortex are the **Graafian follicles**, which are exclusively limited to this part of the ovary, where they occur in all stages of development. The youngest and least matured Graafian follicles are plentifully scattered through the outer part of the cortex, where in many animals, as the cat and the rabbit, they form almost a complete zone. The most **immature follicle** consists of the ovum surrounded by a single layer of flattened cells, the progenitors of the membrana granulosa, outside of which lie the cells of the general stroma, without the intervention of a special limiting membrane. Among the immature follicles are others in various stages of more advanced development, in which the ovum is embraced by two or more rows of polygonal cells; around such ova the stroma is concentrically disposed, a condition foreshadowing the membrana granulosa and the theca of later stages. The cells which surround the ovum by their division give rise to the numerous elements lining the follicle; they were originally derived from the **germinal epithelium**

as cylindrical masses which penetrate the stroma and undergo proliferation. With the increase in size which accompanies their development the Graafian follicles pass towards the inner limits of the cortex bordering on the medulla, where they undergo further enlargement; after a time their diameter includes almost the entire cortex, and extends from the medulla to the surface of the ovary. Subsequently the position of the follicle becomes evident as a distinct **projection on the free surface,** marking the point at which the final rupture of the sac and the escape of the ovum take place. Such discharge usually coincides with the phenomena attending menstruation.

FIG. 267.

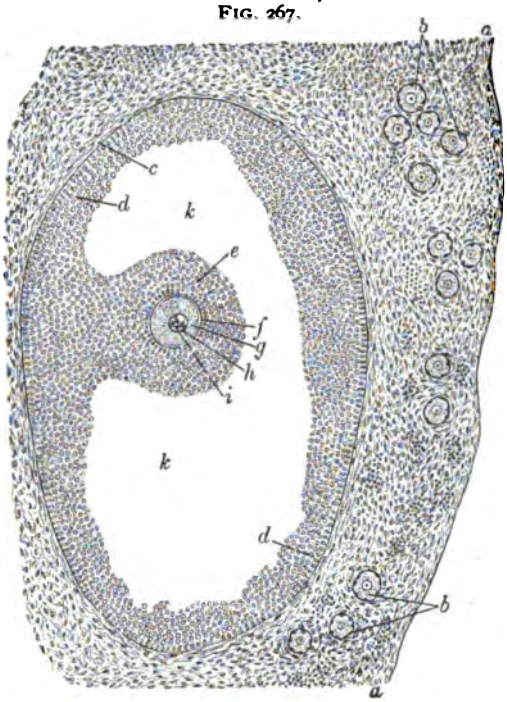

Section of cortex of cat's ovary, exhibiting large Graafian follicle: *a*, peripheral zone of condensed stroma; *b*, groups of immature follicles; *c*, theca of follicle; *d*, membrana granulosa; *e*, discus proligerus; *f*, zona pellucida; *g*, vitellus; *h*, germinal vesicle; *i*, germinal spot; *k*, cavity of liquor folliculi.

The **mature Graafian follicles** appear as clear vesicles, 4–8 mm. in diameter, and, on section, exhibit a characteristic arrangement. The follicle is defined from the surrounding tissue by a condensed layer of stroma, which forms a sheath, the **theca folliculi**; this envelope is composed of two layers, an outer **tunica fibrosa,** containing fibrous connective tissue and coarser blood-vessels, and an inner **tunica propria,** rich in cells, small blood-vessels, and capillaries. Within the theca follows the **membrana granulosa,** consisting of many layers of small polyhedral epithelial cells, the descendants of the single row of original cells contained within the young follicle; at one point the membrana granulosa presents a thickening, which is continued as a zone of cells immediately surrounding the ovum; this constitutes the **discus proligerus,** which remains in contact with the ovum after its escape. The cells of the discus which lie next the ovum are placed vertically

to its surface, forming a radial zone, the **corona radiata.** The interior of the follicle is occupied by an albuminous fluid, the **liquor folliculi,** derived probably as an exudate from the blood-vessels of the theca, as well as from the breaking down of some of the central cells of the follicle.

Within the discus proligerus lies the **ovum,** a spherical body about .2 mm. in diameter, enclosed within a distinct membrane, the **zona pellucida,** which presents a delicate radial striation. These markings are regarded by many as due to the presence of fine canals, which may facilitate the access of fluids and possibly, also, of the spermatozoa to the contained cell. The **zona pellucida** is a protecting membrane, derived from the cells of the surrounding discus proligerus, and does not, strictly considered, constitute a part of the ovum proper, since it lies outside of the true cell-wall, the **vitelline membrane.**

FIG. 268.

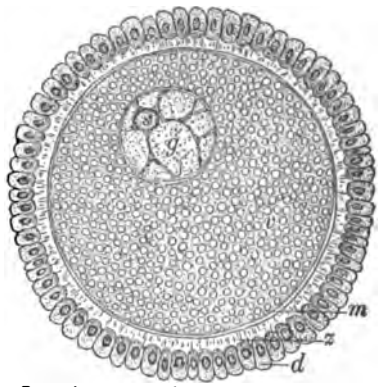

Ovum from ovary of cat: *d*, innermost cells of discus proligerus, between which processes from zona pellucida (*z*) extend; *m*, vitelline membrane; *v*, vitellus; *g*, germinal vesicle; *s*, germinal spot.

The protoplasm of the ovum, or **vitellus,** occupies almost the entire area within the zona pellucida, and is limited by the delicate and inconspicuous vitelline membrane, which closely approximates the inner surface of the zona pellucida. The **protoplasm** of the ovum is modified by the presence of numberless particles of fatty matter which lie embedded within the albuminous protoplasm proper. The **germinal vesicle,** corresponding to the **nucleus** of the ovum, is situated eccentrically, limited by a distinct membrane, and contains the **germinal spot** or **nucleolus.** Of the parts of the ovum, the germinal vesicle is the most important, since in it, as in the nucleus of cells in general, are inaugurated the important changes attendant upon the phenomena of cell division. The threads of **chromatin** form a loose, irregular net-work throughout the germinal vesicle, the interspaces of which are filled with a substance representing the **nuclear juice.** While each Graafian follicle contains, as a rule, but a single ovum, exceptions are observed occasionally where two, and even three, ova are found within the same vesicle.

The formation of **new follicles** continues for only a short time after birth; ovisacs are then most numerous, the entire number contained within the two ovaries of the child being estimated at over

seventy thousand. In view of the unquestionably large number of follicles in very young ovaries, and the relatively small proportion of ova which reach maturity, the **degeneration of many follicles,** after attaining a certain development, seems certain; the atrophic remains of such degenerating Graafian vesicles, continually encountered, point conclusively to the fate of a large contingent.

The **medulla** contrasts with the cortex by its looser structure and the number and the size of its vascular canals. The stroma of this portion of the ovary more nearly resembles ordinary connective tissue, the peculiar spindle-cells occurring much less abundantly, while the fibrous tissue forms an important constituent of the supporting matrix. A considerable amount of **involuntary muscle** is mixed throughout the fibrous bundles separating and surrounding the numerous blood-vessels. The latter are largely venous, the large **sinus-like veins** being very conspicuous objects in the medulla.

FIG. 269.

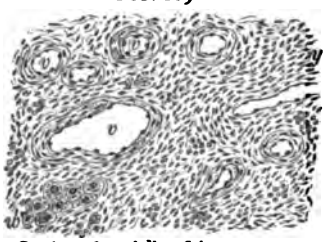

Section of medulla of human ovary: *v*, vascular canals surrounded by the stroma-cells and the connective tissue; *w*, group of interstitial cells derived from Wolffian tubules.

In addition to the elements already described, groups of polygonal **interstitial cells** occur between the bundles of stroma-tissue, especially in the medulla, but also within the cortex. These cells are epithelial in character, and represent the remains of the cylindrical cell-masses which grow from the **Wolffian body** into the tissue of the primitive ovary. In some animals the interstitial cells are much more numerous than in the human ovary; in the rabbit these cells constitute an important part of the stroma of the organ.

On the **escape of the ovum,** the ruptured and partly-collapsed follicle becomes filled with the blood poured out from the torn vessels of the walls of the vesicle; subsequent changes lead to the conversion of the follicle into a **corpus luteum.** The production of these characteristic bodies depends principally upon the proliferation of the walls of the follicle, in some cases the interstitial cells being involved; the process results in the plication of the remains of the envelope, as well as in the gradual formation of a mass of **polyhedral cells,** between which the capillaries derived from the vessels of the follicle extend; the enclosed area corresponds to the remains of the cavity of the follicle, and is for a time occupied with the yellowish mass composed of the degenerating blood-clot and the membrana granulosa; these tissues are replaced by a shrunken fibrous area, which is later invaded by the proliferating peripheral cells. When

best developed, the corpus luteum is sharply defined from the surrounding stroma, and in appearance recalls somewhat the liver, the polygonal cells being surrounded by capillary blood-vessels. Subsequent changes lead to retrogression and disappearance of the cells, the entire mass becoming fibrous and cicatricial in character, but remaining visible for many months as an obscure, shrunken, irregularly-plicated body in the midst of the cortical tissues. While the formation of a corpus luteum follows the discharge of every mature ovum, when such escape is followed by pregnancy the yellow body becomes exceptionally large and well developed, presenting a large round mass, 2–3 cm. in diameter, which retains its distinctive character much more tenaciously than the corpus of ordinary menstruation. These differences led to the distinction of the **corpus luteum of pregnancy** as the **true** yellow body as contrasted with the ordinary or false; the former large symmetrically-developed body has been regarded as positive proof of pregnancy, a conclusion, however, which the repeated observation of identical bodies in the ovaries of virgins by no means upholds: the evidence afforded by such corpora lutea should be regarded as corroborative rather than as positive.

FIG. 270.

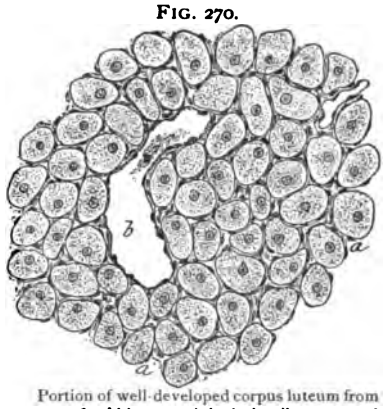

Portion of well-developed corpus luteum from ovary of rabbit: *a*, polyhedral cells separated by vascular connective tissue; *b*, blood-vessel.

The **blood-vessels** of the ovary enter at the hilus along the attached border. They directly penetrate to the medulla, smaller twigs passing to supply the cortex and the Graafian vesicles. Each of these sacs is surrounded by a net-work of vessels, especially conspicuous in the larger follicles. The venous vessels within the medulla are of large size, the channels resembling **sinuses** in their tortuous course and thin walls.

The **lymphatics** are numerous within the medulla, while their terminal radicles have been traced within the cortex to the cleft-like spaces within the fibrous tunic of the walls of the larger follicles.

The **nerves** of the ovary include medullated and pale fibres, representing both the cerebro-spinal and the sympathetic system. After passing into the interior of the organ, fine twigs enter the cortex, where they have been traced into the envelope of the larger Graafian follicles.

THE PAROVARIUM.

The **parovarium**, the **epoöphoron**, or the **organ of Rosenmüller**, consists of a group of tubular structures lying transversely within the broad ligament, between the ovary and the oviduct; the short **vertical tubules** lie irregularly parallel or converge somewhat at their ovarian ends, while their opposite extremities are connected with a longitudinal **head-tube** of larger diameter, which extends downward often for some distance within the broad ligament. The tubules are lined by **low columnar epithelial cells**, the representatives of the elements clothing the embryonic canals. The parovarium represents the partially-obliterated **remains of parts of the Wolffian body**; the transverse canals correspond to the tubules of the body, while the head-tube is identical with the upper part of the Wolffian duct; when this latter canal persists throughout the greater part of its original extent it constitutes **Gartner's duct**, the homologue of the vas deferens. Other **fœtal remains** are sometimes encountered, as **rudimentary tubules** embedded within the broad ligament nearer the uterus than the parovarium; these structures constitute the **paroöphoron**, and represent the atrophic transverse tubules of the lower portion of the Wolffian body, being homologous with the paradidymis in the male. The closed **tubules** of the paroöphoron are lined by **low columnar epithelium**, and are often occluded by the partially-shed cells.

FIG. 271.



Portion of tubules of parovarium: *w*, canals lined with cuboidal epithelium embedded within surrounding connective tissue (*s*).

The **stalked hydatid** of Morgagni frequently forms a conspicuous appendage to the ovary. This pedunculated vesicle represents the remains of the duct of the pronephros, and is common to both sexes; low columnar or **cuboidal epithelium** forms the lining of its dilated sac and stalk as far as pervious.

THE OVIDUCT.

The **oviduct**, or **Fallopian tube**, consists of three coats,—an inner **mucous**, a middle **muscular**, and an outer **serous**.

The **mucous membrane** of the oviduct is thrown into **longitudinal folds**, which correspond in their amplitude to the general variation in the size of the tube, being low towards the small uterine end and increasing in height and in complexity on approaching the expanded fimbriated extremity of the canal. On transverse section through the smaller portions of the tube, the longitudinal folds give to the lumen a generally stellate outline, the complexity of the figure

increasing as the sections approach the fimbria, owing to the addition of numerous secondary plications which there exist. The mucous membrane of the oviduct consists of a fibro-elastic **tunica propria** and a single layer of **columnar ciliated epithelial** cells, whose ciliary wave sweeps from the fimbria towards the uterine end of the tube. All parts of the canal are lined with ciliated cells, including the inner surface of its expanded ovarian end; at the free edge of the latter the ciliated columnar cells of the tubal surface are replaced by the flat endothelial plates of the peritoneum which invests the outer aspect of the tube.

FIG. 272.

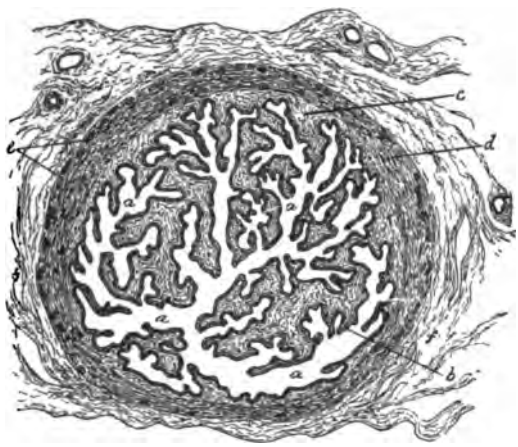

Section of human oviduct near fimbria; *a*, lumen of tube encroached upon by complicated folds; *b*, layer of ciliated columnar epithelium; *c*, fibrous tissue supporting plications; *d*, circular layer of muscle; *e*, longitudinal bundles of muscle-cells; *f*, external fibrous tissue.

The outer layers of the tubal mucous membrane contain scattered longitudinal bundles of **involuntary muscle,** which represent a poorly-developed muscularis mucosæ; outside these a thin layer of fibrous connective tissue answers to a **submucosa,** and contains the larger blood-vessels and the lymphatics. **Glands are absent** within the mucous membrane of the oviduct.

The **muscular tunic** consists of a principal **inner circular layer** of non-striped muscle and a slightly developed **outer** layer consisting of an incomplete zone of **longitudinal bundles.**

The **serous coat** consists of the fibro-elastic stroma and the endothelial plates of the general peritoneum.

The **blood-vessels** of the oviduct are branches from the ovarian and uterine arteries and the corresponding veins; the arteries possess a tortuous course and extend along the bases of the folds of the mucosa; from these vessels smaller twigs arise, which break up into the capillary net-works destined for the various coats.

The larger **lymphatics** accompany the blood-vessels and communicate with the lymph-spaces within the deeper layers of the mucosa.

The **nerves,** derived from the ovarian and uterine plexuses, con-

sist of both medullated and pale fibres; the principal trunks run in company with the blood-vessels as far as the mucous membrane; their ultimate distribution and mode of termination are still uncertain.

THE UTERUS.

The uterus being the fused morphological continuations of the oviducts, similarity approaching identity in the structure of the two segments of the original tube is to be expected; this resemblance, in

FIG. 273.

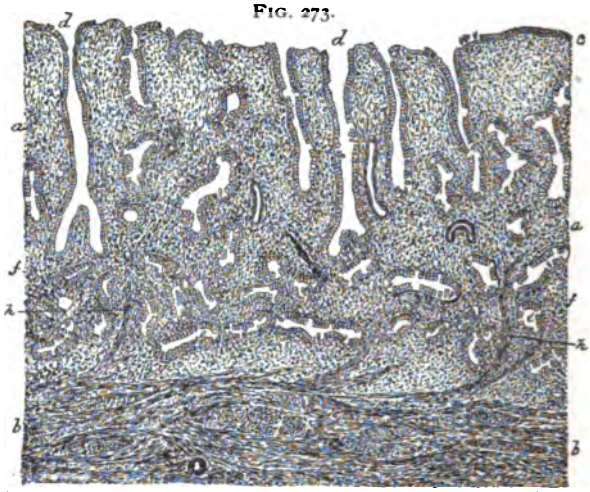

Section of human uterus, including mucosa (*a*) and adjacent muscular tissue (*b*); *c*, epithelium of free surface and tubular uterine glands (*d*); *f*, deepest layer of mucosa, containing fundi of glands; *h*, strands of non-striped muscle penetrating within the mucosa.

fact, exists. The uterus is composed of a **mucous**, a **muscular**, and a **serous coat**, modified to meet the demands of special functions.

The **mucosa**, 1–2 mm. in thickness, consists of a **tunica propria** formed of delicate bundles of fibrous tissue, intermingled with some elastic fibres and many leucocytes, and the **epithelium.** The latter is a single layer of **ciliated columnar cells**, whose ciliary current is directed towards the cervix. The tunica propria contains numerous slightly wavy tubular **uterine glands**, limited by a delicate basement-membrane and lined by an extension of the ciliated columnar epithelium of the adjacent mucous surface. Since a submucosa is wanting in the uterine wall, the blind and often forked extremities of the glands abut directly upon the muscular tissue.

The **mucosa of the uterine cervix** differs materially from that of the body of the organ, being thicker and firmer, and within the lower third beset with minute **papillæ** covered with **stratified squamous epithelium.** In the upper half or two-thirds of the cervix

the epithelium is ciliated columnar, similar to that of the body of the organ. In addition to the scattered tubular follicles, the representatives of the usual uterine glands, numerous short **mucous crypts,** with expanded blind extremities, lie embedded within the mucosa; these pour out the thick glairy mucous secretion which is characteristic of the glands of the cervix. Not infrequently retention of the secretion takes place in some of these mucous follicles, the glands then undergoing transformation into greatly-distended cysts, the **ovula Nabothi;** these appear as translucent yellowish vesicles embedded within the mucosa and readily seen by the unaided eye. In

FIG. 274.

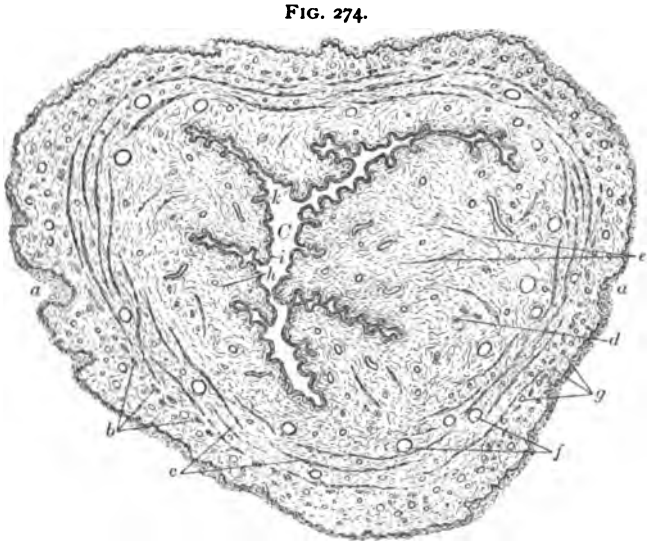

Section of uterus through lower segment of cervix from child: *a*, vaginal surface covered with squamous epithelium; *b*, *c*, *d*, *e*, variously-disposed bundles of non-striped muscle; *f*, *g*, blood-vessels; *h*, fibrous tunica propria covered by columnar epithelium (*i*); *k*, folds of mucosa projecting within lumen of canal (*C*).

the absence of glands the mucous membrane of the lowest part of the cervix still further resembles that of the adjacent vaginal surface. The **exterior** of the projecting portion of the cervix is covered with an extension of the vaginal mucous membrane. With the recurrence of each **menstrual period** the uterine mucous membrane undergoes changes destined to prepare this surface as a favorable place for the reception and retention of the ovum during gestation in the event of impregnation. Greatly-increased vascularity, softening and thickening of the mucous membrane, with increase in the length of the glands and in the number of the leucocytes, are among the changes then taking place. Should impregnation occur, these altera-

tions become more pronounced and result in the formation of the **decidua.** When incidental merely to the phenomena of menstruation, the flow of blood following the rupture of the over-distended capillaries is accompanied, possibly, by a very slight degeneration of the innermost portions of the uterine mucous membrane. There is little evidence that the profound changes involving the uterine glands and mucosa, formerly described, actually take place. Diapedesis is the most important change.

The **muscular coat** of the uterus consists of bundles of involuntary muscle separated by bands of connective tissue and surrounding numerous vascular, especially venous, channels. While more or less irregularly arranged, the muscular tissue is disposed in three general strata, an **inner,** a **middle,** and an **outer layer.** The **inner layer,** upon which directly rests the mucosa, is often regarded as belonging to the mucous membrane, being in fact the **hypertrophied muscularis mucosæ**; it is composed principally of irregular longitudinal or oblique bundles, and contributes about 1.5 mm. of the entire muscular tunic. The **middle layer** is the most robust, forming the greater part of the muscular wall, consisting chiefly of bundles having a general circular disposition. This layer is also distinguished by the numerous **large venous channels** enclosed between its bundles; hence the name, **stratum vasculare.** The **outer layer** of muscle, about .1 mm. in thickness, is made up partly of circular and partly of longitudinal bundles, the latter predominating and being closely related to the overlying serous coat. Many bundles of this outer layer pass obliquely across the fundus and into the broad ligament; some of these enter the round ligaments and accompany the areolar tissue and the blood-vessels composing these structures towards the groin, while others extend along the oviducts; strong muscular bands also run from the uterus into the ovarian ligaments. The **musculature of the cervix** is characterized by greater regularity in its arrangement, a distinct inner longitudinal, a middle circular, and an outer longitudinal layer being present. **During pregnancy** the muscular tissue of the uterus becomes enormously increased, the augmentation depending not only upon the excessive size of the already existing individual muscle-cells, but also upon the appearance of additional new muscle-cells.

The **serous coat** of the uterus is composed of the usual constituents of the peritoneum, the fibro-elastic stroma being covered by the outer sheet of endothelium.

The **blood-vessels** supplying the uterus are very numerous. The arteries, branches from the ovarian and the uterine, pass beneath the serous coat into the muscular tunic, where many twigs are given off for distribution to the tissue of this layer; the capillary vessels pass

between and into the muscle-bundles supported by the intervening connective tissue; the terminal branches reach the mucosa, where they break up into capillaries, which form net-works around the uterine glands and beneath the free surface. In addition to the trunks accompanying the principal arteries, the veins contribute numerous channels to the middle muscular coat, in which they form a **plexiform system** of thin-walled sinus-like **blood-spaces** within the intermuscular connective tissue.

The **lymphatics** are represented within the uterine mucosa by a wide-meshed net-work of canals within the deeper layers of the tunic, as well as by blind, slightly club-shaped branches and the interfascicular lymph-spaces. Within the muscular tunic lymphatic channels occur among the muscle-bundles, particularly of the middle layer; these unite with the larger lymphatics lying within the subserous tissue.

The **nerves** supplying the uterus are derived from the inferior hypogastric and the ovarian plexus, together with branches from the lower sacral nerves; they consist, therefore, of both medullated and non-medullated fibres: minute **ganglia** have been observed in connection with the latter. The larger trunks send many twigs to the muscular tissue; the final termination of the branches passing into the mucosa is still undetermined.

THE VAGINA.

The walls of the vagina consist of a **mucous membrane**, a **muscular coat**, and a **fibrous adventitia**.

The **mucous membrane** is covered with a thick **stratified squamous epithelium**, which rests upon a tunica propria rich in elastic fibres and leucocytes and beset with numerous **papillæ**; the latter, when small, do not impress the free surface, the epithelium presenting an uninterrupted plane. Larger elevations, however, occur as the prominent folds constituting the **rugæ**, which include within their structure not only the tissues of the mucosa but also bundles of **involuntary muscle** and numerous **large veins**, these latter bestowing upon the parts somewhat the character of cavernous tissue. **Leucocytes** are plentifully scattered within the mucosa of the entire vaginal tract, but in certain places, particularly in the anterior wall near the orifice of the vagina, these cells are very numerous, and give the mucosa the **appearance of adenoid tissue**; solitary lymph-follicles also exist. **True glands** are not found in the vaginal mucous membrane; the watery acid secretion bathing its surface seems to be the product of the general mucosa. The **hymen** consists of a crescentic or circular duplicature of the mucous membrane strengthened by an intervening layer of fibrous tissue.

The deepest part of the mucosa is continuous with the loosely-woven, highly-vascular **submucous tissue**; outside the latter follows the **muscular tunic**, composed of an inner circular and an outer longitudinal stratum of involuntary muscle. These layers are not sharply defined, but are blended with one another by numerous oblique bundles. The outer **adventitious coat** consists of a dense fibrous tunic, rich in elastic tissue, which contributes greatly to the strength of the vaginal walls: this fibrous coat is best developed in the anterior wall of the canal, where it closely unites the vagina to the bladder, and encloses within its firm, compact mass the urethra.

The **blood-vessels** of the vagina are very numerous; the larger twigs break up within the submucous tissue into smaller vessels, which pass to supply the muscular coat and the mucous membrane. Those entering the latter terminate in capillary loops lying beneath the epithelium and within the papillæ. The veins correspond with the larger arteries, but, in addition, form dense **plexiform net-works** beneath the serous coat. Around the entrance of the vagina the number and size of the venous channels give the submucous coat the character of cavernous tissue.

The **lymphatics** form net-works within the mucosa and muscularis, which unite with the larger lymph-channels within the adventitia.

The **nerves** supplying the vagina, derived from the hypogastric plexus and from the sacral and pudic nerves, consist of both pale and medullated fibres. Numerous microscopic ganglia occur in connection with the sympathetic fibres. Special **end-bulbs**, or the **genital corpuscles of Krause**, exist within the vaginal mucosa.

THE GENITALIA.

The **labia majora** consist of the folded integument enclosing an abundance of adipose tissue, together with blood-vessels, nerves, glands, and bundles of involuntary muscle; their **outer surface** corresponds to the usual integument of the vicinity, while internally the delicate skin resembles somewhat in appearance a mucous membrane. The **median surfaces** of the labia contain little fat, but, on the other hand, many bundles of elastic and unstriped muscular tissue. **Sebaceous follicles** and **sweat-glands** are numerous, but they are more plentiful on the outer than on the inner surface of the labia. Owing to the unusual quantity of **pigment** contained within the deeper layers of the epithelium, the labial integument is especially dark.

The **labia minora**, or **nymphæ**, include between their folds of delicate skin vascular areolar tissue; their external surfaces resemble closely in appearance the adjoining integument of the external labia, with which they are continuous. **Vascular**

papillæ and well-developed **sebaceous follicles** are common to both surfaces of the nymphæ, but sweat-glands, hairs, and fat are wanting. The interior of the nymphæ contains **venous spaces** in abundance, which, in connection with the unstriped muscle also present, produce a layer resembling **erectile tissue.** The **blood-vessels** of the labia majora are similar to those supplying the integument; in the nymphæ the mucous surfaces are beset with vascular papillæ, which contain the terminal capillary loops.

The **lymphatics** consist of the interfibrillar lymph-clefts and the more definite channels which are present as small lymphatic vessels accompanying the larger blood-vessels from the areolar tissue.

The **nerves** of the nymphæ, derived from branches supplying the lower part of the vagina, include both medullated and pale fibres: numerous special end-bulbs, the **genital corpuscles of Krause,** represent the particular terminations.

The **clitoris** largely repeats the structure of the corresponding male organ, subject, however, to the modifications incident to the feebler development of the parts. The **glans** possesses small and large papillæ, which contain simple and compound arterial tufts, while some of the smaller elevations are occupied by the peculiar nervous end-bulbs or the **genital corpuscles. Sebaceous follicles** also surround the glans and are present in the outer layer of the prepuce; on the glans itself they are almost wanting. The **erectile tissue** constituting the diminutive corpora cavernosa and the glans consists of the same elements as the corresponding structures of the penis.

The mucous membrane lining the **vestibule,** continuous with the skin covering the inner surface of the nymphæ, passes inward into the vagina and the urethra. A thick layer of **stratified squamous epithelium** rests upon a tunica propria containing bundles of elastic tissue, and many **mucous follicles,** the latter being especially abundant in the vicinity of the urethral orifice. The submucous tissue around the vestibule and base of the nymphæ is so generously supplied with intercommunicating **venous channels** that in many places the part assumes the characters of erectile tissue.

The **glands of Bartholin** are two round or oval yellowish bodies, about 1 cm. in diameter, lying on either side of the lower part of the vagina. These structures are the homologues of Cowper's glands in the male; they are **racemose glands,** composed of small groups of acini lined with clear **mucous cells.** Each gland is connected with the inner surface of the nymphæ by a long slender **duct** lined with low **cuboidal epithelium.** The character of the secretion of these glands is muco-serous.

The **female urethra** differs from the canal in the male in being

short, very dilatable, and of large size. Its walls consist of a **mucosa,** composed of fibrous tissue intermingled with many elastic fibres and containing large numbers of leucocytes, and an **epithelium** of the **stratified squamous** variety, continuous with the transitional epithelium of the bladder on the one hand and with the epithelium of the vestibule on the other. The mucous membrane of the urethra presents longitudinal folds, especially on the posterior wall, and contains many **tubular mucous glands;** several of these, near the urethral orifice, are of large size. Near the vestibular end of the canal on either side are found the rudimentary **paraurethral ducts** or **tubes of Skene.** Outside the submucosa follows **involuntary muscle,** disposed as an inner thin longitudinal and an outer thick circular layer.

THE MAMMARY GLANDS.

The mammary glands are usually described in connection with the female reproductive organs, although these structures are only modified and specialized **sebaceous integumentary glands;** strictly regarded, the mammæ, therefore, belong to the consideration of the skin.

Each **mamma** consists of from fifteen to twenty distinct **tubo-racemose glands** or **lobes,** which are held together by connective tissue and united into a single hemispherical mass by adipose tissue, which fills all irregularities and interspaces between the divisions of the organ. Each **lobe,** supplied by its own **excretory duct,** is subdivided by penetrating fibrous septa into **lobules,** which, in turn, are composed of groups of individual **acini.** The histological details of the secreting portions of the organ vary with the stages of its functional activity: the following description applies to the active glands as seen during lactation.

FIG. 275.

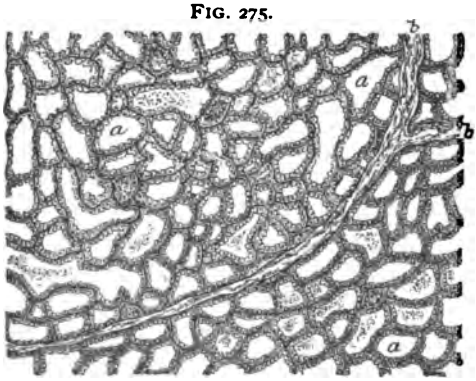

Section of human mammary gland during lactation: *a*, *a*, sections of the large tubular acini which constitute almost the entire lobule; *b*, interlobular connective-tissue septa.

The **acini,** usually tubular or saccular in form, are grouped together to constitute the lobules; limited by a distinct **membrana propria,** they are lined by a single layer of short **columnar** or **polyhedral epithelial cells,** whose protoplasm differs in appearance with the condition of secretion. **At rest,** these cells are uniformly granular; as **secre-**

tion **advances**, their granular protoplasm becomes broken up and displaced by the accumulation of oil-globules within the cell; these minute oil-drops exist at first as minute separate particles, which gradually increase in size, until finally they become confluent and form a single large globule, which occupies the greater part of the entire cell; the nucleus in consequence is displaced towards the periphery, next the basement-membrane, where it lies embedded within the thin belt of protoplasm occupying the outer zone of the cell. **During secretion** the acini possess a comparatively wide lumen, since the epithelial layer forms but a narrow lining to the irregular spherical or tubular spaces. The cells within a single acinus often contain very **unequal amounts of oil**; some of the elements are so loaded that the entire cell is occupied by the oil-drop, while, on the other hand, the neighboring cells may contain so little oil that the presence of the fatty particles is masked by the general protoplasm. Between the extremes all gradations may be found. Upon reaching a certain tension, the contained oil-globules, escaping in the direction of least resistance, are discharged into the cavity of the acinus, where they, together with the granular débris of old epithelial cells, are collected within an albuminous fluid and constitute the **lactiferous secretion**. The assumed **destruction** of the epithelial cells following the discharge of the oil-globules is improbable, since the cell then simply enters upon a period of rest and repair, during which its powers of secretion are recuperated. In the earliest stage of the activity of the mammary gland, when the flow of milk is first established, the acini, in many cases, still retain their primitive **condition of solidity**; while the cells at the periphery remain as the secreting elements, those occupying the centre of the acinus undergo fatty degeneration, some become disintegrated, while others are cast off as masses which constitute the **colostrum-corpuscles** found in the milk during the first few days.

FIG. 276.

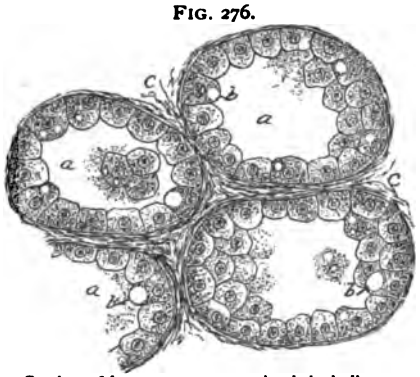

Section of human mammary gland, including several acini (*a*) engaged in sluggish secretion of milk; *b*, epithelial elements containing oil-droplets; *c*, interacinous connective tissue.

The secretion accumulated within the comparatively large alveoli is carried off by the **terminal branches of the ducts**, whose walls consist of a basement-membrane and a single layer of **low colum-**

nar or **flattened epithelium.** The large excretory ca **galactophorous ducts,** each of which collects the secret an entire lobe, pass as distinct tubes to the nipple ; they pos of considerable thickness, composed of fibrous and elastic c tissue, together with some unstriped muscle derived from th The lining **epithelial cells** are **columnar** to within a few m of the external openings of ducts, where the epithelium **stratified** and continuous with the epidermis. The fifteen t excretory ducts, after a longer or shorter course, converge the **areola,** within whose area they undergo considerable to form the **ampullæ,** which serve during lactation as te reservoirs for the milk.

The **nipple** consists, in addition to the external coverin mented and greatly wrinkled skin which is perforated at th the openings of the excretory milk-ducts, of a central mass c of the **lactiferous canals** and the blood-vessels embedde the fibro-elastic tissue. A considerable amount of **unstrip cle** exists, disposed as encircling and radiating fibres ; contraction of this muscle, which responds to mechanical the **erectility** of the nipple principally depends. The **cu papillæ** are supplied with numerous nerve-terminations, whi a high degree of sensitiveness. The **subcutaneous tissu** nipple proper no fat; aroun and over th elevations n orifices of t tered groups racemose s which consti **glands of gomery. tegument areola** sur the base of th usually posse siderable p the amount g creasing duri nancy ; large **glands** and numerous well-developed **sebaceous follicles** present within this area.

FIG. 277.

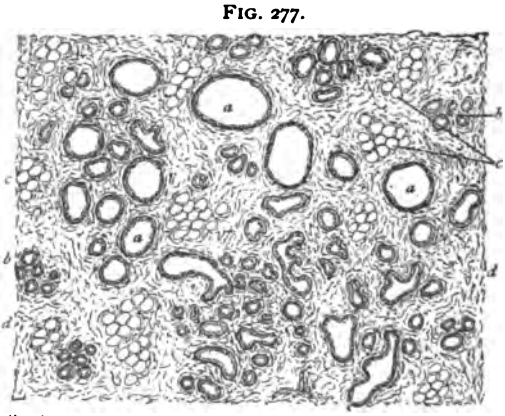

Section of human mammary gland undergoing retrogressive changes after lactation: *a*, sections of ducts; *b*, atrophic acini; *c*, fat-cells; *d*, interlobular connective tissue.

The relative proportion of the glandular structure to th vening connective tissue varies with the condition of functiona

of the organ. **During lactation** the secreting tissue predominates, and the septa are reduced to mere partitions; **before pregnancy** has taken place the connective tissue and fat form the bulk of the organ, the glandular structures then being represented by the system of ducts and excretory tubes, since the acini are present only as small solid rudimentary cylindrical cell-masses. **After lactation** the secreting parts of the organ atrophy and become much less conspicuous, some of the acini almost entirely disappearing, while connective tissue and fat constitute the greater part of the mamma. The termination of the period of sexual activity is followed by the **permanent atrophy** of the gland-tissue, which finally is almost complete, the entire mamma being then composed of **connective tissue** and **fat**, with scarcely a trace of the former conspicuous secreting structures. The **rudimentary breasts** of children of both sexes, and of the adult male, contain principally connective tissue, in which **excretory ducts**, attached to small groups of **immature acini**, lie embedded. Under exceptional circumstances the male mammary gland may secrete true milk.

The principal **blood-vessels** supplying the mammary glands run mostly in the superficial tissues somewhat radially towards the areola; from these vessels on the anterior surface of the organ branches penetrate into the glandular mass and pass between the lobules, giving off twigs which break up into capillaries enclosing the alveoli. The cutaneous papillæ are supplied with capillary tufts where not occupied by nervous structures. The vascular supply of the nipple, while generous, does not include cavernous tissue, the erectility of this part being due largely to the muscle.

The **lymphatics** include the radicles enclosed within the fibrous septa of the gland, as well as a net-work of subcutaneous lymph-canals within the more superficial portions of the organ. The lymphatic vessels are closely related to the surrounding chain of lymphatic glands, as well as to those within the axilla.

The **nerves** are distributed more richly to the superficial, cutaneous parts of the organ than to its secreting tissue. They are principally medullated fibres, those supplying the papillæ of the nipple and the areola in many cases ending in special **tactile corpuscles**; the nerves entering the base of the nipple often bear corpuscles of Vater. The deeper parts of the glands receive principally the pale fibres destined for the control of the blood-vessels, not, however, to the exclusion of medullated fibres; ganglion-cells have also been observed in connection with the latter.

Milk is composed microscopically of a clear fluid, the **milk-plasma**, in which numbers of small **oil-globules**, 2–5 μ in diameter, together with the granular **débris of disintegrated cells**, are

suspended. These globules do not coalesce, owing to the probable presence of a delicate **envelope of casein.** The addition of acetic acid or of caustic potash destroys the envelope and liberates the oil-droplets, which then run together, forming irregular masses. **Human milk** is usually **alkaline.**

FIG. 278.

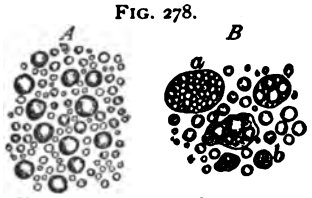

Human milk: *A*, usual appearance; *B*, shortly after delivery; *a*, large colostrum-corpuscle; *b*, small amœboid cells containing oil; *c*, colostrum-corpuscles with few oil-droplets.

The milk secreted **during the first few days after delivery** contains large fatty granular-looking bodies known as **colostrum-corpuscles;** these bodies probably represent the remains of a portion of the epithelial cells which at one time occupied the centre of the then solid acini, but which underwent fatty degeneration and partial destruction on the establishment of lactation.

The **development of the reproductive organs** comprises the genesis of two distinct parts, the **sexual glands** and their **excretory ducts.**

In order to understand the formation of the reproductive organs it is necessary to recall the condition of the fœtal excretory structures prior to the appearance of the sexual glands, since the Wolffian body and its duct play important *rôles* in the subsequent development of the generative tract. The **Wolffian body** consists essentially of a long tube, the **Wolffian duct,** which extends parallel with the vertebral axis throughout the lower part of the body-cavity, and of the transverse **Wolffian tubules,** which join the duct generally at right angles, so that the two parts of the Wolffian body are frequently compared to the back and the teeth of a comb. The tubules are tortuous, and bear close relations with tufts of convoluted capillary blood-vessels, much the same as the uriniferous tubules do in the Malpighian bodies of the kidney. Some time after the establishment of the Wolffian body and its duct, a second canal, the **Müllerian duct,** makes its appearance;

FIG. 279.

Section of rabbit embryo of ten and a half days, showing the Wolffian bodies and the early indifferent sexual glands; *w*, *t*, and *m*, respectively duct, tubules, and Malpighian corpuscle of Wolffian body; *p*, mesothelial surface of primary peritoneal cavity; *g*, indifferent sexual glands.

this tube lies parallel and in close proximity with the Wolffian duct, its cephalic end opening into the body-cavity, while its lower extremity terminates at first within the **cloaca** and later within the **uro-genital sinus.** It is necessary further to distinguish **three groups** of the Wolffian tubules, since the fate of these portions of the fœtal organ varies; these divisions are the anterior group, constituting the **pronephros,** the middle or **sexual segment,** and the posterior **rudimentary tubules,** which give rise to atrophic structures.

The **development of the sexual glands** includes a primary **indifferent** and a later **specialized** stage. During the period when the Wolffian body has attained its greatest growth there appears on the ventro-mesial surface of the organ a localized **thickening of the mesothelial elements.** This proliferation produces an eminence, the earliest trace of the sexual gland. This for some time is indifferent, since its appearance is identical in the two sexes. The **indifferent sexual glands** soon exhibit two kinds of elements, the loosely-packed proliferated **small mesothelial elements** and the sparingly-distributed much larger **primordial sexual cells.**

FIG. 280.

Section of peripheral zone of indifferent sexual gland from rabbit embryo: *e*, mesothelial cells constituting the later germinal epithelium; *s, s*, small elements derived from proliferation of mesothelium; *o*, large primordial sexual cells.

In the male, the further changes within the sexual gland include extended proliferation of the early mesothelial elements and their grouping as epithelioid cylindrical masses, the **sexual cords;** within the latter lie the large primordial sexual cells, their number, however, in the developing testicle being distinctly smaller than in the corresponding female organ. The sexual cords become the **seminiferous tubules,** remaining solid cylinders throughout fœtal life. The particular fate of the large sexual cells is still uncertain. The surrounding mesodermic tissue grows into the mesothelial mass and contributes the intertubular connective tissue as well as the denser portions of the framework represented by the tunica albuginea and the trabeculæ.

The system of canals forming the connection between the testicle and the epididymis, including the **vasa efferentia** and the **coni vasculosi,** are derived from the **tubules of the Wolffian body;** by the ingrowth of these canals into the embryonal testicle the isolated sexual gland is provided with excretory passages. Other remains of the **lower tubules** of the Wolffian body constitute the **paradidymis.** The main **tube of the epididymis** and the **vas deferens** are the direct representatives of the **Wolffian duct.**

The **Müllerian duct** in the male is atrophic, since its extreme anterior and posterior parts alone persist; these remain as the **non-**

stalked or **sessile hydatid,** in close relation with the epididymis, and as the short diverticulum opening into the prostatic portion of the urethra, the **uterus masculinus** or **sinus pocularis,** which is therefore the homologue of the vagina and uterus.

In the female the indifferent sexual gland early exhibits a grouping of the mesothelial elements into cylindrical masses, the **sexual cords,** which in the ovary, however, retain a closer connection with the germinal mesothelium than do those of the testicle. Many groups of epithelial elements are disposed vertically to the free surface of the organ, and constitute the **primary egg-tubes.** In the ovary, as in the testicle, the sexual cords contain the large **sexual cells,** the latter being much more plentiful in the female than in the male gland. The **ovarian stroma** originates later as a secondary ingrowth of the surrounding mesoderm between the groups of sexual cells. The genetic relations between the embryonal elements, particularly the large cells, and the ova and the follicular cells of the fully-formed ovary, are still indefinite. It may be assumed as established, however, that both these constituents of the later organ are derived from the cells constituting the sexual cords, and, therefore, indirectly from the **ovarian mesothelium** or primitive **germinal epithelium.** Whether the large sexual cells are the direct ancestors of the ova alone or contribute to the production of the follicular elements as well is uncertain, but it seems probable that the later ova are the immediate descendants especially of the large sexual cells.

FIG. 281.

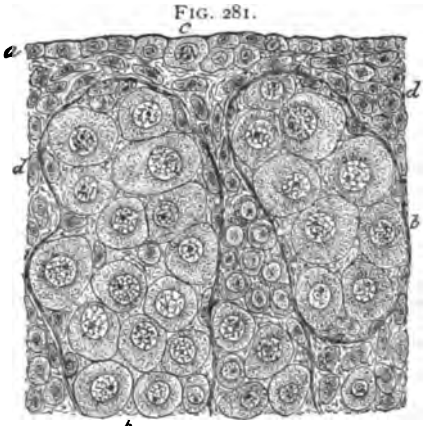

Section of ovary from very young kitten: *a*, ovarian mesothelium or germinal epithelium, containing large sexual cell (*c*); *b*, cylindrical epithelial masses constituting egg-tubes; *d*, developing stroma.

The passages providing for the escape of the product of the ovaries, the ova, are derived from the **Müllerian ducts,** their anterior segments remaining distinct tubes, the **oviducts,** while their middle and posterior divisions become fused and form respectively the **uterus** and the **vagina.** The **Wolffian body** and its **duct** in the female are represented by rudimentary structures, the **parovarium** and the **paroöphoron.** The horizontal **head-tube** of the former is the persistent anterior segment of the **Wolffian duct,** while the shorter **vertical branches** are the remains of the **Wolffian tubules.** The

presence of a number of the rudimentary canals which constitute the lower atrophic segment of the Wolffian body produces the obscure

FIG. 282.

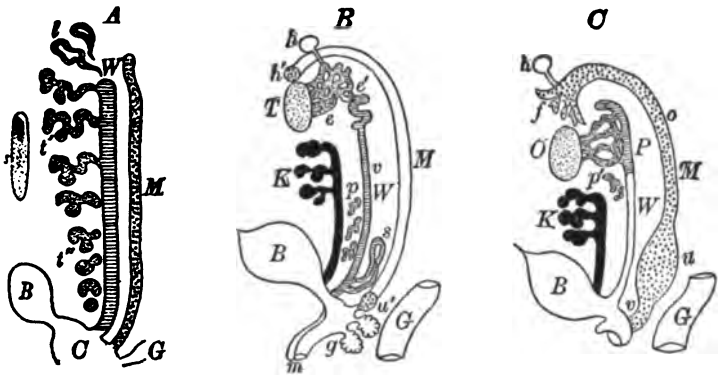

Diagrams illustrating development of sexual organs. In all figures *W*, *M*, *B*, and *G* represent respectively Wolffian duct, Müllerian duct, bladder, and gut. *A*, *indifferent type* containing fundamental parts: *s*, sexual gland; *t*, *t'*, *t''*, Wolffian tubules constituting anterior (pronephros), middle (sexual), and posterior (rudimentary) groups; those of sexual division retain their communication with Wolffian duct. *B*, *male type*: *T*, testicle; *e*, *e'*, tubes of globus major derived from middle Wolffian tubules; *v*, tube of epididymis, the persistent Wolffian duct; *s*, seminal vesicle; *p*, paradidymis; *h'*, unstalked hydatid; *u'*, uterus masculinus, the persistent parts of the Müllerian duct (*Mf*); *h*, stalked hydatid; *g*, Cowper's glands; *m*, penis; *K*, kidney. *C*, *female type*: *O*, ovary; *P*, parovarium; *p'*, paroöphoron; *W*, Gärtner's duct when present; *f*, fimbria; *o*, oviduct; *u*, uterus; *v*, vagina; *h*, stalked hydatid; *K*, kidney. (Modified after *Wiedersheim*.)

Paroöphoron, the homologue of the paradidymis. The greater part of the Wolffian duct atrophies in the female; when it persists as a pervious canal it becomes the **duct of Gärtner.**

Male.	Indifferent Type.	Female.
Testicle.	*Sexual gland.*	Ovary.
Tubules composing globus major.	*Wolffian tubules.*	Short tubules of parovarium.
Paradidymis.		Paroöphoron.
Tube of epididymis and vas deferens.	*Wolffian duct.*	Head-tube of parovarium. Gärtner's duct when persistent.
Stalked hydatid.	*Duct of pronephros.*	Stalked hydatid.
Sessile hydatid representing fimbria.	*Müllerian duct.*	Oviduct.
Sinus pocularis.		Uterus.
		Vagina.
Bladder.	*Lower segment of allantois and part of cloaca.*	Bladder.
Urethra.	*Uro-genital sinus.*	Vestibule and urethra.
Prostate gland.		Paraurethral tubes.
Cowper's glands.		Bartholin's glands.
Penis.	*Genital eminence.*	Clitoris.
Prepuce.	*Genital folds.*	Labia minora.
Scrotum.	*Genital ridges.*	Labia majora.

CHAPTER XIV.

THE RESPIRATORY ORGANS.

THE respiratory tract consists of two parts,—the system of **air-passages**, including the nasal fossæ, pharynx, larynx, trachea, and bronchial tubes, and **special organs**, the lungs, devoted to the performance of the respiratory function.

THE LARYNX.

The **larynx** consists of the **cartilaginous framework** formed by the thyroid, the cricoid, the arytenoid, and the other smaller cartilages of Wrisberg and of Santorini, united by the ligamentous membranes and the bands of fibrous tissue, and lined within by **mucous membranes**; on the outside the cartilages are covered by fibrous and muscular structures.

The **mucous membrane** of the larynx possesses the same constituents as does that of the pharynx,—namely, an epithelium and a tunica propria; beneath the latter lies the submucosa.

The **epithelium** covering the free margins of the epiglottis and partly the larynx as far as the false vocal cords is **stratified squamous** in character; at the lower edge of the false vocal membranes the epithelium becomes **stratified ciliated columnar**, which type is retained throughout the ventricle of the larynx. Over the true vocal cords the epithelium once more becomes **stratified squamous**, beyond which point the **stratified ciliated columnar** character is again resumed and retained throughout the trachea and the bronchi. Numerous taste-buds, identical in structure with those of the tongue, lie embedded on the posterior surface of the epiglottis.

The **tunica propria** of the larynx is composed of fibrous connective tissue, with which is mingled an especially rich net-work of elastic fibres; the **true vocal cord** consists of the free lateral margin of the crico-thyroid ligament covered by mucous membrane; over the fibro-elastic basis of the cord stretches the mucosa clothed by stratified squamous epithelium and re-enforced externally by the fasciculi of the thyro-arytenoideus muscle. In addition, large numbers of **leucocytes** lie scattered throughout the mucosa; in the posterior surface of the epiglottis, the false cords, and the ventricle of the larynx the leucocytes are so numerous within the subepithelial tissue

that the mucosa assumes the character of **diffuse adenoid tissue.** The superficial part of the tunica propria is beset with papillæ, best developed in those regions which are covered with squamous epi-

FIG. 283.

Longitudinal section of larynx of child, exhibiting vocal cords and ventricle: *a*, surface above false cord (*b*) covered with squamous epithelium; *c*, true cord covered with squamous epithelium; *V*, ventricle lined with ciliated columnar epithelium; *d*, ducts of mucous glands (*g*) cut in various directions; *m*, fibres of thyro-arytenoideus muscle.

thelium. The deeper layer of the mucous membrane is of loose structure, and passes into the still looser tissue of the **submucosa,** which serves to attach the mucous membrane with the surrounding firmer structures. In places the submucous tissue contains **mucous follicles,** .2–1 mm. in length, lined with columnar cells, many of which are distended with mucous secretion, even to the condition of

goblet-cells. The minute groups of glands in the **epiglottis** lie embedded within the pits and openings in its plate of cartilage. The true vocal cords are destitute of mucous glands.

FIG. 284.

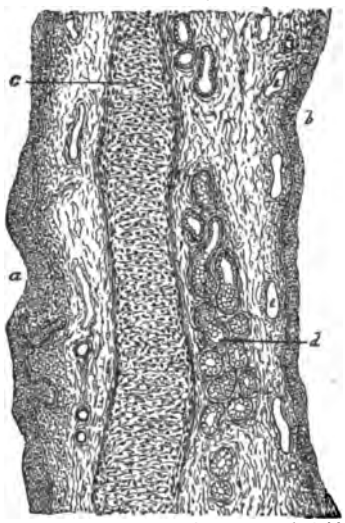

Longitudinal section of epiglottis of child: *a*, laryngeal surface; *b*, glossal surface; *c*, plate of elastic cartilage; *d*, acini of mucous glands.

The **cartilaginous framework** of the larynx consists principally of **hyaline cartilage**; to this variety belong the **thyroid**, the **cricoid**, and the greater part of the **arytenoid cartilages**. The **epiglottis**, the apex and the processus vocales of the **arytenoid cartilages**, together with the **cartilages of Wrisberg** and **of Santorini**, are formed of the **yellow elastic** variety. The little nodules embedded within the lateral thyro-hyoid ligaments, the **cartilagines triticeæ**, are sometimes composed of fibrous, at other times of yellow elastic cartilage. On the outer side fibrous connective tissue connects the **perichondrium** with the surrounding structures, the **attachment of the muscles** being effected by tendinous tissue directly continuous with the investment of the cartilage.

The **blood-vessels** supplying the interior of the larynx terminate within the mucosa in capillary net-works beneath the epithelium; those parts where papillæ exist these are provided with vascular loops.

The **lymphatics** exist as a **superficial net-work** of small vessels within the mucosa, and a **deeper set**, composed of much larger channels, within the submucous tissue; these latter vessels are of exceptional size on the anterior surface of the epiglottis. The **lymphoid character** of the **mucosa** in certain localities has already been noted; local aggregations of such cells in the form of **lymph follicles** are encountered in man sometimes, and constantly in some of the lower animals (dog, cat).

The **nerves** distributed to the laryngeal mucous membrane are composed principally of medullated fibres, although pale fibres are present.

THE TRACHEA.

The trachea in its general structure resembles the lower part of the larynx: it consists of a **fibrous tube**, lined by the **mucous membrane**, and strengthened and kept open by a series of incomplete **cartilaginous rings**.

The **mucous membrane** of the trachea is lined by **stratified ciliated columnar epithelium**, among whose elements lie numbers of goblet-cells. The current established by the ciliated epithelium tends to expel mucus or other substances.

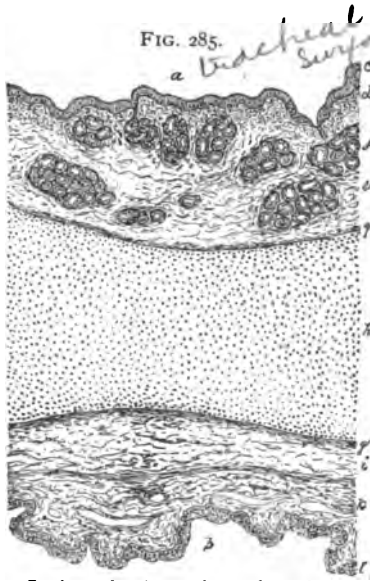

FIG. 285.

Section embracing trachea and œsophagus of child: *a*, *b*, tracheal and œsophageal surfaces; *c*, tracheal epithelium; *d*, stroma of mucosa; *e*, submucosa; *f*, mucous glands; *i*, part of ring cartilage; *g*, its perichondrium; *i*, fibrous tissue; *k*, fibro-muscular tissue of œsophagus; *l*, œsophageal epithelium.

The **tunica propria** is conspicuous on account of the large amount of **elastic tissue** which it contains; owing to the disposition of the elastic fibres, two zones are recognizable, an **inner** loosely-thrown-together **fibrous layer**, containing some elastic tissue, vascular loops, and nerve-fibres, together with numerous lymphoid cells, and an **outer layer**, next the submucosa, made up largely of close net-works of longitudinal **elastic fibres**. The elastic fibres are particularly robust and abundant along the posterior membranous wall of the trachea, between the ends of the cartilages.

The **submucosa** is loosely arranged, and connects the mucosa with the fibrous sheath, as well as supports the glands and larger blood-vessels, lymphatics, and nerve-trunks. The **tracheal glands** are represented by numerous small groups of **racemose** structures which occupy the **submucous layer** and communicate with the mucous surface by means of the long **excretory ducts**. The latter are lined with **low columnar epithelium**, while the acini contain **cuboidal cells**.

The **fibrous coat** lies external to the submucosa and forms a complete investment in which the cartilaginous rings are embedded. These latter are C-shaped masses of **hyaline cartilage**, embracing almost three-fourths of the tracheal tube. The remaining cleft is bridged by the continuation of the **fibrous tunic** supplemented by

a layer of transversely-disposed bundles of **non-striped muscle**. These latter extend for some little distance along the inner side of the cartilages, to whose perichondrium they are attached. The muscle not only exists between the ends of the cartilaginous plates, but also passes across in the intervals between these, thus constituting a **continuous layer**, which serves to narrow the tube. In addition to the transverse bundles, a few **longitudinal muscular bands** are present. The outer surface of the fibrous tunic is connected with the surrounding structures by loose areolar tissue.

The larger **blood-vessels** pass to the submucosa, from which smaller twigs are given off to supply the mucous membrane and, partially, the fibrous and cartilaginous structures. The vessels terminate within the mucosa in a net-work beneath the epithelium; the acini of the mucous glands within the submucous layer are surrounded by capillaries.

The **lymphatics** of the trachea are numerous within the mucous and submucous coats, where they constitute plexiform arrangements of large, irregular, thin-walled channels. Lymphatic tissue in the form of **solitary follicles** also occurs.

The **nerves** contain both medullated and non-medullated fibres. The larger trunks pass within the submucosa and send smaller fibres into the mucosa, where they course as minute naked fibrillæ; the exact mode of their ending is unknown.

THE BRONCHI.

The larger **bronchial tubes** repeat almost exactly the structure of the trachea, with such modifications as result from the slight general development of the several coats incidental to the gradual reduction in the size of the tubes.

On reaching the **small bronchi** the **epithelium** is reduced to a single layer of **ciliated columnar cells**. The thickness of the mucosa at first is not greatly diminished, since the loss sustained by the thinning of the elastic tissue of the tunica propria is compensated by the appearance of an additional layer of **non-striped muscle** situated at the outer border of the mucosa, next the submucosa; this layer, which corresponds to a **muscularis mucosæ**, forms a complete investment, especially conspicuous when the cartilaginous plates diminish. The **ring-cartilages** of the bronchi become reduced in size, then broken up, and finally replaced by **irregular short plates**; these, becoming smaller and infrequent, embrace gradually less of the circumference of the tube, until in the bronchial twigs of a diameter of about one millimetre they altogether disappear.

By repeated division the bronchial tubes become greatly reduced in size, the reduction being accompanied by the changes already

noted ; when the diameter of the twig no longer exceeds **one millimetre** the tube is termed a **terminal bronchus.**

FIG. 286.

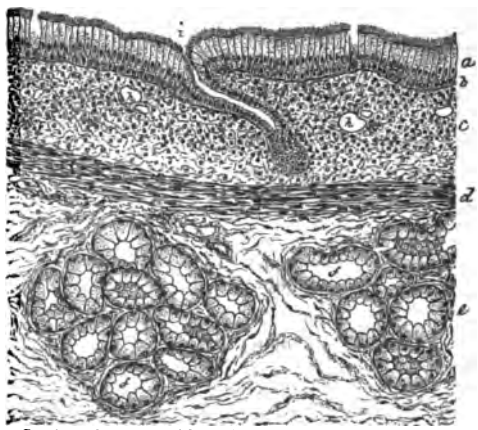

Section of portion of bronchus of child: *a*, epithelium; *b*, basement-membrane; *c*, stroma of mucosa; *d*, layer of involuntary muscle; *e*, submucosa; *f*, acini of mucous glands; *h*, blood-vessels; *i*, obliquely cut duct of mucous glands.

According to Miller, the distal extremity of the terminal bronchus communicates with several spherical cavities, the **atria.** Each of the latter in turn opens into a group of larger and less regular spaces, the **air-sacs,** into which directly open the ultimate air-spaces, the **alveoli** or **air-cells.** The latter open not only into the air-sacs and atria, but also beset the alveolar ducts as minute sacculations that impart an irregular contour to the air-tube.

The walls of the **terminal bronchial tubes** consist at first of a single layer of **ciliated columnar epithelium,** outside of which the mucosa contains longitudinal **elastic fibres** and thin, irregular, annular bundles of **non-striped muscle.** The **mucous glands** and the **cartilaginous plates** are wanting in the terminal tubes. Within the latter the ciliated cells disappear, a simple columnar epithelium existing for some distance, which, in turn, is replaced by cuboidal cells on approaching the atria.

FIG. 287.

Diagram of terminal compartments of air-passage: *B*, terminal bronchus; *A*, atrium; *S*, air-sac, into which open air-cells (*C*). Branches of pulmonary artery follow bronchus; those of pulmonary vein lie at periphery. (*Miller.*)

The walls of the irregular atria suffer still further reduction, the fibrous coat becoming greatly thinned, while the mucosa is reduced to a delicate tunica propria of fibro-elastic tissue, in which bundles of non-striped muscle may remain.

The **epithelium** of the smaller passage, at first low cuboidal in character, rapidly assumes a **flat polygonal** type ; towards the air-sacs **large flat plates** appear among the smaller polygonal cells, and become more numerous as these terminal divisions of the air-passages are neared.

Within the irregularly round air-sacs the epithelial lining consists of the large flat endothelioid plates, or **respiratory epithelium**, between which elements diminutive groups of the smaller polygonal cells appear. In the air-cells, presently to be described, the large plate-like elements of the respiratory epithelium chiefly constitute the lining.

THE LUNGS.

The lungs, with their system of air-tubes, correspond in plan of structure and in development to **racemose glands,** the excretory ducts being represented by the bronchial tubes, and the glandular tissue by the pulmonary parenchyma. The latter is built up of **groups of air-sacs** enclosed by connective tissue to form **lobules**, which are associated in larger groups ; these latter in turn are united into the **lobes.** All these divisions are connected by **alveolar tissue,** the external surface being additionally covered by the pleura.

By the division of the terminal bronchial tube into the several atria, and the subsequent origin from these of the air-sacs and the alveoli, the part of the pulmonary parenchyma in communication with a single terminal bronchiole forms a **pyramidal mass**, whose **apex** corresponds to the **terminal bronchus,** and whose **base,** when reaching the free surface, appears as one of the **polygonal areas** marking the exterior of the lung. These larger polygonal fields, made up of many smaller areas which correspond to the groups of the alveoli, are often defined with great distinctness by the pigment accumulated within the connective tissue separating the adjacent lobules.

FIG. 288.

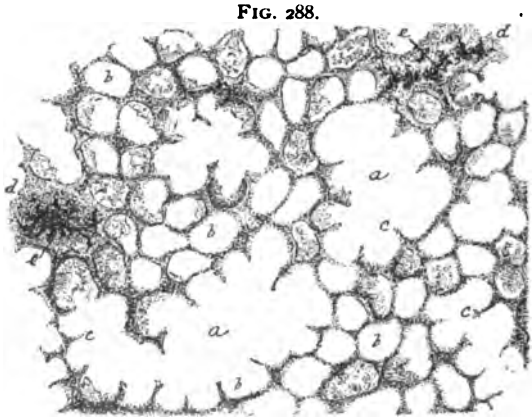

Section of human lung: *a*, atria and air-sacs cut in various directions; *b*, alveoli separated by interacinous partitions (*c*); *d*, masses of connective tissue containing accumulations of pigmented particles (*e*).

The ultimate air-cells, or **alveoli** of the lung represent the acini of racemose glands, the similarity being especially marked in the uninflated organ, which still retains its glandular character. Opening into the cavity of the expanded air-sacs and the less uncertain atria, the

are placed closely side by side, and by mutual pressure be- polyhedral. Around the opening or **base of the alveolus,** it communicates with the air-sac wall, the **elastic tissue** of ter is arranged as a **ring,** from which elastic fibres pass in all ons over the air-sac to form its **framework.**

wall of the alveoli comprises the **epithelium,** the **con- ve-tissue framework,** and the **capillary net-work.**

epithelial lining is represented chiefly by a **single layer ge plates,** closely resembling endothelium in silvered prepara- among which **polyhedral** ie scattered as d elements or ups of two or Originally, e embryonal ion of the tis- ily the smaller edral cells are t in the air- nd the closed , the large ike elements pearing **after** sue has been led following **ion** of the The small

FIG. 289.

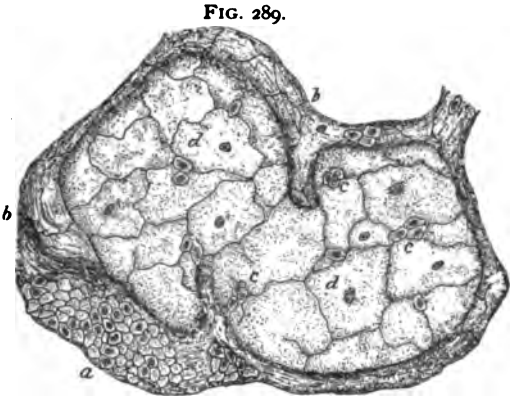

Section of silvered lung of kitten, including portions of two alveoli and atrium: *a*, small polyhedral epithelial cells covering distal part of atrium; *b*, fibro-elastic framework; *c*, large flattened epithelial plates lining alveoli, among which lie small groups of the small cells (*d*).

herefore, are to be regarded as **genetically identical** with ger, the only difference being that the smaller have **never gone the expansion** to which their neighbors have been sub- ; during forced expiration the larger cells become diminished . Between the cells, frequently at the juncture of the angles eral, minute **pseudo-stomata** may exist ; they usually con- ith microscopic passages leading into the lymphatic channels. ans of these channels **particles of inhaled foreign matters,** leeply pigmented, are carried from the air-sacs into the lym- s, and become lodged within the interlobular connective tis- Additional particles are carried into the tissues by means of **andering lymphoid cells** which occur within the epithelium air-sacs and air-passages.

framework of the alveoli is composed almost entirely of the **c fibres** springing from the annular bundle surrounding the of the sac. These fibres unite to form a net-work which

completely surrounds the alveolus and constitutes the septum between the adjoining air-cells, at the same time supporting the capillary vessels and the investing epithelium. In addition to the elastic fibres, a very small quantity of **fibrous tissue,** with a few connective-tissue cells, aids in the construction of the alveolus.

The **capillary net-work** within the walls of the alveoli is remarkable for the closeness of its meshes, being one of the **densest vascular net-works** within the body. The **larger arterial stems** take their course, in company with the veins, bronchioles, nerves, and lymphatics, within the thicker tracts of **interlobular connective tissue**; the **smaller twigs** extend among the groups of the air-sacs, embracing the openings into the alveoli with more or less complete **rings,** from which pass the capillaries enveloping the air-cells with **net-works** on all sides. Between the adjoining alveoli lies only a **single layer** of capillary vessels, which, however, are not confined to a single plane, but encroach alternately upon the adjacent air-sacs as projecting arches or loops.

FIG. 290.

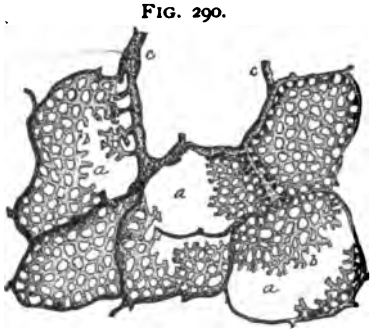

Section of injected and inflated lung of cat: *a*, air-sacs enclosed in dense capillary net-works (*b*); *c*, larger interlobular branches of pulmonary artery.

While the **interalveolar septa** are reduced to a minimum, the two layers of **respiratory epithelium** lining the adjoining air-cells, the scanty **connective-tissue framework** and the **capillary network** constituting their entire bulk, the alveoli belonging to **different,** although neighboring, end-tubules are separated by distinct **connective-tissue partitions**; these increase in thickness as the included divisions of pulmonary substance become larger, and reach their greatest development in the **fibrous envelopes** ensheathing and separating the lobes.

Owing to the accumulation of the **pigmented particles** conveyed by the lymphatics in the manner already described, the interfundibular and often also the interlobular connective tissue present dark patches, the degree of discoloration varying from a few scattered irregular points to an intense almost uniformly black area. The **presence of pigment** within the connective tissue emphasizes the outlines and **boundaries of the lobules** with diagrammatic sharpness.

The **blood-vessels** of the lungs enter at the hilus along with the large divisions of the bronchus; the smaller branches of the pulmo-

nary artery follow the air-tubes to their ultimate distribution, the arterioles extending along the respiratory bronchial tubes and terminal ducts as far as the **interatrial septa.** They there end in **capillary net-works** which surround the air-sacs in the manner above described. In their course along the respiratory bronchial tubes and the terminal ducts the pulmonary arterioles give off twigs which form **net-works around the air-cells** besetting those passages. The blood of the alveolar net-works is carried away by the radicles of the pulmonary veins, which begin at the margins of the air-cells.

In addition to the system of vessels derived from the pulmonary artery destined for the **respiratory function,** a second group, for the **nutrition of the pulmonary tissues,** is distributed by the **bronchial arteries.** These vessels run in company with the bronchial tubes and the other blood-vessels within the interlobular connective tissue and give off twigs which break up into the capillaries immediately supplying the walls of the air-passages and associated structures. Additional capillaries supply the **interlobular areolar tissue** and the **pleural tissues** on the surface of the lungs.

The numerous **lymphatics** of the lung are arranged as two sets, those originating within the **connective-tissue septa** and those arising in connection with the **bronchial mucous membranes.** Of the former two groups are recognized, one of which includes the channels beginning within the **interlobular fibrous tissue** and forming the lymphatics which accompany the branches of the pulmonary blood-vessels; the other, the superficial set, arises by the radicles connected with the **subpleural lymph-spaces,** which communicate with the serous cavity of the pleura by means of the minute passages leading from the intercellular orifices of the pleural surface into the subjacent lymph-clefts.

The **bronchial lymphatics** originate within the subepithelial lymph-spaces which communicate with the mucous surfaces of the air-tubes and the alveoli through the stomata; from the subepithelial plexus larger lymph-channels unite with others to form definite lymphatic canals; these accompany the blood-vessels to the root of the lung, where the superficial and deep lymphatics meet and are taken up by a few **trunks of large size** which pass from the lung to the **bronchial lymph-glands.** Masses of lymphoid tissue of varying extent are associated with the walls of the alveolar ducts and the bronchial tubes, as well as the subpleural and peribronchial areolar tissue.

The **nerves** of the lung include contributions from both the cerebro-spinal and the sympathetic system. The nerve-trunks, made up of medullated and pale fibres, enter the organ at its root and follow the air-tubes and the blood-vessels. Small groups of ganglion-cells

occur along their course. On reaching the smaller and the terminal ramifications of the bronchial tubes the nerves become broken into fine non-medullated fibrillæ, which pass to the muscular tissue of the tubule as well as to the mucous membrane. The exact mode of final termination of the nerve-filaments within the pulmonary tissue is still undetermined.

THE PLEURA.

The pleura resembles in structure other **serous membranes,** the general characters of which have been already considered in Chapter VIII. It consists of an **endothelial covering, a connective-tissue matrix,** and **subpleural tissue.** The lining of the pleural cavity is not of equal thickness in all parts, the visceral or pulmonary pleura being thinnest as well as most firmly attached, while the parietal or costal pleura is thickest, and, owing to the well-developed subpleural tissue existing in this region, less rigidly adherent.

FIG. 291.

Section of human pleura covering surface of lung: *a*, endothelium; *b*, fibro-elastic stroma; *m*, cut bundle of muscle-cells; *p*, peripheral layer of pulmonary tissue.

The **endothelium** of the parietal portion possesses cells more expanded and thinner than those covering the surface of the lung; the elements in this latter position vary in their size with the **changes in the bulk** of the pulmonary mass. Between the endothelial plates minute **stomata** exist, which through the minute canaliculi indirectly communicate with the lymphatic spaces within the subjacent tissue.

The **stroma of the pleura** consists of fine bundles of fibrous connective tissue intermingled with elastic fibres; within the fibrous lamellæ the intercommunicating **lymph-channels** form a plexus of considerable richness, which communicates on the one hand with the pleural cavity through the stomata and intervening canaliculi, and on the other with the neighboring lymphatics within the **subpleural tissue.**

The latter where developed as a layer of some thickness, as beneath the parietal pleuræ, is composed of loosely-disposed areolar tissue, containing many elastic fibres. Upon the lung the subpleural layer is intimately united with the pulmonary tissue, and forms a strong superficial **fibrous envelope,** in which bundles of **non-striped muscle** are also present. Within the stroma of the visceral pleura the **blood-vessels** form a wide-meshed capillary reticulum over the surface of the lung; superficial vessels communicate with deeper branches surrounding the interalveolar septa.

The **nerves** of the pleura occur as infrequent stems, composed

principally of medullated fibres; fibrillæ are traceable into the subpleural tissue, but their exact mode of ending is uncertain.

THE THYROID BODY.

In view of its topographical relations, as well as a matter of convenience, it is usual to consider this organ in connection with the respiratory tract, although such association is only incidental and without foundation or morphological significance, unless its descent in common with the respiratory organs as an outgrowth from the pharyngeal entoderm be regarded in such light.

The **thyroid body** is a **compound tubular gland** whose excretory canal, the **thyro-glossal duct,** in the early stages of the organ, connects the tubules with the mucous surface, where its opening corresponds to the **foramen cæcum,** situated on the dorsum about an inch from the base of the tongue. After a short existence, long before the gland attains its full development, the thyro-glossal duct

FIG. 292.

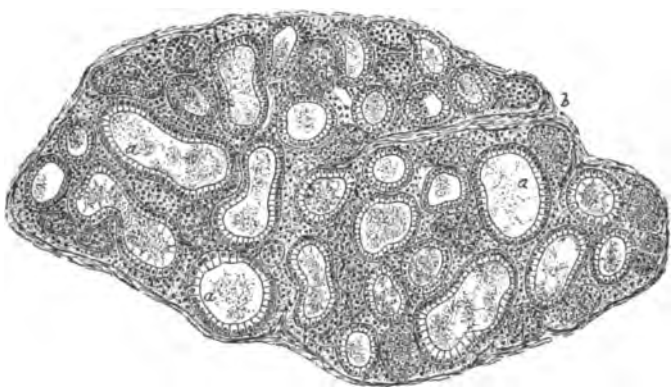

Section of thyroid body of child: *a*, acini distended with colloid secretion, cut in various directions; *b*, interlobular connective tissue.

undergoes atrophy and more or less complete obliteration; the **acini,** consequently, become **isolated closed cavities,** while the organ is often classed as a ductless gland.

The fully-developed adult thyroid gland consists of numerous **tubular acini,** 40–110 μ in diameter, united by intertubular areolar tissue into **lobules**; these, in turn, are joined into **lobes** by still larger masses of connective tissue, which form on the outside of the organ a general external **fibrous envelope.**

The **acini** are completely closed, and lined with a single layer of cuboidal or **low columnar epithelium,** whose component cells rest upon a distinct basement-membrane. The enclosed cavities differ

according to the size and the distention of the acini; they usually contain a viscid yellowish mass, the **colloid substance**, produced through the active agency of the cells lining the acini. In addition to the characteristic colloid secretion, detached **epithelium, leucocytes,** migrated **plasma-cells,** and in very many cases **colored blood-corpuscles,** are included within the contents of the alveoli. The presence of red blood-cells in various stages of disintegration has suggested the destruction of effete blood-cells as a possible function, in part at least, of this questionable organ. The inter-alveolar tissue contains elements closely resembling plasma-cells.

FIG. 293.

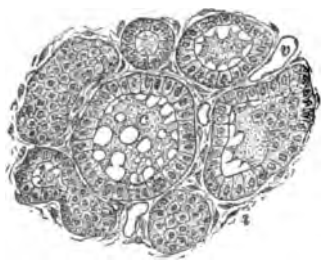

Section of thyroid body, exhibiting detail of the acini, which are cut in various directions: *c*, colloid material distending the larger acini; *i*, interacinous connective tissue; *v*, blood-vessels.

The **blood-vessels** of the thyroid gland are exceptionally numerous, the arteries being remarkable for their **large size** and very **free anastomoses.** From the larger branches, which run within the interlobular tissue, small twigs pass between the alveoli and break up into capillaries surrounding the acini with a close-meshed net-work situated immediately beneath their epithelium. The venous radicles are also numerous, and form the conspicuous superficial plexuses.

The plentiful **lymphatics** occupy the deeper connective-tissue septa between the lobules as well as the fibrous envelopes surrounding the lobes. The **deeper lymphatics** begin as spaces lying between the bundles of fibrous tissue close to the acini, and frequently contain characteristic colloid substance. Large **superficial trunks,** provided with valves, carry off the accumulations from the smaller canals.

The few **nerves** which supply the thyroid gland are derived almost entirely from the sympathetic system. The fibres, therefore, are principally of the pale, non-medullated variety, and seem to be distributed especially to the walls of the blood-vessels; a few medullated fibres are usually present, but the exact mode of their termination is uncertain.

The **development of the respiratory organs** begins as a **ventral evagination** of the entodermic lining of the primitive pharynx. The caudal extremity of this complex cavity abruptly narrows into the œsophageal division of the primary gut tract. The earliest indication of the formation of the respiratory apparatus consists in the extension of the ventro-dorsal diameter of the primitive œsophagus at its pharyngeal end, in which plane it now appears as an irregularly-compressed ellipse.

The **pulmonary evagination** extends caudally for some distance,

when its expanded extremity divides into two **lateral diverticula**; of these, the right, which is the larger and longer, subdivides into **three** branches, while the left bears but **two.** These pouches correspond to the future lobes, and thus early establish the asymmetrical division of the future lungs. The **pharyngeal end** of the pulmonary tube becomes the larynx, while the remaining portions form the system of **air-passages,** including the trachea and the bronchial tree. In the further development of the bronchial ramifications the same general plan of division is repeated. The already-existing tube **divides dichotomously,** but the limbs of the forks grow unequally, since the **ventral bud** becomes the continuation of the stem, while the other becomes a lateral branch. After the entire system of air-passages is established the expanded ends of the terminal buds produce the ultimate divisions of the **pulmonary structure.** While the entodermal diverticulum thus takes part in the formation of the entire pulmonary tract, its contribution is limited to the **epithelial lining** of the alveoli and the air-tubes, while the remaining constituents of the respiratory organs are derived from the mesoderm. The **mesodermic tissue**

FIG. 294.

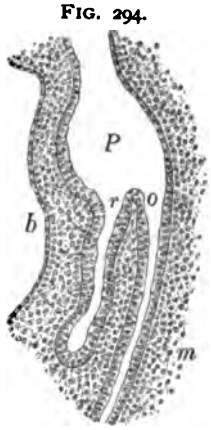

Part of sagittal section of eleven-day rabbit embryo, showing pulmonary evagination: *P*, primitive pharynx; *r*, *o*, respiratory and œsophageal tubes; *b*, body-cavity; *m*, mesodermic tissue.

FIG. 295.

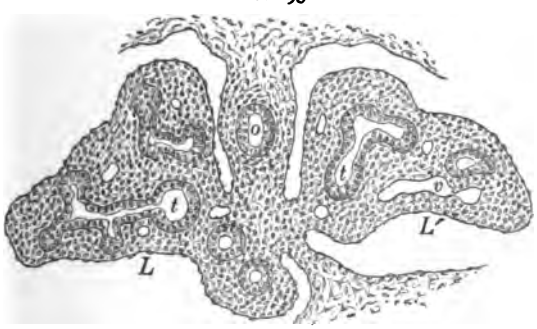

Portion of section of thirteen-day rabbit embryo, including developing lungs; mesodermic pulmonary masses, *L*, *L'*, are covered with primary pleural endothelium and penetrated by bifurcations of primary bronchi (*l*, *l*); *v*, blood-vessels; *o*, œsophageal tube.

surrounds the entodermic diverticula, constituting for a time a conspicuous mass, into which the epithelial tubes grow. Subsequently the mesodermic area becomes so completely invaded by the rapidly-

developing system of primary air-tubes and alveoli that its relative quantity is greatly reduced, since it eventually is limited to the **connective-tissue framework** of the organ. The appearance of the blood-vessels occurs at a later period. The derivation of the greater part of the digestive and of the respiratory tract is identical, — namely, the **epithelial structures from the entoderm** and the remaining tissues from the mesoderm.

FIG. 296.

Portion of sagittal section of twelve-day rabbit embryo, exhibiting mesial thyroid area as epithelial outgrowth (*t*) still connected with pharyngeal entoderm (*e*); *m*, surrounding mesoderm.

The **development of the thyroid body** includes the history of **two structures** which originate independently, but which after a short time in man and other mammals become blended to constitute a single organ: in many animals, however, the **mesial** and **lateral thyroid areas** produce organs which permanently remain distinct.

The **middle thyroid area,** from which originates the true thyroid body, appears as a **ventral outgrowth** from the entodermic lining of the **primitive pharynx** at a position corresponding approximately with the second visceral arch. The mesial outgrowth rapidly elongates, and after a time usually loses its attachment with the pharyngeal epithelium. The entodermic mass gradually leaves the primitive pharynx and assumes a close relation with the paired lateral thyroid areas, with which it eventually fuses.

FIG. 297.

Portion of section of fourteen-day rabbit embryo, including lateral thyroid area (*t*) which is still attached to fourth inner pharyngeal furrow (*p*); *m*, surrounding mesoderm.

The **lateral developmental areas** of the thyroid body appear as **ventral outgrowths** from the entodermic lining of the **fourth inner visceral furrow** on either side. The **epithelial evaginations** become elongated cylindrical masses, which undergo active proliferation and extend their bulk as branching cords; where these are at first solid they subsequently obtain a lumen, and for a time present the character of **tubular glands.** The later changes include the approximation and final fusion of the two lateral and the single mesial areas to form the thyroid body of the mammalian type. The **disappearance of excretory ducts** and the **ingrowth** of the surrounding **mesoderm** result in the division of the organ into lobules and the isolation of the imperfectly-developed acini. Distention of the latter by accumulations of **colloid material** follows the activity of the secreting cells within the ductless alveoli.

CHAPTER XV.

THE SKIN AND ITS APPENDAGES.

THE SKIN.

THE skin consists of two parts: the superficial epithelial layer—the **epidermis** or the **cuticle**, derived from the **ectoderm**—and the deeper connective-tissue layer—the **corium** or the **cutis vera**, derived from the **mesoderm**. Blended with the corium and separated from it by no sharp demarcation, the **subcutaneous tissue** exists

FIG. 298.

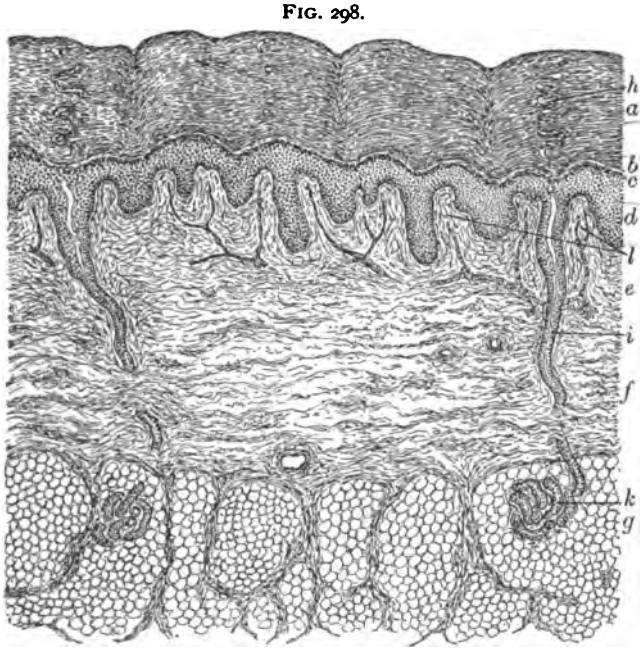

Section of human skin: *a*, stratum corneum; *b*, stratum lucidum; *c*, stratum granulosum; *d*, stratum Malpighii; *e*, *f*, papillary and reticular layers of corium; *g*, stratum of adipose tissue; *h*, *i*, spiral and straight portions of duct of sweat-gland; *k*, coiled portion of sweat-gland; *l*, vascular loops occupying papillæ of corium.

usually as a stratum of considerable thickness, which forms a loose attachment between the skin and the adjacent structures. The integument **varies in thickness** from .3 to 3.75 mm., being thicker on the back of the head, the neck, and the trunk than on their

anterior aspects, and thicker on the outer side of the limbs than on their mesial surfaces.

The **epidermis,** or the cuticle, is a highly developed **stratified squamous epithelium**; while forming a protecting layer to the underlying sensitive corium over the entire surface of the body, the epidermis varies in different regions, in some places, as on the eyelids and brow, not exceeding .1 mm. in thickness, while in others, as on the soles of the feet and the palms of the hands, it reaches almost 1 mm. The epidermis is accurately adapted to the opposed surface of the corium, which is beset with **papillæ,** so that when the two layers are separated the under surface of the epidermis presents impressions or pits corresponding to the elevations of the corium which they receive.

FIG. 299.

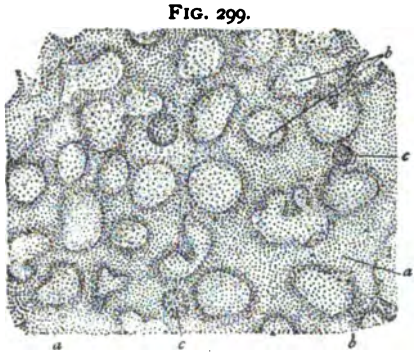

Epidermis of human skin separated from corium, viewed from beneath: *a*, thickened areas filling depressions between papillæ; *b*, pits receiving papillæ of corium; *c*, ducts of sweat-glands.

FIG. 300.



Section of human skin from hand, including superficial layer of corium and epidermis: *a*, *b*, *c*, *d*, respectively the stratum corneum, lucidum, granulosum, and Malpighii; *e*, layer of columnar cells next the corium; *f*, fibro-elastic tissue constituting papillary layer of corium.

The **cells composing the epidermis** are arranged in many irregular layers, the number of which depends upon the cuticular development in any particular region; where well represented the layers are grouped into two sharply-defined zones, the inner, darker, softer **stratum Malpighii** and the outer, clearer, denser **stratum corneum**; where highly developed the epidermis presents two additional zones, distinguished by the peculiar character of the protoplasm of their cells; these layers are the **stratum granulosum** and the **stratum lucidum.**

The **stratum Malpighii,** or **rete mucosum,** contains the most

recently formed and most actively growing elements, the deepest of which, next the corium, are perpendicularly placed and possess a distinct **columnar character.** The irregular and often slightly **expanded bases** of the deepest cells rest upon the thin basement-membrane, while their outer ends are surrounded by the more polyhedral elements.

Next the layer of columnar cells the elements become broader and polyhedral in form and possess the delicate **protoplasmic spines** characteristic of **prickle-cells.**

The elements of the succeeding **horny layer** stand in marked contrast to those of the soft underlying Malpighian stratum, owing to the production of **keratin** within the protoplasm and the desiccation of the cells. These influences are seen in the superficial layers, in the disappearance of the nucleus, and in the reduction of the once large polyhedral cells into the thin compressed horny plates of the outer layer.

At the inner border of the horny layer lies a thin band of cells, conspicuous on account of the marked granular appearance of their protoplasm; these constitute the **stratum granulosum,** and contain granules of **eleidin,** a peculiar substance, probably identical with keratohyaline, staining intensely in certain dyes, and resulting from the cornification of parts of the epithelial elements occupying the outer layer of the stratum Malpighii.

At the outer border of the granular stratum the **horny elements** begin; those lying next the stratum granulosum, however, are incompletely transformed into horny substance, and appear as an ill-defined narrow zone, the **stratum lucidum,** which contrasts strongly with the darker granular layer. Superficial to the clear zone lie the characteristic cells of the **stratum corneum**; these epithelial elements are enlarged and without nuclei, the outermost cells being compressed **flattened horny scales,** which after desiccation undergo desquamation and mechanical abrasion.

Over those parts of the cutaneous surface where the epidermis is well developed and destitute of hairs, the **stratum corneum** differs somewhat from its usual condition in being composed chiefly of large distended bladder-like cells, which probably represent the superficial **epitrichial layer** of the embryonal skin. Where the epidermis is thin the stratum granulosum is imperfect, the stratum lucidum is wanting, while the superficial cells rapidly dry.

Pigment-granules are widely distributed throughout the epidermis, but it is especially within the deeper layers of the **stratum Malpighii** that accumulations are found to which the dusky hue of the skin of many races is due. The pigment-granules usually originate within the epithelial elements; in some cases, however, they are

conveyed to the epidermis by means of migratory cells. The **dark tint** of the skin of the negro and of other colored races depends almost entirely upon the pigment **within the epidermis,** since in the adult integument the subepithelial tissue contains comparatively few pigmented cells. While microscopical examination shows the presence of pigment some weeks before birth, the dark color is usually not evident until a day or two afterwards, owing to the opaque layer of moist superficial scales which masks the underlying colored cells.

FIG. 301.

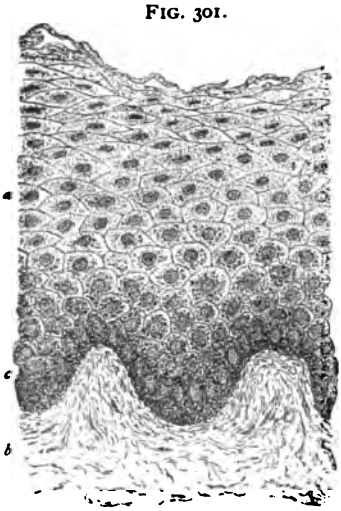

Section of negro's skin, including epidermis (*a*) and papillary layer of corium (*b*); the deepest layers of epidermis (*c*) contain the pigment.

The **corium, derma,** or **true skin** consists of a felt-work of bundles of white fibrous connective tissue, with which elastic fibres and non-striped muscle are mingled in varying amounts. The corium is densest in its outer part, where beneath the epidermis it is beset with **papillæ,** which greatly extend the sensory surface and form the principal organ of tactile sensibility. The deeper parts of the corium are much looser in structure, since the bundles are coarser and more loosely disposed, fading away into the subcutaneous tissue. These differences have led to the recognition within the corium of an outer, denser **stratum papillare** and an inner, looser **stratum reticulare**; no sharp demarcation exists between the two, the papillary layer blending with the reticular, while the latter in turn passes gradually into the tissues of the subcutaneous stratum.

The **papillæ** vary in size, number, and disposition in different regions, being best developed and most numerous on the palmar surface of the hands and the fingers and on the corresponding parts of the feet, where they attain a height of .25 mm.; on the other hand, the papillæ may be very slightly developed or even absent. These elevations consist of closely-arranged bundles of fibro-elastic tissue, and support the **vascular loops** together with the rich **terminal nerve-supply**; in certain localities the latter includes the highly-specialized tactile corpuscles of Meissner, the corpuscles of Vater, and the various end-bulbs which already have been described in Chapter VI. The **simplest type** of the papillæ is the rounded or blunted conical elevation, but very often such projection becomes

cleft and converted into one of the **compound variety.** The papillæ of the hand and the foot are distributed in **characteristically-arranged rows,** which form elaborate, and for each individual constant and distinctive, ridges on the integumentary surface. These ridges have been found to retain their definite arrangement, or "patterns," from early life to old age unchanged. This constancy in the details of the surface markings has been taken advantage of in securing records by means of impressions for the purposes of identification.

Non-striped **muscular tissue** occurs within the **corium** in connection with the hair-follicles, as the **arrectores pilorum,** and in the **subcutaneous tissue,** attached to the under surface of the corium, in particular localities, as in the scrotum, the perineum, the penis, and in and around the nipple.

The **subcutaneous stratum** consists of a reticular framework of loosely-disposed fibro-elastic bundles continued from those of the deeper layers of the corium without sensible interruption ; the **interfascicular spaces** are largely occupied by adipose tissue, which in many places forms a compact layer, the **panniculus adiposus.** The cellular elements of the subcutaneous tissue are the usual cells of connective tissue, including **fusiform** and **plate-like elements, leucocytes,** and **fat-cells** : while the latter are quite constant constituents of the deeper layers of the skin, within the integument of the eyelids, the penis, and the labia minora **fat does not occur.**

THE APPENDAGES OF THE SKIN.

These include the **nails** and the **hairs,** together with the **cutaneous glands,** all of which are directly derived from the ectodermic epithelium of the epidermis.

THE NAILS.

Each nail consists of a large exposed **body,** which ends anteriorly in the projecting **free edge,** and extends posteriorly as the **root** some considerable distance beneath the overhanging upper margin of the groove, or **nail-fold,** receiving the root ; at the sides the borders of the nail are covered by the **nail-walls.** The nail, which represents an enormously developed **stratum lucidum,** rests upon a highly vascular and sensitive **nail-bed,** the posterior portion of which, covered by the root of the nail, is the **matrix.** The **nail-root** is usually lighter in color and somewhat opaque, owing to the thickness of the stratum Malpighii ; on the thumb it extends beyond the nail-fold as a pale projecting convex area, the **lunula.**

While attached throughout the extent of the nail-bed, the **growth** of the nail takes place from the **matrix alone,** each newly-formed

increment pushing before it the older already existing parts at the rate of about one millimetre per week.

The **nail-bed** comprises the **corium** and that portion of the epidermis corresponding to the **stratum Malpighii.** The corium consists of the usual bundles of fibro-elastic tissue, which are arranged somewhat parallel to the long axis of the finger, the longitudinal bundles being supplemented by vertical ones extending from the periosteum of the phalanx to the superficial layers. The minute elevations

FIG. 302.

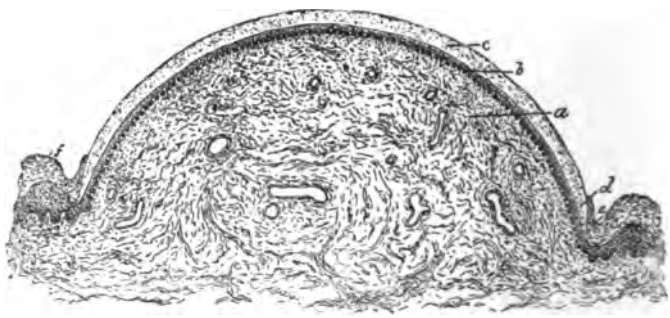

Transverse section of child's finger, including the nail: *a*, connective tissue of corium; *b*, longitudinally corrugated nail-bed; *c*, corneous tissue constituting body of nail; *d*, its thin edge covered by tissue of nail-wall (*f*); *e*, point where stratum Malpighii becomes continuous with nail-bed.

which occupy the surface of the corium in transverse section are no true papillæ, except posteriorly over the matrix, but **longitudina ridges.** They are lowest behind and gradually increase in heigh towards the front of the nail, terminating abruptly at the point wher the latter parts from its bed. The **epithelial portion** of the nai bed is principally composed of cells belonging to the stratum Ma pighii, whose numerous layers fill up the inequalities between th papillæ and the ridges of the corium below, and are sharply define from the substance of the nail above. The transformation of th deeper cells into the horny plates of the nail takes place **only ov the matrix,** where the constantly-recurring division of the epith lial elements furnishes material for the growth of the nail. Th **nail-fold** and the **nail-wall** have the same general structure as t skin.

The **substance of the nail** itself consists of intimately unit lamellæ of **horny epithelial cells,** which possess a nucleus a closely resemble the elements of the **stratum lucidum;** the old and most superficial layers are made up of compressed horny d scales, while those composing the last formed and hence deepest layer are softer and more regularly polyhedral, resembling the cells of the stratum Malpighii.

THE HAIR.

The hairs, together with their homologues, feathers and scales of the lower animals, are **derived entirely from the epidermis**, and are therefore of **ectodermic origin.** These slender flexible horny threads are distributed, with few exceptions, over the entire surface, but differ greatly as to both size and frequency in various regions; individual and race peculiarities also greatly influence the character of the hair. In general, in **straight-haired races** the hairs are thicker and coarser and more cylindrical than in crisp-haired races;

FIG. 303.

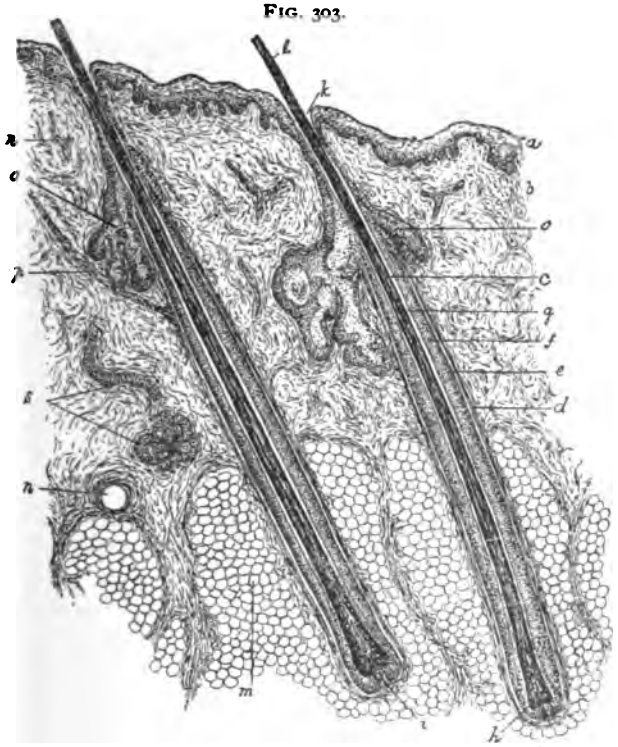

Section of human scalp, showing hair-follicles and sebaceous glands: *a*, epidermis; *b*, corium; *c*, hair embraced within its hair-follicle; *d*, fibrous sheath of follicle; *e*, glassy membrane; *f*, outer root-sheath; *g*, inner root-sheath; *h*, expanded terminal bulb of hair; *i*, hair-papilla; *k*, mouth of follicle from which hair-shaft (*l*) projects; *m*, adipose tissue; *n*, blood-vessel; *o*, sebaceous glands; *p*, arrector pili muscle; *s*, portions of sweat-gland.

in the negro the hairs are flattened cylinders, small and oval in section; dark hair is usually coarser than that of light color.

Every hair presents **two principal divisions,** the part which projects beyond the surface, as the **shaft,** and the portion embedded

within the integument, the **root**; at its lower extremity the root terminates in a bulbous expansion, the **hair-bulb**, which at its lowest point is indented to receive the connective-tissue **papilla**. The hair-bulb lies embraced within a pocket of modified integument, the **hair-follicle**, to which the corium and the epidermis contribute respectively the fibrous and the epithelial root-sheaths.

The **hair** consists entirely of epithelial cells disposed as three distinctly defined strata, the **cuticle**, the **cortical substance**, and the **medulla**, or **pith**. The **hair cuticle** is composed of a single layer of thin, **horny, imbricated scales**, which envelop the entire surface of the hair, both on the root and on the shaft; in these situations it forms a layer respectively 6–8 μ and 2–4 μ in thickness. Owing to the imbricated arrangement of the cells, as tiles upon a roof, only their free projecting borders are visible, which produce in surface views the characteristic **oblique transverse markings** so distinctive of hair; in profile the edges of the cells appear as **delicate serrations**.

FIG. 304.

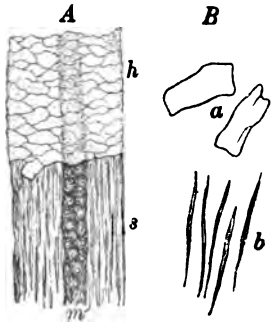

A, human hair; the upper half of the figure represents the superficial horny cells (*h*) constituting the cuticle, the lower half, the fibrous structure of the cortical substance and the medulla; *B*, isolated elements of the hair; *a*, cuticular scales; *b*, thin fibre-cells of cortical substance.

The **cortical substance** constitutes by far the greater part of the hair, when the medulla is wanting sometimes forming its entire bulk. This portion of the **hair-shaft** is composed of greatly **elongated horny epithelial cells**, which possess attenuated nuclei and are so intimately united that the boundaries of the individual elements under ordinary circumstances are not distinguishable. On the **root** the cells are broader, less horny, and assume more and more the character of the elements of the stratum mucosum as the proximal end of the hair-bulb is approached; immediately **around the papilla** the cells of the cortical substance become continuous with the extension of the stratum mucosum, the outer root-sheath.

The **medulla**, or **pith**, occupies the central tract of the hair-shaft, and extends in favorable examples from near the hair-bulb almost to the extremity of the hair. Many hairs possess **no pith**, this part being usually wanting in the **fine hairs** of the general body-surface and the **colored hairs** of the head, as well as in the **hairs of children** under four or five years of age. In the thick short and in the robust long hairs, likewise in most white scalp-hairs, the medulla is present, and constitutes sometimes one-third of the diameter of the hair.

The **medulla is composed** of rows of irregular cuboidal or spherical cells, 15–20 μ in diameter, filled with dark granules, which really are **minute air-vesicles**; by reflected light the pith appears silvery-white, while by transmitted light it is dark and opaque. The air gains access to the medulla in consequence of the partial drying out of the soft protoplasm of the cells. In many animals the **medulla-cells** form a conspicuous and relatively large portion of the hair, and present characteristic details sufficiently distinctive to determine the kind of animal from which the specimen was obtained.

The **color of the hair** depends upon the presence of **pigment-granules, diffuse pigment,** and **air.** The **granular pigment** occurs as colored particles varying from light brown to black; in **dark hair** the pigment lies within the elements of the cortical substance, as well as often between the cells, the cortex in addition sometimes containing diffuse soluble coloring-matter in combination with the protoplasm of the cells. **Diffuse pigment** is entirely wanting in white hair, is sparingly present in light blond hair, and exists in abundance in dark blond, red, and dark hair.

The **hair-follicles** are tubular or flask-shaped depressions within the integument (2–7 mm. in length) which tightly embrace the hair-shafts; those of the finer hairs lie entirely within the corium, while those of the large hairs frequently extend deeply into the subcutaneous stratum.

The hair-follicle serves the double purpose of supplying the tissue from which the hair is formed and of affording the necessary attachment and support to the hair after its development. The relation of the hair-follicle to the general integument is best appreciated by remembering that the **follicle develops** by an **ingrowth of the epidermis** into the subjacent connective tissue; the hair subsequently appears as the result of the metamorphosis and the differentiation of the cells occupying the most dependent part of the epidermal plug. While in the follicles of the finer hairs the epithelium forms almost the entire structure, in those of the large hairs the surrounding connective tissue takes part to the extent of supplying a strong protective sheath, the fibrous coat.

FIG. 305.

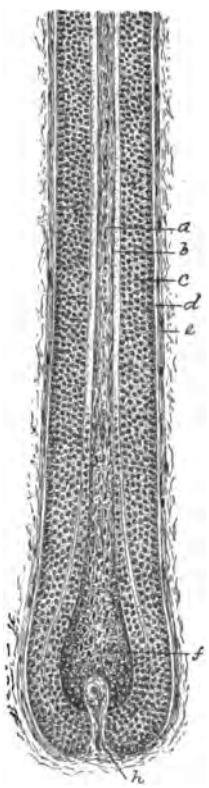

Hair-follicle from human scalp: *a*, hair; *b*, inner root-sheath; *c*, outer root-sheath; *d*, glassy membrane; *e*, fibrous sheath; *f*, hair-bulb; *h*, hair-papilla.

Below the openings of the sebaceous glands the **hair-follicle consists** of the fibrous coat and the stratum mucosum of the epidermis only: at its upper extremity the stratum corneum additionally takes part in the formation of the follicle. The **fibrous coat** of the follicle consists of three layers: the **outer,** composed of longitudinally-placed bundles of connective tissue, rich in cells, and representing a condensation of the tissue of the corium; the **middle,** represented by a layer of circular connective-tissue bundles continuous with the papillary layer of the cutis; and the **inner,** a clear, homogeneous, narrow but conspicuous zone, the **glassy** or **hyaline membrane.** The latter separates the epithelium from the surrounding fibrous tissue, and corresponds to a highly-developed **basement-membrane.** These layers of the fibrous sheath are not continued to an equal extent over the hair-follicle; the outer longitudinal layer completely invests the follicle, becomes continuous with the corium, and materially aids in maintaining the form of the follicle. The circular

FIG. 306.

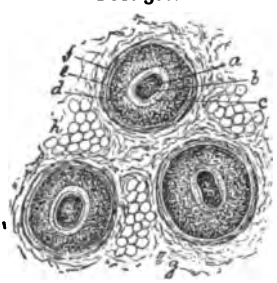

Transverse sections of hair-follicles from human scalp: *a*, hair; *b*, cuticle of hair; *c*, *d*, inner and outer root-sheath; *e*, glassy membrane; *f*, fibrous sheath; *g*, surrounding connective tissue of corium; *h*, fat-cells.

FIG. 307.

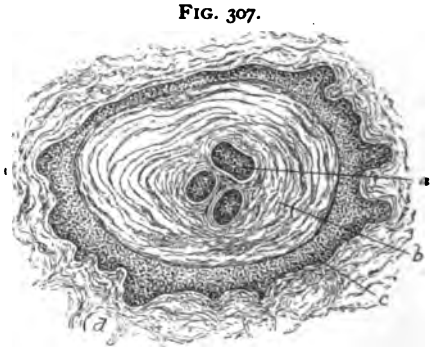

Transverse section of hair-follicle from human scalp; plane of section passes through mouth of follicle: *a*, one of the hairs; *b*, horny tissue of superficial layers of epidermis; *c*, cells of stratum Malpighii; *d*, surrounding connective tissue.

layer extends from the base of the hair-follicle to the orifices of the sebaceous glands, while the glassy membrane, as such, ceases at the mouth of the follicle.

Next inside the glassy membrane follow the epithelial layers occupying the entire space between the hair and the sides of its follicle. The epithelial tissue is disposed in **two well-marked strata,** the thicker, many-layered zone next the glassy membrane, which constitutes the **outer root-sheath,** and the much thinner concentric layer composing the **inner root-sheath.** The former is the direct **prolongation of the stratum mucosum** of the general integu-

ment, while the latter is derived from a part of the same cells that form the hair itself, and is therefore closely related to the hair.

The **outer root-sheath** being the direct continuation of the stratum mucosum of the adjacent skin, its structure corresponds with that layer of the epidermis; when well developed, as in the follicles of the larger hairs, this sheath measures 40–60 μ in thickness, or more than twice the breadth of the inner root-sheath. In the upper part of the follicle, where the glassy membrane and the circular fibrous layer are wanting, the outer sheath rests directly in contact with the longitudinal layer. The **outer cells** of the root-

FIG. 308.

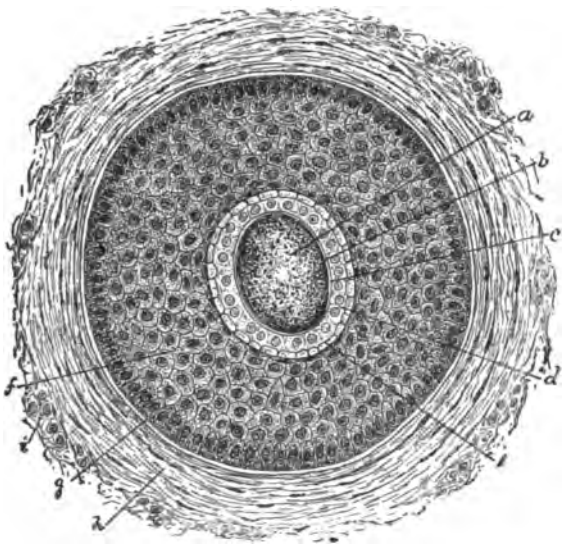

Transverse section of hair-follicle from human scalp, more highly magnified: *a*, substance of hair, condensed at periphery (*b*); *c*, cuticular layer, composed of cuticles of hair and of inner root-sheath; *d*, *e*, respectively layer of Huxley and of Henle; *f*, outer root-sheath; *g*, glassy membrane; *h*, *i*, circular and longitudinal bundles of fibrous sheath.

sheath **are columnar** and placed vertically upon the glassy membrane, while the **cells of the succeeding layers,** some five to ten deep, present the **polygonal outlines** and the intercellular connecting threads seen in the corresponding parts of the ordinary epidermis. The space between the outer root-sheath and the hair is occupied by **three narrow zones,** which collectively form the **inner root-sheath,** a clear transparent rigid membrane closely embracing the lower two-thirds of the hair-follicle and terminating in the vicinity of the opening of the sebaceous gland. The outer or **Henle's layer** appears as a light band composed of somewhat elongated

polyhedral cells, whose protoplasm is very faintly granular and whose nuclei are wanting. Next follows **Huxley's layer,** consisting of a single or double row of shorter and broader polyhedral cells, which ordinarily display small nuclei; at the lower part of the follicle these cells contain numerous granules, probably of **eleidin.** Of the 15–35 μ representing the entire thickness of the inner root-sheath, **Henle's layer** contributes about one-third, the remaining two-thirds being made up by the **layer of Huxley.** The inner surface of Huxley's layer is covered with the clear delicate **cuticle of the root-sheath,** a single layer of thin transparent plates lying against the cuticle of the hair in such close relation that the two cuticular layers appear as one. The **cells** of this envelope are imbricated in a manner similar to those of the hair-cuticle, but the free edges of the plates are directed in the opposite direction from those of the hair, the serrations of the cuticle of the root-sheath fitting into the impressions on the surface of the hair.

The extremity or base of the hair-follicle presents a deep invagination for the reception of the process of dermal connective tissue constituting the **hair-papilla.** The latter is a large, simple, club-shaped elevation, .1–.3 mm. in length, which usually contains numerous **connective-tissue-cells** and loops of **blood-vessels.** The presence of **nerves** within the papillæ, on the contrary, is very doubtful.

The most interesting as well as important part of the hair-follicle is **immediately around the hair-papillæ,** since to the differentiation of the soft granular polyhedral cells occupying this position the hair, together with the inner root-sheath, owes its formation. These elements are the **direct derivatives** of the **stratum mucosum** and represent the **centre of greatest activity;** the elements directly over the papilla supply the material from which the hair proper is developed, while the cells at the lower part of its sides become transformed into the layers of the inner root-sheath. For some distance immediately above the summit of the papilla, polyhedral cleated granular, and often pigmented, cells compose a matrix from which the constituents of the cortical and medullary portions of the hair are directly derived.

The **muscles** of the hairs, the **arrectores pilorum,** exist as minute flattened plexiform **bundles of non-striped muscle,** which extend from the most superficial parts of the corium to the follicles; the muscular band is attached to the fibrous coat of the follicle, below the sebaceous glands, on the side towards which the hair is directed. When the muscle contracts the obliquely-placed follicle becomes perpendicular and the shaft erect, in consequence of which the integument attached about the hair is drawn up, producing the well-known condition of **cutis anserina,** or "goose-

Muscular slips frequently encircle the lower part of the follicle, while additional bands sometimes are given off to find attachment in the fibrous sheath of the sweat-glands.

THE SEBACEOUS GLANDS.

These structures occur so **closely connected with the hair-follicles,** into which they usually open, that the sebaceous glands may be looked for wherever hairs exist; in addition, the glands may be present when hair-follicles are absent, as on the external genitalia (labia minora, glans and prepuce of the penis), the eyelids (Meibomian glands), and the red edge of the lips. The **smallest sebaceous glands** are connected with the head-hairs, while the **largest** are found on the mons Veneris, the labia majora, and the scrotum. The size of these structures is **not proportionate** to that of the associated hairs, since frequently the fine lanugo hairs possess large glands, a relation also seen in the particularly well developed sebaceous sacs connected with the fine hairs on the nose and the face. The group of acini is usually placed on the side towards which the hairs slope, and occupies the interval between the hair-follicle and the arrector pili muscle, the contractions of the latter aiding in the expulsion of the secretion of the gland.

FIG. 309.

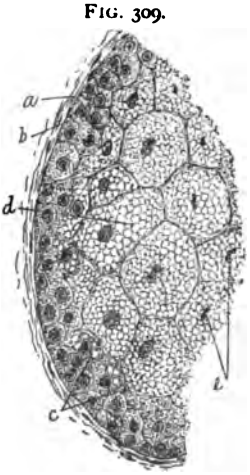

Section of portion of sebaceous gland from human scalp, including part of acinus: *a*, membrana propria; *b*, peripheral layer of cuboidal cells; *c*, elements in which fatty metamorphosis is beginning; *d*, cells filled with fatty particles and exhibiting marked intra-cellular net-works; *e*, nuclei of cells.

The **sebaceous glands** are sometimes simple but usually small compound saccular structures possessing short **ducts** which open into the hair-follicles near their upper extremities. The periphery of the **acini,** five to twenty in number, is lined by a peripheral layer of **cuboidal epithelium,** while the greater part of the sacs is filled with cells in various stages of **fatty metamorphosis.**

The **secretion** of these glands, the **sebum,** when fresh at the body-temperature, is a semi-fluid substance consisting of oil-droplets and the *débris* of broken-down cells; on exposure to the atmosphere it becomes of the consistence of tallow.

THE SWEAT-GLANDS.

The sweat or sudoriparous glands are **modified simple tubular glands** which extend from the free surface of the integument, where

they open by the trumpet-shaped orifices of their wavy ducts to the deepest part of the reticular layer of the corium, or still farther into the subcutaneous stratum, in which position the gland-tube ends as a greatly convoluted spherical mass. The sweat-glands enjoy a **very wide distribution,** being present in greater or less abundance over the entire body-surface, with the exception of the deeper parts of the external auditory canal and the tympanic membrane.

The **largest sweat-glands** occur in the axilla, at the root of the penis, on the labia majora, and around the anus. While the average diameter of the gland-masses is .3–.4 mm., the axillary glands measure 2–7 mm. at their widest part. Each sweat-gland presents **two divisions,** the greatly convoluted **gland-coil** and the much straighter, slightly wavy **excretory duct**; the former, which represents the **secreting portion** of the gland, is much wider, both in its general diameter and lumen, than the part constituting the duct. The **gland-tube** is limited by a membrana propria continuous with that of the skin, outside of which a delicate connective-tissue envelope gives additional strength; within the basement-membrane **cuboidal** or **low columnar epithelial cells** form the lining of all parts of the gland. In the **secreting division** of the tube the low columnar cells are disposed as a **single stratum,** while those lining the **duct** are arranged as a **double layer** of small and low polygonal elements; the cells of the duct are covered next the lumen of the tube with a delicate **cuticle.**

The **duct** from the secretory portion of the gland to the epidermis maintains an almost constant diameter (20–25 μ); on **entering the epidermis,** however, it enlarges to almost double, and on reaching the **stratum corium** expands into the trumpet-shaped orifice which marks its termination. Within the epidermis the duct **loses its distinct walls,** the final turns of its spiral, corkscrew-like course being **bounded by the horny plates** of the epidermis. In exceptional cases the sweat-glands open into the upper part of the hair-follicles, but, as a rule, they reach the free surface by entering the epidermis in the **depressions between the papillæ** of the corium.

The terminal **secretory segment** of the gland-tube, usually single, although sometimes branched, is convoluted to form the characteristic coils, which can be seen often with the unaided eye as reddish-yellow spherical masses. The **columnar secreting cells** (10–20 μ in height) present a single layer of elements whose protoplasm is very finely granular and sometimes contains **fatty granules,** as well as **yellow** or **brown particles**; these latter are especially evident in the ceruminous glands of the external ear, the axillary and the mammary areolar glands. The nuclei of the secreting cells

are eccentrically placed, while the border of the cells next the lumen presents a thickened edge sometimes described as a **cuticle.**

Immediately outside the epithelial cells, between these and the basement-membrane, lies a thin layer of **involuntary muscle**; this tissue occurs only in the secretory division of the tube, and is best developed in the larger glands, where the muscle-cells form a complete layer. The **individual convolutions** of the tube constituting the coil are held together by delicate connective tissue, which additionally furnishes a **fibrous envelope** for the entire mass. The average **diameter** of the secreting portion of the gland is about 65 μ, of which about 30 μ are contributed by the epithelial lining, and about half as much by the fibrous and muscular tunics; the remaining 20 μ represent the usual lumen.

FIG. 310.

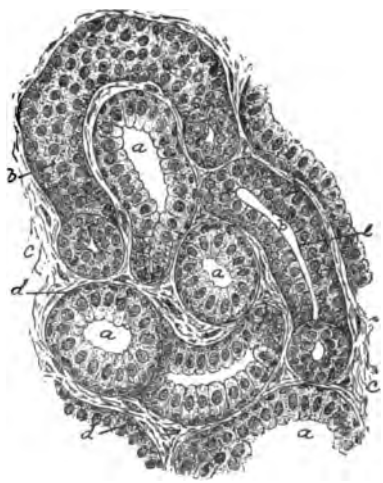

Section of coiled part of sweat-gland from human skin: *a*, *a*, secreting portion of tubule, cut in various directions; *b*, *b*, parts representing beginning of duct; *c*, intertubular connective tissue; *d*, layer of involuntary muscle inside the basement-membrane; *e*, cuticular border.

The **secretion** of the sweat-glands varies with the locality and the character of the glands; in general the secretion of these structures occurs in two forms,—as the **colorless, slightly turbid fluid,** devoid of morphological constituents, which is elaborated by the smaller glands and is the sweat proper, and as the thicker **oily substances** supplied by the large axillary, the circumanal, and the ceruminous glands. The products of these structures consist mostly of water, but contain, in addition, about 1.2 per cent. of solids, including fat, fat-acids, albuminous matters, urea, and salts in various proportions and combinations.

The **ceruminous glands** of the ear and the **glands of Moll** of the eyelid must be regarded as modified sudoriparous glands, since they closely correspond to the sweat-tubes in structure.

The **total number** of sweat-glands of the human body has been estimated to be about two millions (Krause); they are **most numerous** on the palms of the hands, in which situation 373 occur within a single square centimetre, and are almost as frequent on the soles of the feet; the glands are **most sparingly distributed** over the back and the buttocks, where less than sixty are contained within one square centimetre.

BLOOD-VESSELS, LYMPHATICS, AND NERVES OF THE SKIN.

The **blood-vessels** supplying the skin are arranged as **three sets,** which occupy different levels, and are destined especially for the structures lying within the respective layers. The **larger arterial vessels** run between the superficial fasciæ and the integument, generally parallel to the latter, while perpendicular branches are given off which pass towards the free surface and early in their course provide twigs for the supply of the deep-lying **fat-clusters,** among which the arterioles break up into the capillary net-works. At a somewhat **higher level** branches are given off to the **sweat-glands,** superficially to which a net-work is formed by the terminal branches of the ascending arteries, and constitutes a rich **subepithelial reticulum** distributed to the outermost stratum of the corium. Where well developed, the **papillæ** receive vascular tufts and loops from the subepithelial net-work, the disposition of the loops corresponding with the simple or compound character of the papillæ. Numerous twigs also provide for the nutrition of the **hair-follicles,** around which the longitudinal arterioles are connected by the transversely-disposed capillary net-works encircling the follicles; loops are given off to supply the hair-papillæ, as well as small branches to the sebaceous glands and the hair-muscles. The **veins** follow the general arrangement of the arterial branches. The follicles of the conspicuous **tactile hairs** of the lower animals are surrounded by the large **venous spaces** which occupy the cavernous tissue situated between the longitudinal and the circular coat of the fibrous sheath.

The numerous **lymphatics** of the skin are arranged in **two general sets,** those extending **within the corium** and forming the superficial reticulum, and those situated **within the subcutaneous tissue** and following the larger blood-vessels. The **superficial lymphatics** begin as the interfascicular clefts of the corium, some of which are contained within the papillæ; these irregular spaces, with their imperfect lining of connective-tissue plates, communicate with the more definite lymph-vessels, which anastomose to form the plexus extending throughout the corium slightly beneath the plane of the closer-meshed reticulum of blood-capillaries. **Special net-works** of lymph-capillaries surround the **hair-follicles** and the **glands.** The **deeper set** of lymphatics lie within the subcutaneous tissue and constitute a loose reticulum of larger vessels, which freely communicate with the closer superficial lymphatic net-works as well as with those surrounding the adjacent hair-follicles and the glands. Each of the larger blood-vessels is usually **accompanied by two lymphatic trunks** of considerable size, which, by means of numerous transverse branches, freely communicate and enclose the blood-vessels within their meshes.

The **nerves** supplying the skin vary greatly in different regions, the palmar surface of the fingers and the corresponding parts of the toes receiving the richest supply. The **larger stems** lie within the subcutaneous tissue, from which, in addition to twigs distributed directly to the **sweat-glands** and the **involuntary muscle,** numerous branches accompany the blood-vessels into the corium to end in various ways. Upon reaching the superficial portions of the corium, after having given off many lateral branches, the ascending twigs break up into bundles, which form a rich **subpapillary plexus,** containing both medullated and pale fibres, and extending beneath the epidermis and the bases of the papillæ. The **non-medullated fibres** are probably destined for the involuntary muscle of the cutis, the glands, and the blood-vessels; the **medullated fibres,** on the other hand, are connected with several forms of **special nerve-endings.** From the superficial plexus within the corium small twigs ascend to the epidermis, some fibres ending immediately **beneath the epithelium,** while others pass for different distances **between the epithelial elements** to terminate either as **free endings** or in connection with the **tactile cells.** The branches from the subpapillary plexus which ascend into the **papillæ** are connected with the large **tactile corpuscles of Meissner** which occupy the non-vascular papillæ. Within the **subcutaneous layer,** in many regions, numerous **corpuscles of Vater** are present. The **hair-follicles** receive a considerable part of the nerves of the corium, the medullated fibres forming **loose net-works** around the follicles, which they accompany as far as the sebaceous glands, where they divide into the **naked fibrillæ** which are traceable with certainty as far as the glassy membrane and probably end within the external root-sheath.

THE DEVELOPMENT OF THE SKIN AND ITS APPENDAGES.

The **development of the skin** includes the participation of the **ectoderm** and the **mesoderm,** which contribute respectively the **epidermis** and the **corium.** The history of the epidermis is closely identified with that of the ectoderm. In the earliest stage the latter consists of a **single layer of low cuboidal cells;** later an additional superficial stratum, the **epitrichium,** becomes differentiated, the two layers of the ectoderm probably already indicating the **corneous** and **Malpighian strata** of the future epidermis, although the precise

FIG. 311.

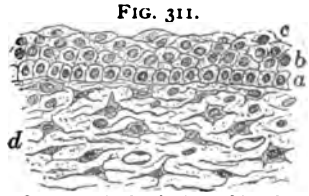

Section of developing skin from human fœtus of three and a half months: *a*, layer of cuboidal cells representing stratum Malpighii; *b*, polyhedral elements forming superficial layers; *c*, outermost flattened plates, probably the remains of the epitrichial layer; *d*, mesodermic tissue forming corium.

relation between the horny layer and the embryonal cells is still unsettled. It is probable that where a well-developed stratum corneum exists the parts of this external to the stratum lucidum represent the metamorphosed epitrichium; where, however, a true cornified layer is wanting and the superficial cells belong to a highly-developed stratum lucidum, as in the nails, the epitrichium is not represented, since in this case the **entire epidermis** is derived from the **deeper layer** of ectodermic tissue (Bowen, Minot). With the general growth the layers of the epidermis increase in number and the **innermost cells** assume the characteristic **columnar character** which continues distinctive of the active Malpighian layer.

The **corium** is formed of **mesodermic tissue** which becomes condensed beneath the epithelial layer and subsequently is beset with numerous **papillary elevations**; the development of vascular structures within the young corium takes place along with the differentiation of a distinct subepidermal zone within the mesoderm. Before the fourth month of fœtal life the **corium** and the **subcutaneous zones** have become defined, and a little later **fat-cells** appear within the last-named layer.

The **development of the nails** depends upon the specialization of the stratum lucidum within certain areas connected with the terminal phalanges. The earliest indication of the nail-formation appears about the third month in the human embryo, and consists of a **thickening of the primitive epidermis** over the end of the digit; the nail-area becomes defined by a **furrow** and takes up a permanent position on the **dorsal aspect** of the finger, when an ingrowth of the **stratum Malpighii** takes place to establish the **root of the nail.** About the fourth month the upper cells of the **Malpighian layer** exhibit granules, which play an important part in the cornification of the epithelial elements in the formation of the nail; these granules are very similar to, if indeed not identical with, **eleidin** in their nature. The cells of the **stratum lucidum** subsequently undergo great increase and constitute the body of the nail. Until about the fifth month the young nail is covered superficially by the epitrichium, here called the **eponychium**; the latter then disappears, and finally is represented only by the small epithelial band, the **perionychium**, which persists across the root of the nail. The final steps in the nail-formation are associated with a process of **desquamation of the stratum lucidum,** whereby the distal end of the nail is separated from its bed and the existence of a free edge is established.

By the addition of young cells at its **posterior margin** the nail grows **in length,** while by the **increments** to its **under surface** derived from the stratum mucosum at the lunula it increases **in thickness**; the **thickest part** of the nail is, therefore, not at its

root, but at the anterior border of the **lunula**; from this point forward the nail remains of constant thickness, since it derives no augmentation in its passage over the nail-bed. The **regeneration** of

FIG. 312.

Section of skin of fœtal kitten, showing earliest stage of development of hair: *a*, epidermis exhibiting thickening and elevation of surface; *b*, mesodermic tissue, showing indications of condensation.

FIG. 313.

Section of skin of fœtal kitten, showing ectodermic tissue (*a*) starting to grow into mesoderm (*b*) as solid epithelial process.

the nail after disease or injury depends upon the **integrity of the deeper layers** of the epithelium.

The **development of the hair** in the fœtus proceeds entirely from the **ectoderm.** The first indication of the process, about the end of the third month, appears as a **localized proliferation** of the ectodermic cells, resulting in a slight transient elevation of the surface, and, at the same time, in a feeble encroachment on the subjacent mesoderm. This ectodermal projection soon becomes an **epithelial cylinder,** whose expanded club-shaped extremity penetrates deeply into the primitive corium to form the **epithelial constituents** of the future hair-follicle. The differentiation of the surrounding connective tissue produces the **fibrous root-sheath,** while a projection opposite the base of the primitive epithelial follicle contributes the tissue of the **hair-papilla.** The region **immediately over the papilla** is the seat of greatest activity and differentiation: the **central cells,** containing probably many **eleidin** granules, become converted into the **hair** and its **inner root-sheath,** while the **peripheral cells** of the

FIG. 314.

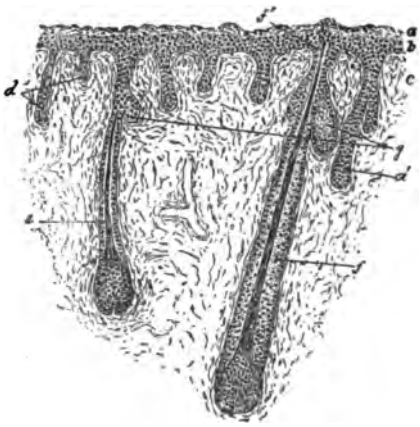

Section of skin of fœtal kitten, exhibiting hairs in various stages of development: *a*, superficial layer of epidermis: *b*, stratum Malpighii from which rudimentary hair-follicles extend into connective tissue (*c*) of primitive corium; *d*, *e*, *f*, hairs in different stages of their development; *g*, sebaceous glands growing from young hair-follicle.

cylindrical epithelial mass assume the character of the **external sheath.** Subsequent **differentiation** in the **central ma** formative cells produces the individua of the inner root-sheath and of th The young hair, or **lanugo,** at first lie pletely embedded **within the epid** its exit being opposed by the cells o ing the neck of the follicle; thes soften and undergo fatty degeneration the young hair forces its way agai superficial epithelial layers. The epi scales at first are raised, but afterwar are broken through by the point tremity of the growing hair-shaft. **eruption** of the hairs on the head a eyebrow occurs about the close of t month of fœtal life, and is completed the sixth month on the extremities. **fœtal hairs,** forming the downy co or the **lanugo,** never possess a medul are short-lived, ceasing to grow t the end of gestation; shortly after, o before, birth these embryonal hai **largely shed** and **replaced** by mo manent successors; on the face and other places, however, the lanugo re The general renewal of the hairs afte corresponds to the periodical change c so common among the lower animals renewal is very unusual in man, the **re ment of the effete hairs** continually place. As soon as the **growth of** a **is arrested** the pressure induced b surrounding soft elastic structures longer resisted, and in consequenc hair is separated and lifted from its p such hairs possess **knob-like extrem** which are lodged in corresponding e sions of the outer root-sheath. B the terminal knob the cells of this **root-sheath** grow out as a **new** towards the base of the follicle; from young cells in due time the **new hair** is formed, the details process corresponding with those of the development of the p

FIG. 315.

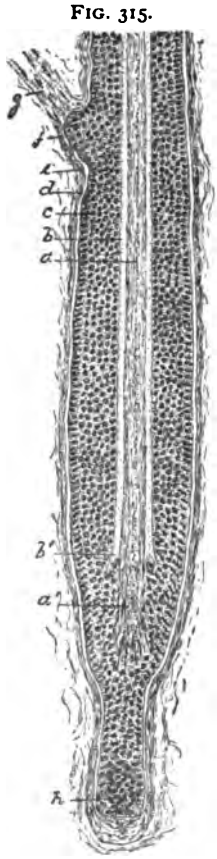

Section of hair-follicle from human scalp, exhibiting changes accompanying growth of new hair: *a*, old hair, terminating in expanded degenerating end (*a'*); *b*, inner root-sheath ending in atrophic area at *b'*; *c*, outer root-sheath; *e*, glassy membrane; *f*, lateral projection marking attachment of arrector pili muscle (*g*); *h*, mass of new cells derived from root-sheath of old follicle from which formation of new hair will proceed.

hairs. Coincidently with the growth of the secondary shaft the old **dead hair** becomes shifted towards the surface, loosened, and finally entirely displaced.

The **development of the sebaceous glands** starts as an **outgrowth** from the **external root-sheath of the hair-follicle,** from which knob-like projections extend laterally; these are at first solid flask-shaped processes, the central cells of which become filled with fat-particles. This fatty metamorphosis affects all the **cells occupying the axis** of the developing gland as far as the root-sheath; after a time the latter structure is penetrated and the degenerated fatty cell-mass discharged into the hair-follicle as the first **sebaceous secretion.** From the original tubular projection **secondary compartments** are produced by a repetition of the processes of budding and subsequent hollowing out until the entire complement of saccules has been formed. After the disintegration of the **central cells,** the peripheral elements undergo similar change.

The **development of the sweat-glands** follows closely that of the hairs and the sebaceous follicles; as in these, so here, the first stage consists in the **ingrowth,** during the fifth month, of a solid epithelial club-shaped process from the **stratum mucosum** into the primitive corium. About the seventh month a **lumen** appears within the tubular mass, an exit, however, for some time being still wanting; subsequently the obstructing epidermal layers are broken through. Somewhat before the appearance of the lumen the extremity of the cylinder undergoes increased growth, resulting in the **thickening** and **convolution** of the tube which represents the future **coiled division** of the gland; the full expression of the characteristic convoluted arrangement, however, is not attained until shortly before birth. The **muscular tissue** of the secretory tubes, situated between the basement-membrane and the lining epithelium, is present before the close of the ninth month; its origin is as remarkable as its position, since the **muscle-cells are derived from** the elements of the adjacent **ectoderm.** The basement-membrane and the fibrous sheath are contributions from the mesoderm.

FIG. 316.

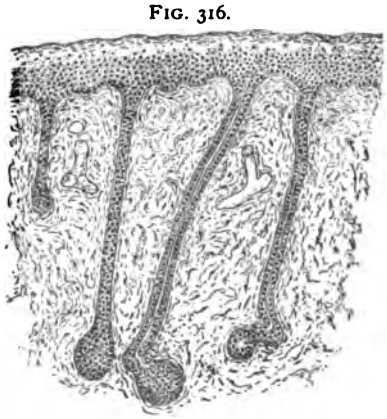

Section of skin of human fœtus, showing developing sweat-glands. The latter grow as epithelial cylinders from the stratum Malpighii of the epidermis into the underlying corium; the characteristic coil appears later.

CHAPTER XVI.

THE CENTRAL NERVOUS SYSTEM.

THE MEMBRANES.

THE spinal cord and the brain are surrounded by their enveloping membranes, the **dura**, the **arachnoid**, and the **pia**; these afford additional protection and support the blood-vessels in their course to the nervous tissue.

The **dura** consists of interlacing bundles of dense **fibro-elastic tissue**, in the interspaces between which lie numerous plate-like **connective-tissue cells**; many irregular granular elements resembling plasma-cells occupy the more superficial layers. The narrow clefts between the fibrous bundles represent **lymph-spaces.**

The smooth **unattached surfaces** of the dura are clothed with a single layer of **endothelial plates**, while the **attached surfaces**, on the contrary, are rough and without endothelium, but covered with **fibrous processes** for attachment. The inner surface of the visceral layer forms the outer wall of the **subdural space**, the inner boundary of which is contributed by the opposed surface of the arachnoid; the two surfaces, while usually in apposition, are united by very few intervening bands of connective tissue. In some places the outer dural layer is less intimately united with the bone than usual, which arrangement produces the **epidural spaces**; a more or less perfect endothelial lining exists at such points.

FIG. 317.

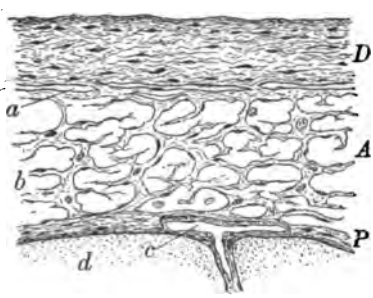

Section of membranes from brain of child: *D*, *A*, *P*, respectively the dura, the arachnoid, and the pia; *a*, subdural space; *b*, meshes of subarachnoidean space; *c*, blood-vessel within the pia sending branch into cerebral cortex, *d*.

The dural layers vary in vascularity in different regions; in addition to the **intradural venous sinuses**, on either side of the superior longitudinal sinus smaller venous clefts, the **parasinoidal spaces**, occur; into these the **cerebral veins** directly open, the entrance of the veins into the sinus being thus indirect. The **arteries** of the dura in many places are surrounded by **perivascular lymphatic**

channels; these canals open into the **sub-** or the **epi-dural spaces** on the one hand, and stand in close relation with the **blood-vessels** on the other. The veins of the dura are of much greater size than the corresponding arteries.

The **nerves** of the dura are not numerous, but consist of both medullated and pale fibres, chiefly distributed to the **walls** of the blood-spaces.

The **arachnoid** is a connective-tissue membrane of great delicacy, the component fibres being loosely held together rather than arranged as distinct bundles. The **free surfaces** of the membrane, including the numerous trabeculæ on its inner side, are covered with **endothelium.** The arachnoid lies closely applied, but slightly attached, to the inner surface of the dura, while between the arachnoid and the pia the considerable **subarachnoidean space** exists.

Scattered over the outer surface of the arachnoid small **villous elevations** project into the subdural space; a core of **connective tissue,** covered by a reflection of the **endothelium,** constitutes these structures. In various situations, but particularly in the neighborhood of the superior longitudinal sinus, the arachnoidal villi become hypertrophied and form the **Pacchionian bodies**: these press against the opposed dural surface and push the latter before them where least resistant; such points occur where the lamina of the dura separate. The **arachnoidal projections** encroach upon the dura to such a degree that its tissue is largely absorbed, the cauliflower excrescence being separated from the venous current by an extremely thin layer. In localities where the projections press against the bones, conspicuous **depressions** on the inner cranial surface mark the positions of the Pacchionian bodies; these latter not infrequently contain small, hard, **calcareous concretions,** the "brain-sand." The arachnoid contains **neither blood-vessels** nor **nerves.**

The **pia** is the vascular membrane, and consists of two lamellæ, an **outer layer,** rich in blood-vessels, and an **inner stratum,** less vascular, but closely associated with the nervous tissue, to which it contributes a partial supporting **framework.** The **pial stroma** is composed of interlacing **fibro-elastic bundles,** between which lie the numerous blood-vessels, surrounded by perivascular lymphatics; the **vessels,** invested by delicate prolongations of both connective tissue and lymph-sheath, pass into the nervous tissue. The free surface of the pia is covered by **endothelium,** as are also the trabeculæ subdividing the subarachnoidean space and connecting the arachnoid and the pia. The pia of the cord is composed of coarser fibres than that of the brain.

The dura and the arachnoid do **not follow** the irregularities of

the surface of the nervous masses; the **pia does,** dipping down into the fissures and penetrating, as part of the velum interpositum, into the interior of the brain. The **inner layer** of the pia is closely united to the surface of the cord and the brain, while the **vascular tunic** in places is less accurately adapted: thus the entire pia enters the anterior median fissure of the spinal cord, while the inner layer alone takes part in the formation of the posterior median septum, or "fissure."

Branched pigment-cells are not uncommon in the outer layer of the pia; these are especially well developed on the anterior surface of the medulla, although frequently found in other positions along the cord and at the base of the brain. A few non-medullated **nerve-fibres** have been traced within the pia.

THE SPINAL CORD.

The **spinal cord,** or **medulla spinalis,** hangs, enveloped by its membranes, within the vertebral canal, and extends from the lower border of the skull, where it becomes continuous with the medulla above, to the lower border of the first lumbar vertebra below; from this level the conical end of the cord, the **conus medullaris,** is continued into the attenuated **filum terminale,** the nervous matter disappearing about the middle of this structure. While the several divisions of the cord are distinguished by individual peculiarities, certain general features of arrangement are common throughout its length.

The cord is formed of **symmetrical halves** partially separated in the mid-line in front by a cleft, the **anterior median fissure,** and behind by an ingrowth of dense neuroglia tissue which constitutes the **posterior median fissure,** but is really only a **fibrous septum. Each half** of the cord contains a **crescentic mass** of gray matter; the convexities of the crescents face, and are connected by a horizontal bridge, the **gray commissure,** the gray matter of the cord thus collectively forming an H-like mass. The horns of the crescents are not equal, the **anterior** cornua being broad and robust, while the **posterior cornua** are more slender and pointed and extend almost to the outer surface.

The **exterior of the cord** is invested by a dense neurogliar layer, from which numerous **fibrous septa** extend into the substance of the cord, dividing the white matter into certain pyramidal areas. The **anterior** or **motor roots** of the spinal nerves are formed by bundles of fibres which escape from the gray matter; these bundles pass from the anterior cornu to the surface of the cord associated in groups, their exit being indicated by **slight furrows.** The position at which the **posterior** or **sensory root** appears on the surface, on the contrary, is marked by a **distinct indentation.**

These furrows marking the anterior and the posterior roots, together with the penetrating processes from the pia, divide the white matter of each half of the cord into definite areas or tracts. The anterior median fissure penetrates a little more than one-third of the diameter of the cord, and does not quite reach the bridge of gray substance, but leaves an intervening band which connects the white matter of the two halves; this constitutes the white commissure included between the gray bridge behind and the anterior median fissure in front.

The part of the cord embraced between the anterior median fissure and the anterior root is the **anterior column**; the large area bounded by the anterior root, the gray matter, and the posterior root forms the **lateral column**; while the field included between the posterior root and the posterior median septum corresponds to the **posterior column.** Since the first two divisions are very closely associated both as to their position and as to their constituents, they are very frequently regarded as a single column, the **antero-lateral.** Each of these principal segments is subdivided into **secondary tracts**, distinguished by names indicating the general course or the destination of the component nerve-fibres.

FIG. 318.

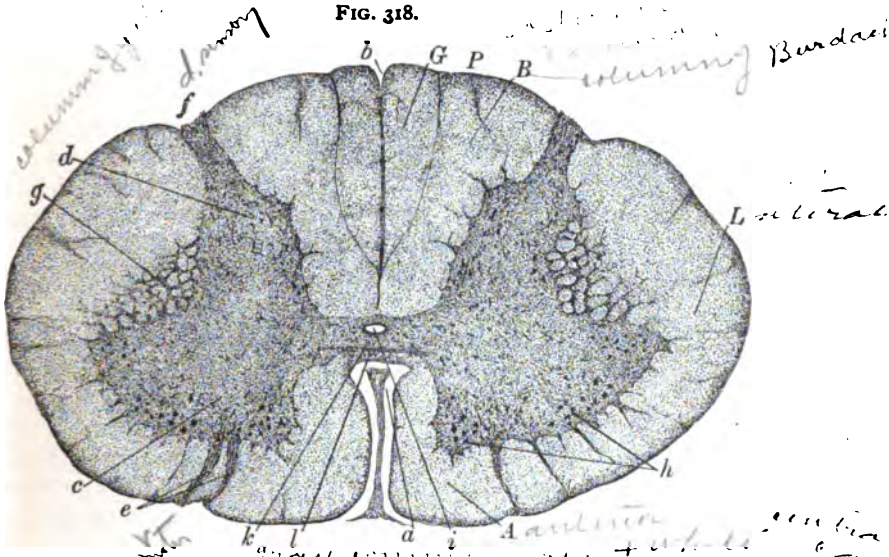

Section of spinal cord from cervical region of child: *a*, anterior median fissure; *b*, posterior median septum; *c*, *d*, anterior and posterior horns of gray matter; *e*, *f*, anterior and posterior nerve-roots; *g*, lateral reticulum of gray substance into white matter; *h*, median and antero-lateral groups of ganglion-cells; *i*, central canal; *k*, *l*, gray and white commissures; *A*, *L*, *P*, anterior, lateral, and posterior columns; *G*, column of Goll; *B*, column of Burdach.

The **anterior column** includes two tracts: the **direct pyramidal tract** (*Türck's column*), next the median fissure, and the

FIG. 319.

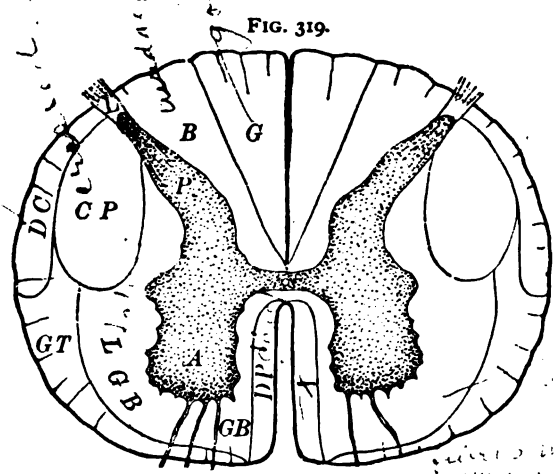

Diagram showing principal divisions of white matter of spinal cord: *A*, *P*, anterior and posterior horns of gray matter; *DP*, direct pyramidal tract; *GB*, anterior ground-bundle; *CP*, crossed pyramidal tract; *DC*, direct cerebellar bundle; *GT*, Gowers's or ascending antero-lateral tract, blending anteriorly with descending antero-lateral tract; *L*, Lissauer's column; *BG*, column of Burdach (fasciculus cuneatus) and column of Goll (fasciculus gracilis); *LGB*, lateral ground-bundle.

anterior ground-bundle, or **anterior radicular zone**, which is continuous with the adjoining area of the lateral region.

The **lateral column** contains a number of important tracts, two of which are especially prominent, the **crossed pyramidal** and the **direct cerebellar.** The **latter** lies as a narrow zone at the margin of the cord, and extends from the posterior root about half-way to the anterior root. The **crossed pyramidal tract** appears as an oval area which lies next the cerebellar path and in front of the posterior root. The remainder of the lateral column is occupied by a number of smaller tracts, concerning which uncertainty still exists. These may be grouped into two segments: an outer peripheral, including the **ascending antero-lateral tract, or tract of Gowers,** and the **descending antero-lateral tract,** and an inner zone, next the gray matter, the **lateral ground-bundle**; the latter, in conjunction with the similar anterior tract, constitutes the **antero-lateral ground-bundle.**

The **posterior column** is divided by a fibrous septum into the inner triangular segment, the **column of Goll,** next the median septum, and an outer area, the **postero-lateral tract**, or **Burdach's column,** lying between Goll's tract and the posterior horn and root.

Lissauer's column appears as a small area capping the apex of the posterior cornua; it consists of fibres from the lateral part of the posterior nerve-roots, which, proceeding from the cells of the spinal ganglia, are passing to higher levels of the cord.

The **framework of the spinal cord** consists of the penetrating **pial processes,** which divide the white matter into numerous areas as well as convey the blood-vessels into the nervous tissue. From the large fibrous partitions finer secondary trabeculæ are given off; these, in turn, divide and subdivide until they become lost as delicate fibrils among the nervous elements. In addition to the framework of connective tissue contributed by the pia, the **specialized supporting tissue** of the nervous system, the **neuroglia,** is distributed throughout the cord, filling up the coarser meshes of the connective-tissue reticulum and intimately uniting the more important nervous elements.

The **neuroglia** occurs immediately beneath the outer pial investment as a condensed **peripheral zone,** from which prolongations accompany the pial septa, as well as intermingle with the nerve-fibres; among the latter lie the characteristic **spider-cells,** sending their long, delicate processes between the fibres.

FIG. 320.

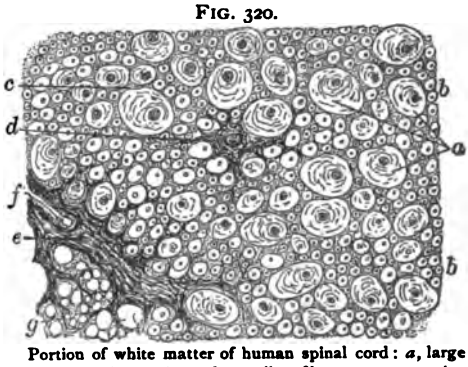

Portion of white matter of human spinal cord: *a*, large nerve-fibres in section; *b*, smaller fibres; *c*, supporting neuroglia; *d*, spider-cell; *e*, connective-tissue trabecula containing blood-vessel, *f*; *g*, spaces from which sections of nerve-fibres have been lost.

The **white matter** of the cord is made up seemingly of great numbers of small round nucleated elements, held together by the supporting neuroglia. These apparent cells are the **nerve-fibres in transverse section,** the supposed nuclei being really the cut axis-cylinders; an irregularly concentric striation is usually present around the axis-cylinder, this appearance being produced by the partial distortion of the medullary substance. The **nerve-fibres** of the cerebro-spinal axis possess **no neurilemma,** the surrounding neuroglia affording the necessary protection.

The **individual nerve-fibres** composing the white matter of the cord vary greatly in diameter (1–27 μ); while the thick and the thin fibres are found side by side in all regions of the cord, certain columns are characterized by the predominance of thick fibres,

while other tracts contain mostly small ones. With reservation, it may be assumed that **motor fibres** are generally the largest (15–20 μ): hence the nerves issuing from the anterior cornua contain principally fibres of large size; the posterior **sensory nerves** and the sensory tracts, on the contrary, contain chiefly small fibres, although a number of fibres of large diameter are usually present. The **largest fibres** occur within the direct and crossed pyramidal tracts; the **smallest,** within the column of Goll.

The **white commissure** in man forms a continuous nervous lamella, .3–.5 mm. in thickness, which separates the gray commissure from the bottom of the anterior median fissure; in many animals the white commissure is incomplete, being represented by isolated commissural bundles found only at certain levels.

The **gray matter,** while presenting the general **H-form** throughout the cord, differs in the details of its arrangement in the several regions. The gray matter shares in the increased size which characterizes the cervical and lumbar enlargements, its amount being absolutely as well as relatively greatest in the lumbar region.

FIG. 321.

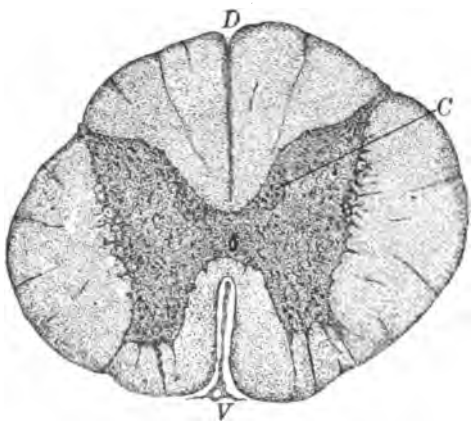

Section of spinal cord from thoracic region of child: *V*, *D*, ventral (anterior) and dorsal (posterior) median fissures; *C*, column of Clarke.

Typical **cervical sections** are distinguished by their large size, great transverse diameter, and large H of gray matter, the anterior cornua of which are robust and broad, while the posterior horns are slender. Sections from the **thoracic region** are smaller than those from either above or below, and present an almost circular outline; the gray matter possesses crescents only slightly curved, with slender horns both in front and behind. Cross-sections of the **lumbar** cord are recognized by being broad, having a deep anterior fissure, and possessing a large, thick H which greatly encroaches upon the white matter. The latter diminishes relatively, as well as absolutely, on reaching the **conus medullaris,** where it is reduced to a mere shell.

The **gray matter** of the halves is united by the **gray commissure,**

in the middle of which lies the minute **central canal**, the direct

FIG. 322.

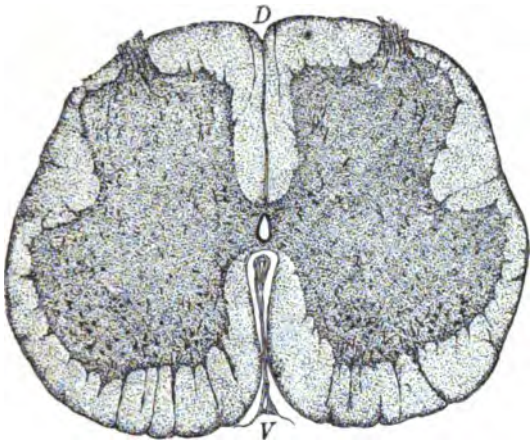

Section of spinal cord from lower part of lumbar region of child: *V*, *D*, ventral and dorsal median fissures.

continuation of the ventricular cavities of the encephalon and the remains of the large **neural canal** of early fœtal life. That part of

FIG. 323.

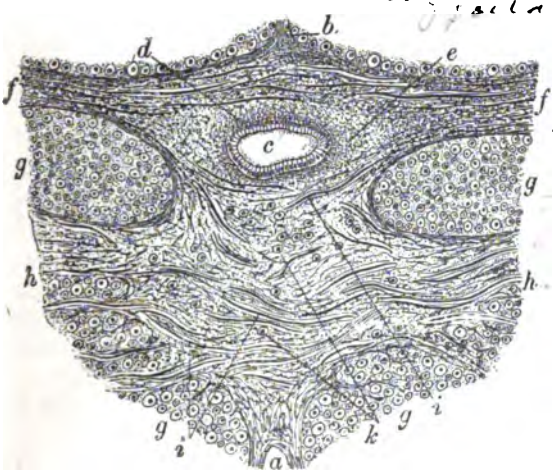

Portion of section of spinal cord of calf, including central canal and commissures: *a*, *b*, anterior and posterior median fissures; *c*, central canal, lined with ciliated epithelium, *d*; *e*, surrounding substantia gelatinosa; *f*, gray commissure; *g*, white matter; *h*, white commissure; *i*, decussating nerve-fibres; *k*, nerve-fibres in section.

the gray commissure lying in front of the central canal constitutes

the **anterior gray commissure,** while that behind the canal is the **posterior gray commissure.**

The **histological elements** entering into the composition of the **gray matter** include the **nerve-cells,** the **nerve-fibres,** the **substantia spongiosa,** the **substantia gelatinosa,** and the **blood-vessels.**

The most conspicuous elements of the gray matter are the **ganglion-cells.** These are especially numerous in the apices of the anterior horns, where they form almost continuous columns. The **motor cells** are largest, those found in the anterior cornu being distinguished by their great size (65–130 μ), as well as by their numerous branched processes. The **ganglion-cells** of the **anterior cornu** are disposed in groups, of which there may be recognized usually a small **median group,** occupying the inner part of the horn, but wanting in the lumbar region, and a conspicuous large **antero-lateral group,** which lies in the outer angle of the horn; the posterior outer angle, where the anterior cornu is broad and well developed, contains often additionally a **postero-lateral** or an **external group.**

FIG. 324.

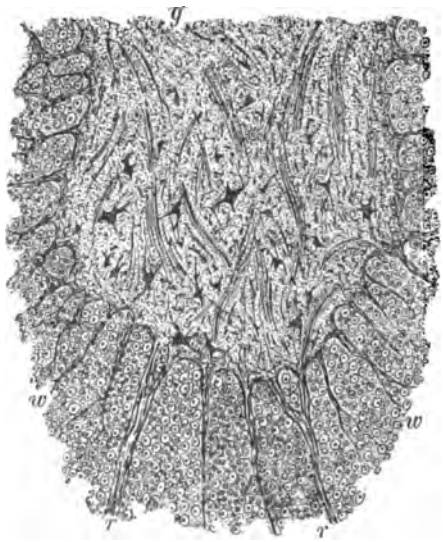

Anterior horn of gray matter of human spinal cord: *g*, gray matter containing stellate ganglion-cells; *w*, white matter penetrated by bundles (*r*) of root-fibres.

The **ganglion-cells** of the **posterior horn** are much smaller (15–20 μ) and irregularly distributed to the outer side of the cornu and within the substantia gelatinosa.

In certain regions of the cord, principally from the eighth cervical to the third lumbar nerve, much less markedly in the upper cervical and in the sacral region, a distinct cluster of nerve-cells exists at the juncture of the posterior root and the gray commissure, which marks the position of the **vesicular column of Clarke.** The ganglion-cells of this tract vary in size (30–90 μ), but possess an average diameter of 70 μ, thus standing midway between the largest motor and the smallest sensory elements; the neurits of these cells pass

ıto the white matter and constitute the nerve-fibres of the
:bellar tract.

:eral horn when well developed, as in the **intermedio-**
act of the tho-
on, also con-
ıps of small,
bipolar, cells
) which re-
: isolated cells
ıterior cornu.
lition to the
f nerve-cells
isolated clus-
'outlying"
-cells exist
he gray sub-
thin the white
the antero-
nd posterior

composition
·ay matter is
:ate, including
ıes not only
es of various
:h medullated
ı-medullated,
tless fibrils of
thickness de-

FIG. 325.

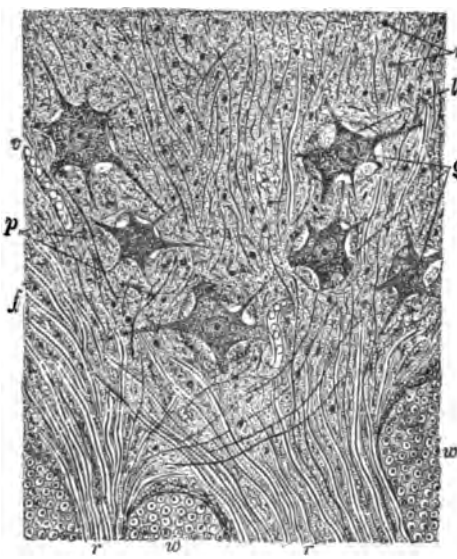

Portion of anterior horn of gray matter of spinal cord of calf: *g*, multipolar ganglion-cells lying within pericellular lymph-spaces (*l*); *r*, *r*, bundles of nerve-fibres (*f*) passing from gray matter to form anterior roots; *w*, white matter; *p*, portions of isolated processes of nerve-cells; *n*, larger processes in section; *v*, blood-vessel.

ı the processes of the ganglion-cells, but also the universally
ıbstantia spongiosa, the modified neuroglia of the gray
hich contributes additional nuclei and fibrils of its own.
ıt advances in our knowledge concerning the processes of
s have introduced new elements of complexity, for it must
bered that, in addition to the richly-branched protoplasmic
, the axis-cylinders contribute numerous fibrils both as the
l fibres and as the net-works of fine **terminal fibres** in
axis-cylinder processes of cells of the second type end.
ation between the various nerve-fibres and the cells of the
er is a question of great difficulty; the researches of Golgi,
Cajal, Kölliker, and others within the last few years have
d that the protoplasmic processes probably **neither anas-**
with one another **nor unite** with nerve-fibres; likewise,
xis-cylinder processes of certain cells are directly continued

as nerve-fibres, these being especially the **cells of the anterior horn**, which are prolonged into the large **motor nerves.**

FIG. 326.

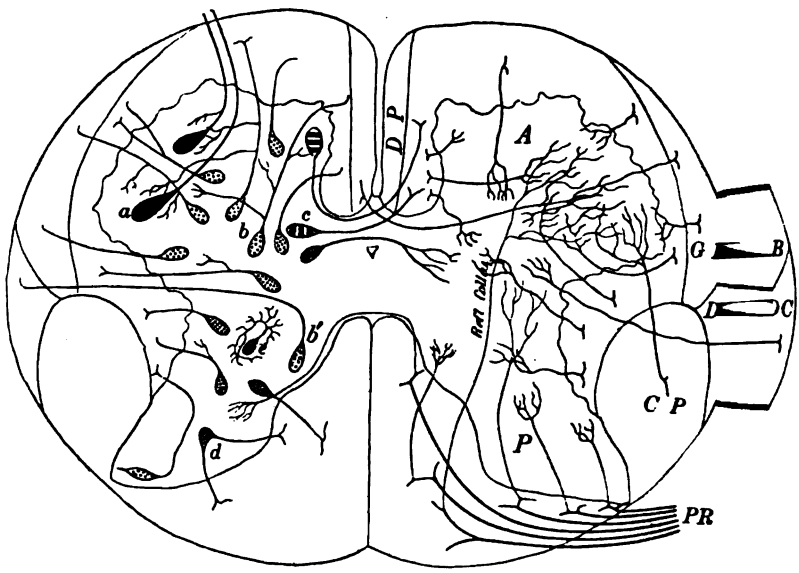

Diagram illustrating the probable relations between the cells and the fibres and the principal tracts of the spinal cord; the left half of the figure exhibits the communications of the several varieties of nerve-cells: *A*, *P*, anterior and posterior cornua of gray matter; *PR*, posterior root-bundles; *DP*, direct pyramidal tract; *CP*, crossed pyramidal tract; *DC*, direct cerebellar path; *GB*, Gowers's tract; *a*, motor cells passing directly into fibres of anterior roots of spinal nerves; *b*, various cells of the antero-lateral column, including elements of Clarke's column (*b'*) and of substantia Rolandi; some give off collateral branches of remarkable size; *c*, commissural cells; *d*, cells to posterior column; *e*, Golgi cells of posterior horn. The right half of the diagram shows the communications established by means of the collateral fibres. (After *Lenhossék*.)

The posterior root-fibres are afferent processes of the nerve-cells situated within the spinal ganglia. On gaining the posterior columns of the cord, the sensory fibres divide into ascending and descending branches, from which collateral twigs are given off at various levels. The collaterals, after a longer or shorter course, pass horizontally into the gray matter, and terminate, in the majority of cases, in arborizations closely related to the nerve-cells of the posterior horn. These latter cells supply the links of communication between the sensory and motor roots, thereby establishing the paths for spinal reflexes. In some cases the sensory fibres traverse the gray matter and end directly in relation to the cells of the anterior horn. While many of the cells of the posterior horn are confined to the gray matter, others send their nerve-processes into the surrounding white matter to form particular tracts of nerve-fibres.

The accompanying diagram, after Lenhossék, illustrates the various groups of nerve-cells now recognized as taking part in the composition of the gray matter, as well as the assumed communications established by the collateral fibres within the cord.

In addition to the nerve-cells and the fibres, the gray matter is everywhere pervaded by the supporting and uniting **substantia spongiosa**; this ground-substance is composed of neuroglia fibres and richly-branched neuroglia cells, the latter being rather more numerous than in the white matter. **Covering the posterior cornu** and immediately **surrounding the central canal** of the cord, the ground-substance is modified to become the apparently almost homogeneous **substantia gelatinosa**; the mass capping the posterior horn, the **substantia gelatinosa Rolandi,** contains some few fusiform nerve-cells and presents a striation produced, in part at least, by the course of the posterior root-fibres. The zone of clear ground-matrix surrounding the central canal of the cord, the **substantia gelatinosa centralis,** markedly differs from that on the posterior cornu, in being composed principally of closely-felted neuroglia fibres ; in certain regions (cervical and dorsal) the gelatinous substance encroaches somewhat upon the gray commissure.

The **central canal** occupies the gray commissure, being continuous with the cavity of the fourth ventricle above, and ending blindly below in the upper half of the filum terminale. The canal does not occupy the centre of the gray commissure, since it lies rather ventrally to that point, especially in the lower part of the cord.

The **columnar epithelium** lining the canal is an extension of that of the cerebral ventricles. In children, and in many animals at all ages, the surface of the cells directed towards the lumen is clothed with **cilia**; the opposite ends of the cells terminate in **long slender processes,** which extend deeply into the surrounding structures. The lining cells represent the **spongioblasts,** which in the embryonic cord closely crowd around the central canal and send long delicate fibres from their outer ends through the cord as far as the pia, while from their inner surface the hair-processes, the cilia, project into the central canal. The **epithelium,** with the **subjacent neuroglia** layer on which the cells rest, constitutes the **ependyma.**

The **form** and **size of the central canal,** which represents the remains of the primitive neural tube, vary in the different divisions: in the upper cervical region its cross-section is somewhat **quadrilateral,** from the level of the fifth cervical nerve becoming oval or **slit-like,** with the cleft placed parallel with the commissure. In the dorsal region the canal gradually approaches the **circular form,** while in the lumbar it once more becomes a **compressed oval,** with, however, the long diameter coinciding with the sagittal plane.

The canal of the sacral cord and of the conus medullaris assumes a **⊥-form**, consisting of a ventral wider arm and a narrow dorsal extension; an irregular dilatation in the lower part of the conus has received the name **ventriculus terminalis.** The cords of children and of many animals contain a **completely pervious** central canal; in the human cord in later life this is usually more or less occluded, although much variation exists in this respect. The upper cervical, lower lumbar, and sacral regions usually contain, even in the adult, a partially pervious tube. Overgrowth of the lining cells, as well as of the subepithelial substantia gelatinosa, is the prin-

FIG. 327.

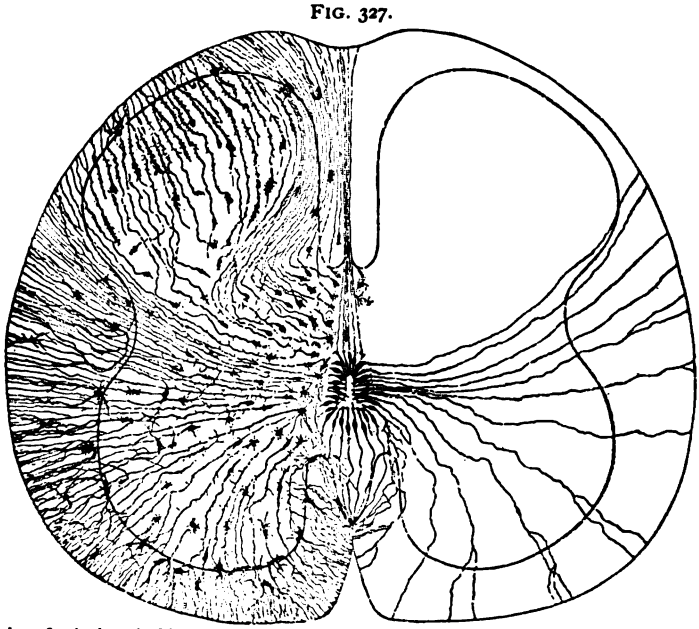

Section of spinal cord of human embryo stained by Golgi silver method; the left half of the figure exhibits the neuroglia-cells, while the right shows the elements constituting the framework of the ependyma. (After *Lenhossék.*)

cipal factor in the closure of the central canal, which, however, must be regarded as a normal change and not a pathological process.

The **blood-vessels** of the substance of the cord are arranged in **two groups**: those **entering at the periphery,** including the larger branches which follow the connective-tissue septa; those **derived from the arteria sulci,** given off from the anterior spinal artery and lodged within the anterior median fissure, from which branches are distributed to the **gray matter.** Of the numerous arteries which enter at the circumference, the **finer** usually terminate

within the white substance, while the **coarser** alone penetrate **into the gray matter,** the outer zone of which they in part supply. The vessel occupying the posterior median septum, the **arteria fissuræ posterioris,** is the most important of the peripheral branches: twigs also accompany the anterior and posterior root-bundles.

At the bottom of the anterior median fissure the **arteria sulci** divides into two **sulco-commissural** branches, which, diverging slightly, enter the gray matter to the inner side of the base of the anterior horn. After a short course within the gray substance, these vessels break up into a number of twigs, which soon form close **capillary net-works** within the anterior and middle parts of the gray

FIG. 328.

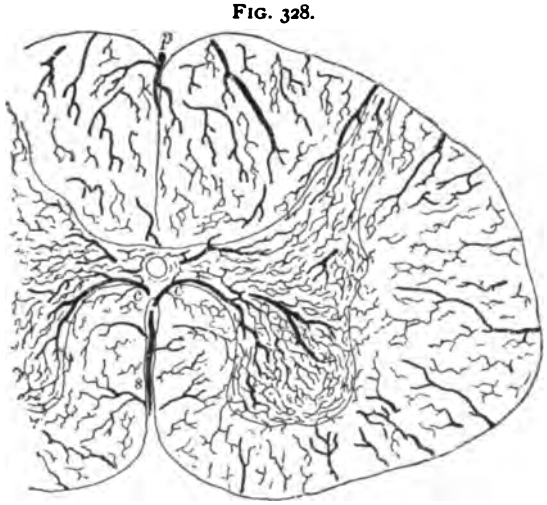

Section of injected spinal cord of child: *s*, sulcal branch of anterior spinal artery occupying anterior median fissure; *c*, *c*, sulco-commissural vessels from sulcal artery passing to gray matter to form dense net-work; *p*, posterior spinal artery, sending off twigs to white matter; around margin of cord numerous peripheral vessels enter white substance to form open net-work.

crescents; a branch of some size passes backward to supply the region corresponding to **Clarke's column.** The sulco-commissural artery likewise gives off **vertical anastomosing branches,** one passing brainward, the other caudalward, to unite with similar offshoots from the corresponding arteries of different planes. The **veins** follow in general the course of the corresponding arteries: some of the blood, however, brought by the sulcal artery is carried off by the peripheral veins.

THE MEDULLA.

The differences between the medulla and the spinal cord are rather of **arrangement** than of any great variation in structural

elements, since the tissues of the cord are prolonged into the medulla, where the increased importance of parts before relatively inconspicuous, together with the addition of new masses of nervous matter, brings about the **redisposition of the structures continued from the cord.** The changes taking place in the transition of the cord into the medulla consist primarily in a **modification of the gray matter**; the principal factors are the **gradual increase** in the size of the tracts of the **posterior column** and the **decussation** of fibres from the lateral column destined to aid in forming the anterior pyramids. The changes wrought by the first factor are earliest indicated, and affect particularly the **posterior cornua** of the gray substance, while the second modifies the **anterior horns.**

FIG. 329.

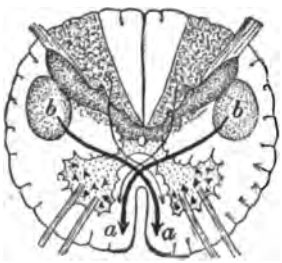

Diagram of spinal cord indicating the paths taken by fibres of crossed pyramidal tract (*b*) to gain the anterior columns (*a*), and by fibres of posterior column (*s*) higher up to form sensory decussation. (After *Testut.*)

An intimation of the changes to follow is seen in sections as low as the first, or even second, cervical nerve in the thickened club-shaped **accumulation of gray matter** representing the posterior cornu, connected by an extended and attenuated stalk with the chief mass. With the progressive increase in the size of the **columns of Goll** (*funiculus gracilis*) and the **columns of Burdach** (*funiculus cuneatus*) the posterior horns are displaced more and more laterally and ventrally until the cornua with their supporting necks lie nearly horizontally, forming almost a right angle with the posterior median septum. The increased mass of the substantia gelatinosa not only approaches the surface, but gradually displays its growth by the formation of the projection known as the **funiculus of Rolando,** which, higher up, expands into the **tubercle of Rolando.** The greater size which the tracts of the posterior column assume is produced by the accession of masses of new gray matter, the **nucleus gracilis** and the **nucleus cuneatus.** These gray nuclei are at first narrow, but become more robust as the medulla is ascended. The ascending fibres of the posterior cord-columns (Goll and Burdach) end in arborizations closely related to the cells of the nucleus gracilis and cuneatus; from these nuclei new fibres spring which pass partly to the cerebellum of the same and the opposite side, as the posterior and the anterior external arcuate fibres, and partly to higher levels by way of the mesial fillet, as the decussating deep arcuate fibres.

With the opening out of the central canal of the cord into the fourth ventricle the **gray matter** lying originally dorsally to the canal

becomes **laterally displaced,** while the remains of the **base** of the **anterior horn** come to the surface of the ventricular floor, and assist in forming the projection of the **funiculus teres.** A longitudinal column of large nerve-cells occupies part of this, forming the nucleus from which the numerous bundles of the **roots of the hypoglossal nerve** arise.

The changes affecting the **anterior cornua** of the cord are produced primarily by the **decussation** of those fibres of the **lateral column**

FIG. 330.

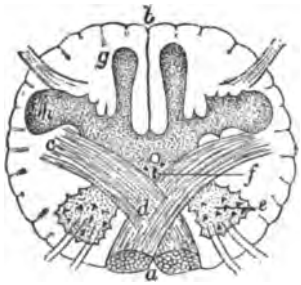

Diagram of lower end of medulla at level of decussation of anterior pyramids: *a*, anterior pyramidal tracts; *b*, posterior median septum; *c*, fibres of crossed pyramidal tracts crossing (*d*) to anterior pyramid of opposite side; *e*, anterior horn of gray matter isolated by decussating fibres; *f*, remains of bases of anterior horns; *g*, nucleus gracilis; *h*, enlarged and displaced posterior horns of gray matter. (After *Testut-Duval.*)

FIG. 331.

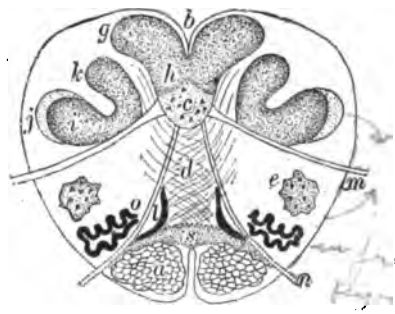

Diagram of medulla through lower part of olivary body: *a*, anterior pyramidal tract; *b*, posterior median groove; *c*, gray matter representing bases of anterior cornua, the latter lying isolated at *e*, forming nucleus lateralis; *d*, decussating fibres of formatio reticularis; *g*, nucleus gracilis; *h*, gray matter of bases of posterior horns; *k*, nucleus cuneatus; *i*, remains of posterior horns, substantia gelatinosa of Rolando; *j*, ascending root of trifacial nerve; *m*, pneumogastric, *n*, hypoglossal, nerve; *o*, nucleus dentatus of olive; *l*, mesial accessory olive; *s*, sensory portion of anterior pyramids. (After *Testut-Duval.*)

which contribute to the formation of the anterior pyramids. The fibres of the **crossed pyramidal tract,** in taking the shortest course to reach the point of decussation, cut obliquely through the gray substance in such a manner that the **anterior cornu** becomes broken up, its **caput being entirely separated**; the remaining portion of its **base** forms a small mass of gray matter lying ventro-laterally to the central canal. The **isolated segment** of the anterior cornu is pushed to the side by the development of the pyramid, and, higher up, by the additional displacement caused by the appearance of the olivary body between the caput cornu and the pyramid; in consequence the separated part **is displaced** both **laterally** and **dorsally,** and becomes the **lateral nucleus,** taking up a position in close relation with the now ventrally situated posterior horn. By the penetration of transverse and longitudinal fibres the greater part

he separated area is broken up into a coarse net-work containing ve-cells and intersecting fibres—the **formatio reticularis.** Above the level of the decussation of the pyramids, a second or **ensory decussation** is seen, formed by the crossing fibres proceeding from the nerve-cells within the funiculus gracilis and cuneatus. On gaining the opposite side, some of the decussating fibres (**internal arcuate**) turn sharply brainward and pass to higher levels as a longitudinally coursing tract, known as the mesial fillet. Other fibres, the **anterior external arcuate,** after crossing, appear ven-

FIG. 332.

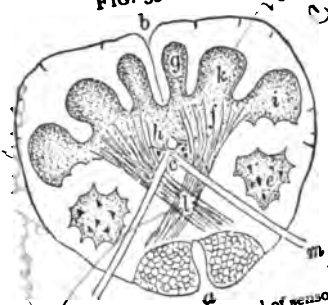

Section of medulla at level of sensory decussation: *a*, anterior pyramidal tracts; *b*, posterior median septum; *c*, *k*, gray matter representing bases of anterior and posterior cornua; *e*, isolated anterior horns; *f*, bundles of sensory fibres displacing posterior horn; *g*, nucleus gracilis; *i*, posterior horn, substantia gelatinosa of Rolando; *k*, nucleus cuneatus; *l*, decussating sensory fibres crossing to the opposite median tract; *m*, root-fibres of hypoglossal nerve. (After *Testut-Duval.*)

FIG. 333.

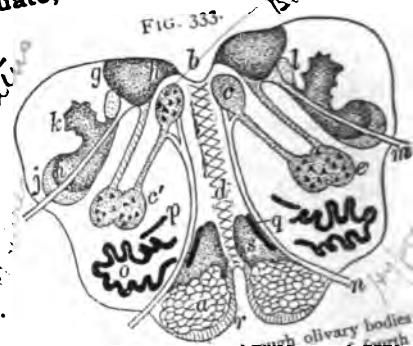

Diagram of medulla through olivary bodies: *a*, anterior pyramidal tracts; *b*, floor of fourth ventricle; *c*, remains of gray matter of base of anterior horns, nucleus of hypoglossal nerve; *c'*, accessory hypoglossal nucleus; *d*, decussating fibres of formatio reticularis; *e*, nucleus ambiguus; *g*, gray matter of posterior funiculus, including *k*, which represents base of posterior horn; *i*, substantia gelatinosa of Rolando; *j*, ascending root of trifacial nerve; *k*, restiform nucleus; *l*, funiculus solitarius; *m*, root-fibres of pneumogastric nerve; *n*, hypoglossal nerve; *o*, nucleus dentatus of olive; *p*, *q*, dorsal and mesial accessory olivary nuclei; *r*, external arcuate fibres; *s*, sensory portion of anterior pyramid. (After *Testut-Duval.*)

trally and wind over the anterior pyramid and inferior olive to gain the restiform body in their course to the cerebellum. Additional decussating fibres pass from the inferior olivary body of the opposite side to the cerebellum by way of the restiform body. A third set of arcuate fibres, **the posterior external,** passes from the posterior funiculi of the same side to the cerebellum by way of the restiform body.

In addition to the longitudinal fibres contributed by the deep arcuate bundles, the continuation of tracts from the antero-lateral column furnish longitudinal fibres of the formatio reticularis. In the upper part of the medulla, a group of longitudinal fibres constitute a distinct tract, the **posterior longitudinal bundle.**

On reaching the **inferior olivary bodies,** new groups of elements are introduced; of these the most important is the nucleus of the olive, or **corpus dentatum.** This consists of a wavy sheet of **gray matter** so disposed that it forms collectively a compressed ovoid capsule or shell, closed externally, but open towards the median side, through which **hilum** the nerve-fibres gain access to

FIG. 334.

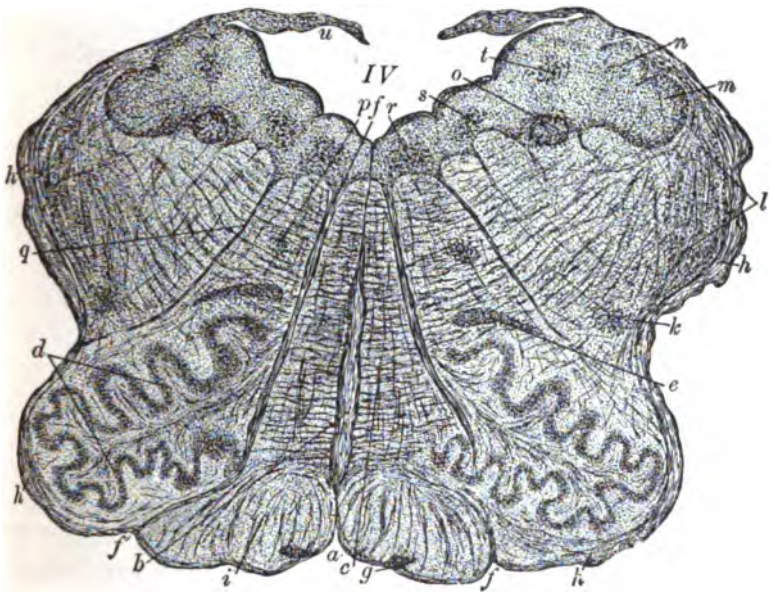

Section of medulla of child through olivary bodies: *a*, anterior median groove; *b*, raphé; *c*, formatio reticularis; *d*, gray matter of nucleus dentatus of olive; *e*, dorsal accessory olivary body; *f*, root-fibres of hypoglossal nerve; *g*, nucleus arciformis; *h*, external arcuate fibres; *i*, anterior pyramidal tract; *k*, remains of nucleus lateralis; *l*, substantia gelatinosa of Rolando and fibres of ascending trifacial root; *m*, *n*, gray matter of posterior funiculus; *o*, funiculus solitarius; *p*, nucleus ambiguus; *q*, root-fibres of pneumogastric nerve; *r*, *s*, hypoglossal and vagus nuclei; *t*, nerve-cells of posterior funiculus; *u*, posterior medullary velum closing in fourth ventricle, IV.

the interior. The considerable tract of nerve-fibres entering the hilum constitute the **olivary peduncle,** having crossed the raphe from the tracts of the opposite side. After gaining the interior of the olivary body, they diverge towards the lamina of gray matter, which they traverse in their course to the restiform body and thence to the cerebellum. These olivary bundles form part of the **lateral arcuate fibres,** but consist, for the most part, of nerve-fibres of smaller diameter than those composing the internal arcuate fibres.

Two **additional small areas** of **gray substance** are seen in

close proximity to the corpus dentatum: these are the **dorsal** or **outer** and the **mesial** or **inner accessory olivary nuclei**, the **first** of which lies behind the olivary nucleus, near and parallel to its wavy band, while the **second** lies almost across the open end of the corpus dentatum.

Attention has already been directed to the tract of large nerve-cells which lies near the median line and represents the **nucleus of the hypoglossal nerve.** In the lower part of the medulla, before the central canal opens out into the ventricle, a group of numerous smaller cells lies close but dorsally to the nucleus just mentioned; as the central canal approaches the surface the tissues forming its former dorsal border become gradually laterally displaced, in consequence of which this group of nerve-cells then comes to lie outside of the hypoglossal nucleus. These cells form a continuous column throughout almost the length of the medulla, constituting a **common receptive nucleus** of the pneumogastric and glosso-pharyngeal nerves.

The four **principal tracts of the medulla** are made up chiefly of the continuations of the columns of the cord; without entering into a detailed account of these structures, a brief outline of the most important of the constituents of the tracts may here find place.

1. The **anterior pyramid** is composed of two sets of fibres: the continuation of the direct pyramidal tract of the anterior column of the cord, which does not take part in the decussation of the pyramids, and the continuation of the crossed pyramidal tract of the lateral column. The proportion of the crossed to the uncrossed fibres varies greatly; while usually from three to ten per cent. of the pyramidal fibres pass directly into the anterior columns of the spinal cord, total decussation of these fibres takes place in about eleven per cent., in such cases the anterior pyramidal tract being evidently wanting. In only about sixty per cent. is a symmetrical disposition of the two pyramidal tracts on each side observed.

2. The **lateral tract** claims all the fibres of the lateral column not included in the crossed pyramidal and the direct cerebellar tract, together with the external anterior or ground-bundle, since the latter really is a part of the adjacent tract of the lateral column. The antero-lateral fibres enter beneath and at the side of the anterior pyramid and pass under the olivary body and the arcuate fibres to take part in making up the formatio reticularis; the sensory fibres derived from the posterior columns after crossing in the sensory decussation pass brainward and aid in forming the mesial fillet.

3. The **restiform body** contains constituents from a number of sources; these may be arranged in two groups,—those **derived**

from the cord and **the medulla** and those **arising from the pons.** The first group comprises:

(*a*) The direct cerebellar tract of the lateral column.

(*b*) The posterior external arcuate fibres from the nucleus gracilis and nucleus cuneatus of the same side.

(*c*) The anterior external arcuate fibres from the nucleus gracilis and nucleus cuneatus of the opposite side.

(*d*) The internal arcuate fibres from the inferior olive of the opposite side.

(*e*) Fibres from the lateral nucleus of the medulla.

The pontine group includes:

(*f*) Fibres from the superior olive of the opposite side.

(*g*) Fibres from the acoustic nucleus of the same side.

4. The **posterior pyramid** is the upward prolongation of the postero-median column of the cord. On approaching the lower angle of the fourth ventricle, this column, or the funiculus gracilis, exhibits the pronounced thickening of the clavus, which contains the nucleus gracilis and then merges into the restiform body.

THE PONS.

The pons, as may be inferred from the mutual relations of the several divisions of the brain which it connects, consists very largely of **bundles of nerve-fibres**; in addition to these, areas of gray matter, the **pontine nuclei**, supplement the nerve-fibres in making up its mass. On section the pons exhibits two portions, the **dorsal** and **the ventral.** The latter contains the principal decussating tracts connecting the cerebral cortex and cerebellum, and constitutes a robust mass of **transverse fibres**; through this the longitudinal bundles of the **anterior pyramids** of the medulla force their way in their course from the cerebrum. In the lower half of the pons the pyramidal fibres are collected into two **closely-packed groups** of bundles, one on either side of the mid-line, which are enveloped in front and behind by a layer of transverse fibres; higher up, above the middle of the pons, the pyramidal tracts become separated by the penetrating transverse bundles into a number of fasciculi. Among the transverse tracts, therefore, are recognized the ventral or **superficial bundles** and the dorsal or **deep bundles**, the latter forming the **corpus trapezoideum.** Small **multipolar cells** are found widely distributed in the ventral region of the pons within the gray matter which occupies the interfibrillar interstices.

The **dorsal portion** of the pons consists largely of structures representing the continuation of parts already encountered below, especially of the **formatio reticularis** and of the **dorsal tracts** of gray substance. In addition to the **gray matter** scattered throughout

the reticulum, other localizations represent important nuclei of cranial nerves. The sheet of gray matter lying in the lower half of the ventricular floor is continued over the pons, and there gives rise to nuclei connected with the V, VI, VII, and VIII nerves. While the details of the sections must vary with each plane, the general disposition of the structures is shown in sections passing through at about the middle of the fourth ventricle. In such sections the dorsal

FIG. 335.

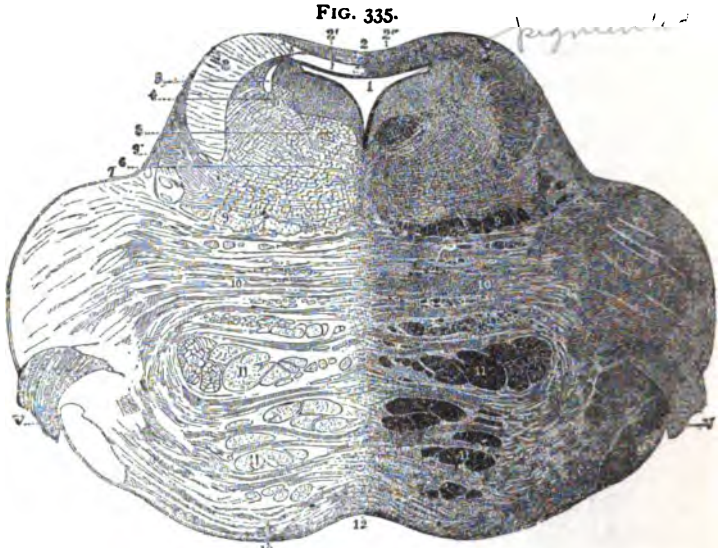

Section through upper part of human pons: 1, fourth ventricle; 2, valve of Vieussens lined with ependyma; 2′, white matter of anterior medullary velum; 2″, gray matter of lingula; 3, descending root of trifacial nerve; 4, substantia ferruginea; 5, posterior longitudinal bundle; 6, formatio reticularis; 7, groove indicating boundary between tegmentum and ventral part of pons; 8, superior cerebellar peduncle; 9, mesial fillet; 9′, lateral fillet; 10, transverse fibres of pons; 11, longitudinal fibres; 12, raphé; V, trifacial nerve. (After *Testut-Stilling*.)

or tegmental portion of the pons bears a resemblance to the medulla, the gray dorsal stratum giving rise to fibres which pierce the reticulum in their course to the free surface.

At a somewhat higher level, lateral groups of pigmented nerve-cells occupy the **floor of the fourth ventricle**; these cells are so dark that they collectively present an area visible to the unaided eye, the **substantia ferruginea**; seen through the stratum of white fibres forming the immediate floor of the ventricle, this area appears of a bluish-gray or slate-color and constitutes the **locus cœruleus.** Close to this pigmented area, lying to its mesial side and near the raphé, an angular tract, known as the **posterior longitudinal bundle,** extends beneath the gray matter of the ventricle, just at the dorsal border of the reticular formation. This fasciculus, also prom-

inent at higher levels, establishes important communications between the nuclei of several cranial nerves.

THE CRURA.

The **crura cerebri**, or **cerebral peduncles**, resemble the pons in general arrangement, since they consist of a ventral portion, the **crusta pedunculi**, or the **cerebral peduncle proper**, made up

FIG. 336.

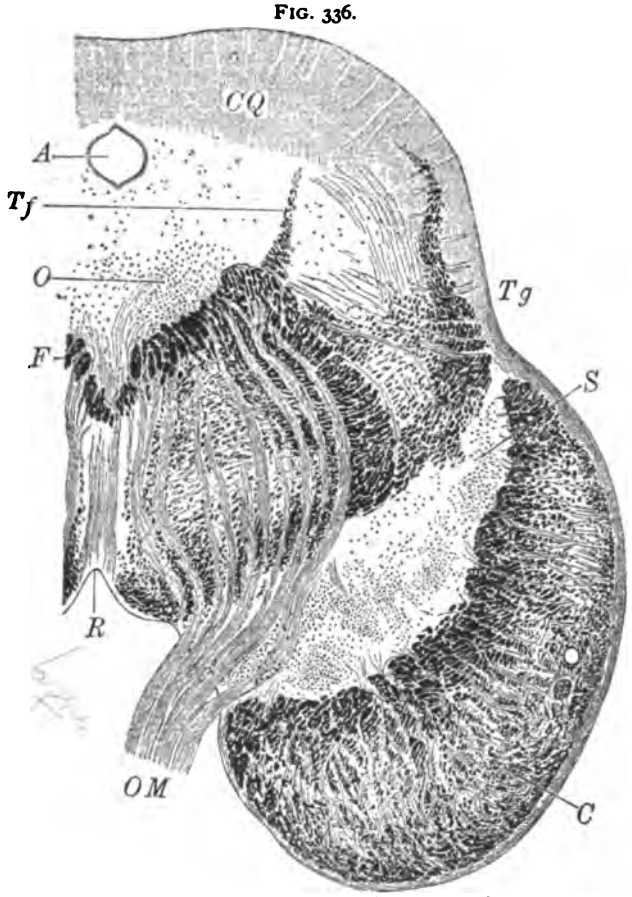

Section through human cerebral peduncles at point of emergence of oculo-motor nerve: *C*, crusta, separated from tegmentum (*Tg*) by substantia nigra (*S*); *R*, raphé dividing formatio reticularis; *F*, longitudinal bundles of latter; *O*, groups of nerve-cells connected with origin of oculo-motor fibres (*Om*); *Tf*, cells connected with origin of trifacial nerve; *A*, aqueduct of Sylvius; *CQ*, anterior corpora quadrigemina. (After *Krause*.)

exclusively of ascending and descending fibre-tracts, and of a dorsal portion, the **tegmentum**, which contains the prolongation of the formatio reticularis and of the dorsal stratum of the gray substance

of the medulla and the pons. On transverse section of the crura, it is seen that the **tegmental halves** are **united,** while the two **peduncular portions** are widely **separated** and are attached to the tegmentum alone; the oblique line of this juncture is indicated within the section by a deeply pigmented area, the **substantia nigra.**

The **crusta** is hemi-cylindrical in section, but the encroachment of the substantia nigra reduces the area devoted to the ascending and descending fibres to a **narrow crescent,** whose convexity corresponds to the external outline of the peduncle, while the concavity embraces the dark field. Since the tracts of ventral nerve-fibres of the peduncle greatly exceed the pyramidal bundles of the pons, it is evident that many additional fibres have arisen within the peduncles. On reaching the cerebral hemispheres in their course upward, the **tracts of the crusta** become continuous with the fibres constituting the **internal capsule.**

The **substantia nigra,** separating the crusta and the tegmentum, forms a tract of gray matter extending from the upper border of the pons forward as far as the mammillary bodies; while it gradually diminishes in its forward course, the mesial edge of the mass becomes thickened in the vicinity of the oculo-motor groove. The area owes its exceptional color to irregular groups of **deeply pigmented multipolar cells** embedded within a finely granular ground-substance.

The **tegmentum** forms only part of the great **nuclear tract** continued through the dorsal portion of the oblongata, the pons, and the peduncle into the subthalamic region; as in the other localities, so here, the **stratum of gray matter** lying beneath the floor of the neural tube and the **formatio reticularis** are its principal constituents. In addition to the gray matter distributed throughout the reticulum, groups of nerve-cells are situated along the **floor of the Sylvian aqueduct;** some of these are of importance as the nuclei of the bundles of the oculo-motor and the pathetic nerve. Near the middle of the formatio reticularis, on either side of the raphé, lies a conspicuous group of large pigmented nerve-cells, the **tegmental** or **red nucleus,** so called on account of its brown or reddish hue. The **formatio reticularis** of the tegmentum differs little from the similar structure at lower levels. In general, the **fibres** contained within the **crusta** connect with the motor areas of the **cerebral cortex,** while those of the **tegmentum** usually terminate in or about the **thalamus.**

THE CEREBELLUM.

The **cerebellum** consists of a peripheral or cortical layer of gray substance which encloses the various tracts of nerve-fibres composing

the white matter of the medulla, together with certain additional gray nuclei embedded within the latter. On section, each leaflet of the cerebellum is seen to be made up of (1) a central core of **white medullary substance,** which blends into (2) the **granule layer,** characterized by its "rust-color," external to which follows (3) the

FIG. 337.

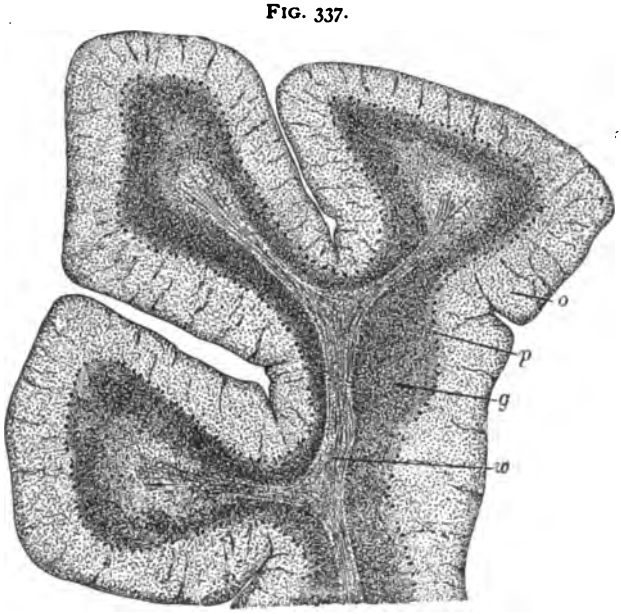

Section of human cerebellum, slightly magnified to show general arrangement: *w*, white matter of medulla; *g*, *o*, granule and molecular or outer layer, between which lies layer of Purkinje's cells (*p*).

outer or **molecular stratum**; between the latter and the granule layer lies (4) the single row of ganglion-cells which constitutes the **layer of the cells of Purkinje.**

The **granule layer** forms a zone conspicuous on account of the great number of small deeply-staining cells which it contains. It varies in thickness, being **broadest at the summit** of the laminæ and **narrowest at the bottom** of the fissures. Towards the outer layer the zone is sharply defined, but it fades away on the median side into the medullary substance.

The **nerve-cells of the granule layer** are of two kinds,—the **small** and the **large** ganglion-cells. The former are small (6–7 μ) round elements, stain deeply, but possess so little protoplasm that the greater part of the cell is formed by the nucleus. These cells, the principal elements of this layer, are arranged in irregular groups; they are multipolar, and have, according to recent investigations,

branched protoplasmic as well as nervous **or axis-cyli processes**; while the **former ramify** among the cells of the **gra layer**, the delicate **nervous processes extend** into the **molecular** layer, where they usually end by dividing into **lon dinal T-branches** which stretch horizontally parallel with the daries of the zone. The processes of these cells are so delica well as so masked by the surrounding elements, that their exis has been established only after the introduction of the recent me of Golgi, the results of whose investigations have been confirm Ramón y Cajal, Kölliker, and others. Other nervous elemer the granule layer are the sparingly-distributed **multipolar** much larger than the ones just considered, which resemble in s ure and size the cells of Purkinje, and, like them, possess ri **branched protoplasmic** processes extending within the mol

FIG. 338.

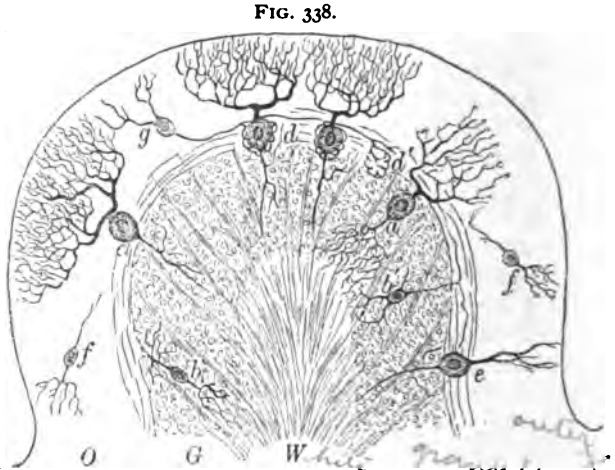

Diagram representing cellular constituents of cerebellar cortex; Golgi's silver staining: W matter; *O*, *G*, outer and granule layers of gray matter; *a*, large cell of granule layer confined substance; *b*, *b'*, small nerve-cells of granule layer (exaggerated for convenience), also limited matter; *c*, cell of Purkinje, sending axis-cylinder into granule layer and richly-branched p towards periphery; *e*, similar cell seen in profile; *f*, small nerve-cell of outer layer, limited matter; *g*, nerve-cell of outer layer, whose axis-cylinder process forms basket works (*d*, *d'*) body of cells of Purkinje; at inner border of outer zone numerous horizontally ramifying t of nerve-fibres are seen.

layer; they differ in the distribution and form of the **axis-cyli processes.** The latter are directed towards the medulla, but, ir of passing into the granule layer to become continuous with r fibres, the processes in question divide and subdivide into an a **ization** of great richness. The ramifications of the two variet nerve-cells of the granule layer, therefore, are distributed in a m directly opposed, the nervous processes of the small cells termir

FIG. 330.

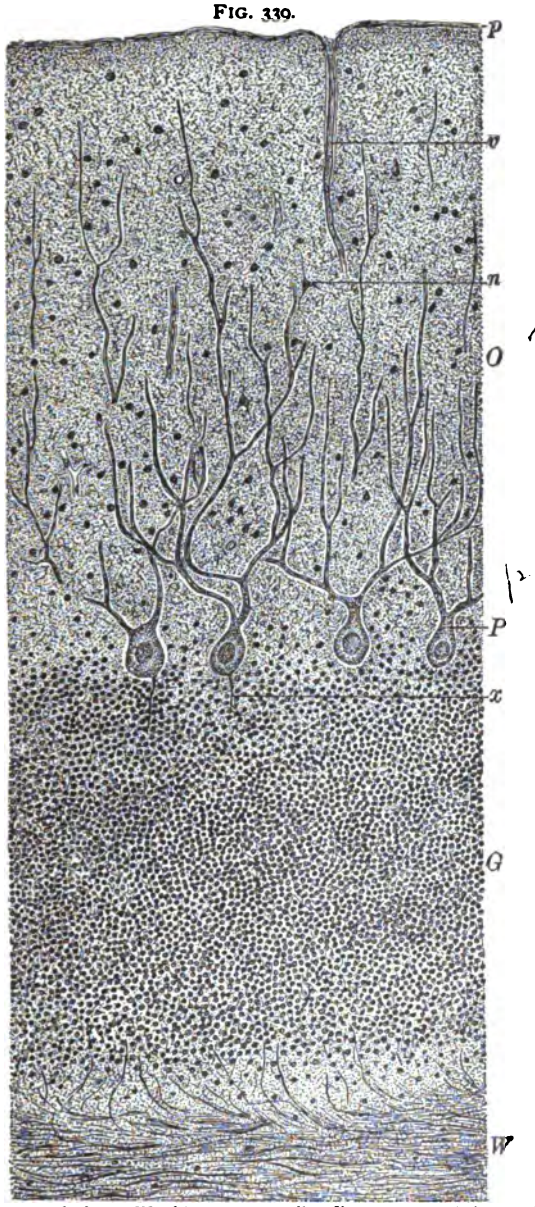

Section of human cerebellum: *W*, white matter sending fibres into granule layer (*G*); *O*, outer or molecular layer; *P*, cells of Purkinje, sending axis-cylinder processes (*x*) into granule layer and protoplasmic processes towards periphery; *n*, small nerve-cell of outer layer; *v*, blood-vessel from pia (*p*).

within the outer layer, while those of the larger cells divide within the granule layer; in both cases, it will be remarked, the axis-cylinder processes terminate **entirely within the gray matter,** thus identifying their possessors as **nerve-cells of the second type.** In addition to the nervous elements, a few flattened cells, with feebly-developed processes, are scattered throughout the granule zone; these are to be regarded as belonging to the **supporting framework.** The interstices between the numerous nerve-cells are partly occupied by the plexus of **medullated nerve-fibres** which are derived from the bundles of parallel fibres continued from the medullary tracts; some of these fibres pass beyond the nuclear layer to **end within the molecular zone.**

The **cells of Purkinje** form the thinnest but, at the same time, the most characteristic layer of the cerebellar cortex. These elements, among the largest ganglion-cells in the body, are disposed as a single row at the junction of the nuclear and the molecular layer, and present pyriform or flask-shaped bodies, 60–70 μ in their longest diameter, placed vertically to the plane of the zone, with the larger, rounded end resting on the outer margin of the nuclear layer, while the smaller end is directed towards the periphery. **Each cell** possesses a **large nucleus** (15 μ) as well as a **nucleolus,** and differs from other ganglionic elements in containing little or **no pigment.** The central pole is prolonged as the **axis-cylinder process,** which, after giving off **collateral fibres,** passes on to become the axis-cylinder of a medullated nerve. The most distinctive feature of these cells, however, is the **distribution** of their **protoplasmic processes.** A thick tapering process, usually single, but occasionally double, extends from the small end of the flask-shaped body towards the periphery; this stem very soon divides into two, the branches running horizontally, sometimes almost at right angles to the parent stalk before turning towards the surface; the peculiarity of the rich ramification which follows is the dominating vertical direction of the larger branches. While the pictures presented by the cells of Purkinje in successfully-stained sections have always been among the most striking, it was not until the introduction of Golgi's silver method that a full appreciation of the remarkable richness of these ramifications became possible. In such preparations the molecular layer is occupied to its extreme periphery by the intertwining but **ununited fibrils** of the branching processes. The extent and breadth of these apparent net-works, however, vary with the point of view, for the cells send out their branches especially in a direction at right angles to the long axis of the convolution or the medullary tract, while in a plane parallel to this axis the branches are limited to a narrow zone, scarcely wider than the body of the cell: it follows

that in order to display Purkinje's cells to the best advantage the tissue should **be sectioned across,** and not parallel with, the axis of the convolutions. These cells, further, are not placed at uniform distances throughout the row which they form, but are more numerous

FIG. 340.

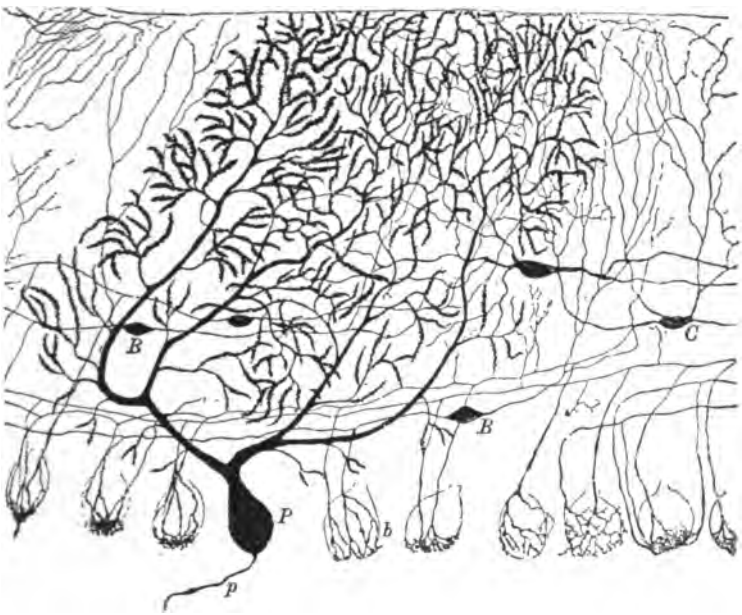

Section of outer portion of cerebellar cortex of young dog, stained after Golgi's silver method: *P*, cell of Purkinje, exhibiting profuse arborization of protoplasmic processes; *p*, its axis-cylinder process; *B*, *B*, cells of outer layer whose axis-cylinder processes form basket-works around bodies of Purkinje's cells; *C*, small ganglion-cells limited to outer layer. (After *Retzius*.)

and **more closely arranged** at the **summit of the convolutions,** at the **bottom of the fissures** being more **widely separated**; these variations correspond with the areas of greatest and least development of the nuclear layer.

The **molecular** or **outer layer** consists of a ground-substance of finely-reticulated supporting **neuroglia,** in which extend the elaborate **arborizations** of **Purkinje's cells,** together with certain nervous elements belonging to this zone. These latter are of two kinds: **small multipolar cells whose** branched protoplasmic processes extend towards the periphery, while the nervous process is directed centrally, but probably is confined to the molecular layer, and **larger elements** distinguished by the remarkable termination of their axis-cylinder or nervous processes. While the **protoplasmic**

processes ramify within the outer part of the molecular laye **axis-cylinder process,** after a short course, passes horizo near the margin of the large-celled layer, and, at various inte sends off lateral branches which subdivide to form **net-worl fibrils, the fibre-baskets,** or **basket-works, around the b of Purkinje's cells.** In addition to the nervous elements, belonging to the **neuroglia** are scattered throughout the zone already stated, certain of the nerve-fibres entering the granule **continue** into the outer layer; these fibres, after penetrating short distance, divide into **terminal branches,** many of extend horizontally, parallel to the boundaries of the zone, t free, in close relation but **without direct continuity** wit nerve-cells.

In addition to the peripheral cortical layer, the cerebellum pos other masses of gray matter, the **central nuclei,** embedded the medullary substance of the vermiform process and of the adj parts of the hemispheres. The central nuclei are two: the **nu dentatus,** situated within the hemisphere of each side, an **nuclei of the roof,** within the worm; the **nucleus embolifo** and **nucleus globosus,** sometimes described as separate centre really parts of the complicated dentate nucleus.

The **dentate nucleus** consists of a greatly plicated pouc sheet of gray substance, .3–.5 mm. in thickness, situated withi fibre-tract of the **superior peduncle** of the cerebellum. The n **cells** contained within the band are of moderate size (25–35 μ **pigmented** to a variable degree; the loosely-packed cells p **branched processes** extending outward, and an **axis-cyli process** directed towards the medulla. Numerous **nerve-f** pass between the cells and connect the **white core** within the n with the surrounding medullary substance.

The **nuclei of the roof** consist of irregularly ovoid areas of substance (6–8 mm. in length) situated within the vermiform pr almost in contact along the mesial line. The masses contain **pigmented multipolar ganglion-cells** (45–80 mm.) and num **nerve-fibres,** some of which are exceptionally large.

The **medullary** or **white substance** of the cerebellum braces the numerous bundles of nerve-fibres which maintain intricate and far-reaching communications of this division o brain. The **cerebellar fibres** are arranged in **three prin tracts, the cerebellar peduncles; the lower** of these c sponds to the **corpus restiforme,** the **middle** to the **pedu pontis,** and the **upper** to the **processus cerebelli ad cor quadrigemina.**

The fibres of the **white matter** are disposed in thin flat bun

which diverge from the chief stem as the primary and secondary medullary branches; these form the "arbor vitæ."

The **blood-vessels** supplying the cerebellum, principally branches of the vertebral and basilar arteries, after repeated division within the pia, send small branches **vertically** into the **molecular layer** as far as its inner boundary; a rich vascular **net-work** surrounds the **cells of Purkinje**: while capillaries are wanting within the **peripheral zone** of the **molecular layer**, they are **well represented** in the **granule layer** and among the **nerve-bundles** of the medulla, where the blood-vessels run between the fibres and form elongated meshes which correspond to the disposition of their tracts.

THE CEREBRUM.

The **cerebral hemispheres** consist of a thin outer sheet of gray matter, the **cortex**, which everywhere covers in the white matter of the **medulla**, accurately following the intricacies of the convoluted surface of the brain; in addition to the cortex, large **special masses of gray matter** lie within the medullary substance and take part in the constitution of the **nucleus caudatus**, the **nucleus lenticularis**, the **thalamus**, the **corpus subthalamicum**, and the minor collections of lesser importance.

The **cerebral cortex** forms a dark, peripheral zone, 2–4 mm. in thickness, which is **best developed** in the ascending frontal and the paracentral convolution, being thicker at the summit of the gyri than in the fissures; the gray stratum appears **least conspicuous** in the posterior part of the occipital lobe.

The arrangement of the elements of the cortex in layers is indicated by the **stratification** which the vertically-cut surface of the cortex presents even to the unaided eye; in favorable situations **three bands** are distinguishable, an **outer white**, a **middle gray**, and an **inner yellowish red**; in certain regions, as the superior frontal, the precentral, and the occipital convolutions, the layers are increased to six by the addition of the **stripes of Baillarger.** These markings, however, do not accurately represent the structure of the cortex, which can be studied adequately only in successfully-stained sections cut vertically to the free surface of the convolution and parallel with the general course of the nerve-fibres. In such preparations **five zones** are recognizable, which, however, are not sharply defined from one another, but are often blended.

1. The **first** or **outer layer**, next the pial surface, about .25 mm. in thickness, is composed essentially of **neuroglia**, together with numberless delicate terminal **ramifications of the protoplasmic processes** of nerve-cells situated within the deeper layers, and a few **tangential nerve-fibres**; the protoplasmic threads contributed

FIG. 341.

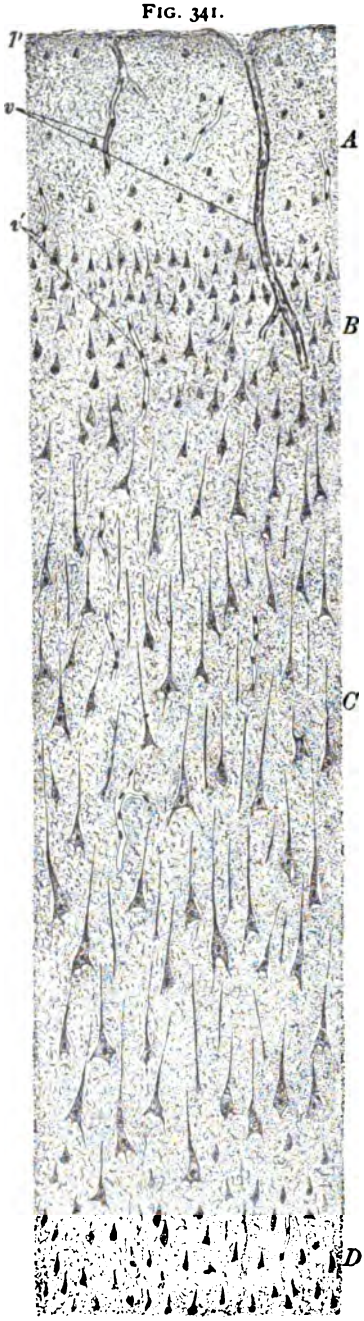

by the cells are so plentiful and closely interwoven that they constitute no inconsiderable part of the fine **ground reticulum** of this layer. Immediately beneath the surface of the nervous matter, the **sub-pial zone** forms a narrow stratum (10–25 μ) composed almost entirely of **neuroglia**, in which lie numbers of **spider** or **Deiters's cells.** The nerve-fibres of this layer extend parallel with the free surface.

2. The **second layer** (.2 mm.) is characterized by the profusion of its closely-packed **small triangular** or **pyramidal nerve-cells,** the branched **protoplasmic processes** of which extend in various directions towards the periphery, while their **axis-cylinder processes** terminate within the gray matter, often ending in T-branches which are directed almost at right angles to the main process.

3. The **third layer,** the formation of the **cornu Ammonis,** is the thickest stratum of the cerebral cortex, reaching in places a breadth of 1 mm., and contains the most characteristic nervous elements of the cerebrum, the **large pyramidal ganglion-cells.** This layer is not sharply defined from the preceding, since the small cells of the latter are gradually replaced by the larger pyram-

Section of human cerebral cortex stained with sodium carminate: *A*, outer layer, poor in nerve-cells, rich in neuroglia; *B*, layer of numerous small nerve-cells; *C*, layer of large pyramidal ganglion-cells; *D*, layer of irregular numerous but small nerve-elements; *p*, pial tissue; *v*, *v'*, blood-vessels.

idal elements, which become more widely separated and of greater size on approaching the deeper parts of the zone; in this situation their basal diameter may reach 40–50 μ.

FIG. 342.

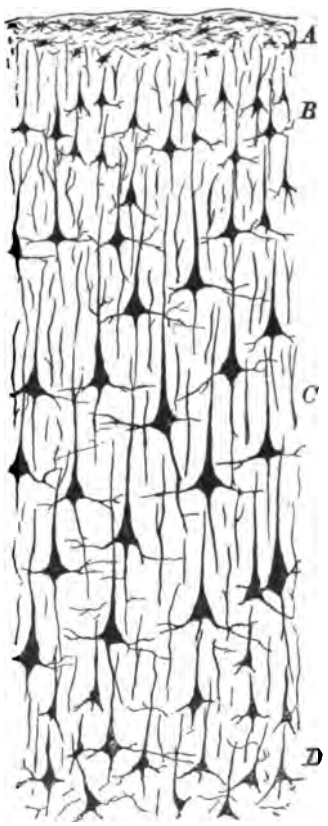

Section of cerebral cortex (motor area) of child stained by Golgi's silver method: *A*, layer of neuroglia-cells; *B*, layer of small pyramidal ganglion-cells; *C*, layer of large pyramidal cells; *D*, layer of irregular smaller cells.

The pyramidal cells, in addition to the general outlines of their bodies, are distinguished by the **arrangement of their processes**; the protoplasmic ramifications are disposed as the principal **apical processes,** which extend towards the periphery as far as the sub-pial zone (Retzius) and by repeated division form a rich arborization within the outer layers of the cortex, and as **lateral basal processes,** which pass obliquely from the base and break up into rich networks of delicate terminal protoplasmic threads; in addition, numerous smaller **lateral processes** are given off from the sides of the cell. Notwithstanding the profusion of the fibrils resulting from the subdivision of the protoplasmic processes of these cells, it is highly probable that the fibrils **terminate without uniting with one another.** From the blunt, central end of the cell the **axis-cylinder process** extends into the white matter, where it becomes continuous with a nerve-fibre. These axis-cylinder prolongations give off recurrent **collateral processes,** which bend towards the periphery. The pyramidal **body of the cell** contains a large round or oval **nucleus,** with a distinct **nucleolus,** embedded within a finely granular protoplasm, masses of **brownish pigment** almost always occupying the base of the cell. The larger pyramidal cells are surrounded by **pericellular lymph-spaces,** which probably communicate with the extensions of the **subarachnoidean space** continued with the prolongations of the pia accompanying the blood-vessels within the cerebral tissue.

4. The **fourth layer** embraces a closely-packed zone (.3–.4 mm.) composed of **small, irregular, oval or angular nerve-cells,** 7–

14 μ in diameter; among the smaller elements a few larger pyramidal cells are often encountered, as well as **radiating bundles** of **medullated nerve-fibres.** The cells of this layer resemble those of the second, since their axis-cylinder processes are confined to the gray matter, the elements being, therefore, **cells of the second type.**

FIG. 343.

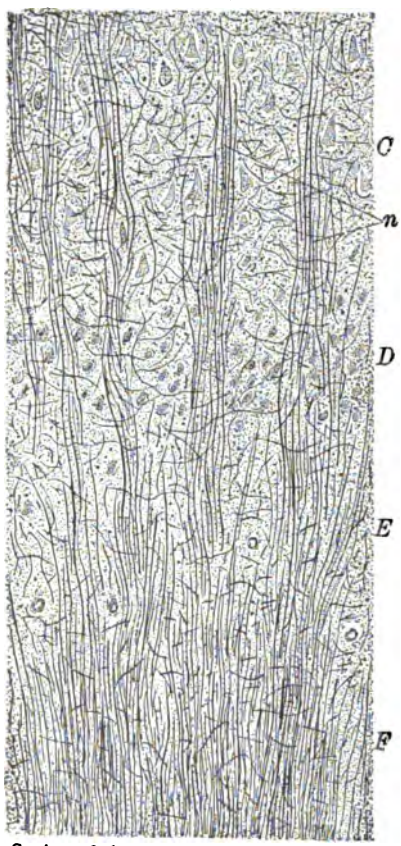

Section of human cerebral cortex stained by Weigert's method, exhibiting groups of nerve-fibres; part of white matter and inner layers of gray substance shown: *F*, white matter from which radiating bundles of nerve-fibres (*n*) extend into gray matter; *C*, *D*, and *E*, third, fourth, and fifth zones of gray matter: cells are faintly stained.

5. The **fifth layer** indicates the proximity of the white matter by the large areas occupied by **bundles of radiating nerve-fibres** directly continuous with the medullary tracts; within the interspaces between the nerve-bundles lie the **small** and **medium-sized cells,** spindle to pyramidal in form, which characterize this layer. While these cells are arranged generally parallel with the fibre-bundles, sometimes, especially at the bottom of the fissures, they are placed at right angles thereto, in the latter case assuming a pronounced **spindle type.**

The **nerve-fibres** entering the gray cortex are arranged in bundles, from which arise net-works variously situated and arranged. The **radial bundles** proceed as such through about half the entire thickness of the cortex; beyond this level they rapidly separate into the component fibres which take their way between the ganglion-cells. The fibres given off during the course of the bundles form net-works at all depths occupying the interfascicular portions of the layers traversed; within the deepest part of the **fourth layer,** however, the nervous fibrillæ are especially numerous, and constitute a **conspicuous reticulum** in preparations stained by Weigert's

method. In the deeper parts of the broad **third layer** a similar **well-marked net-work** occurs, the interlacing fibres of which surround the nerve-cells of the layer. Beyond this plane **nervous reticulations** occupy the third and second layers and extend into the outer zone.

A limited number of the nerve-fibres **terminate within the outer layer** as axis-cylinders which run **parallel with the free surface,** as do also the terminal ramifications of the axis-cylinder processes of some of the ganglion-cells. The recent investigations of Golgi and others have shown that many fibres end **without demonstrable direct anatomical continuity with the nerve-cells,** although a close relation between the cells and the fibres undoubtedly exists.

While the arrangement just described may be regarded as typical for the greater part of the cortex, a few localities are distinguished by **modifications** which materially affect the histological details. These changes depend upon either an **arrested development** of the cortex, as in the septum lucidum, or an **increased complexity** of the cortical arrangement, as in the hippocampal convolution. Less conspicuous variations, affecting one or more layers, are frequently encountered; thus, the **paracentral convolution** contains the largest pyramidal cells, the **"giant pyramids"** (Betz), the entire third layer participating in the increase of size. The **occipital cortex** is especially differentiated by subdivisions of the third and fourth layers into eight layers (Meynert), while the **gyrus cinguli** has the third layer separated into an outer group of small and an inner zone of larger cells, the intervening space appearing radially striated on account of the apical processes which cross it; within the **parietal lobes** an additional stratum of small pyramidal cells exists between the third and fourth cortical layers.

The involuted cortex of the **hippocampal region,** including the **cornu Ammonis, or hippocampus major,** and the **fascia dentata,** presents considerable complexity. On observing a section of this region with low amplification, it will be seen that the **cornu Ammonis** consists of a **central gray zone** bounded both internally and externally by a **stratum of white substance;** the gray zone **corresponds to the cortex** of other parts, and is **continuous** with the thickened gray mass constituting the **fascia dentata** above, and with the cortex of the **hippocampal convolution** below. The medullary substance of the latter becomes greatly reduced in its passage over the cornu Ammonis, the attenuated stratum of fibres being known as the **alveus** which is prolonged into the thicker **fimbria.** The white layer enclosing the gray zone on the mesial surface is a conspicuous thickening of the peripheral zone of the hippocampal convolution.

The several structures composing the **cornu Ammonis**, examined from the ventricle towards the outer surface, are—

1. The **alveus**, an attenuated layer of **medullated nerve-fibres**, homologous with the medullary substance of the typical convolu-

FIG. 344.

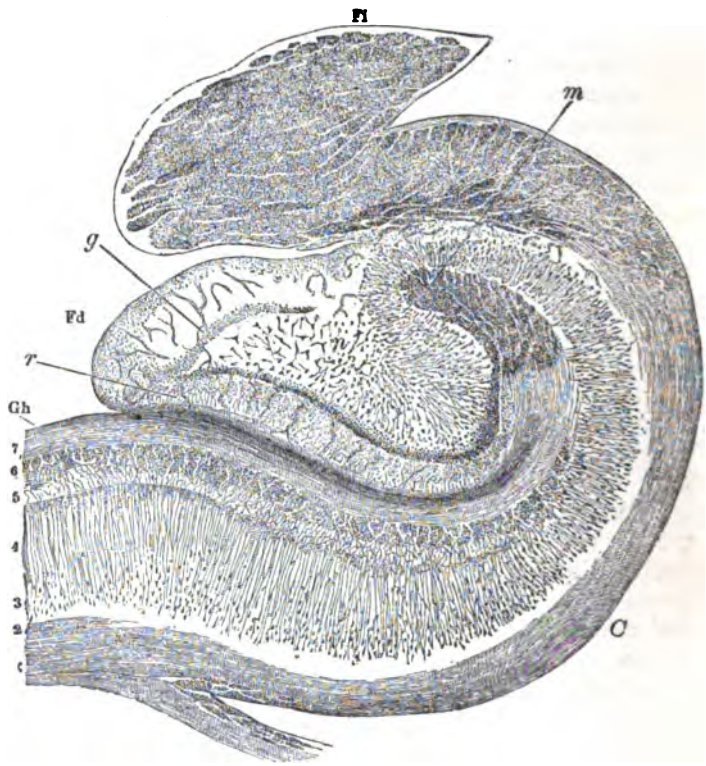

Section across cornu Ammonis, fascia dentata, and fimbria: *Gh*, hippocampal convolution; *Fd*, fascia dentata, separated from preceding by hippocampal fissure; *Fi*, fimbria, composed of transversely cut longitudinal nerve-fibres; 1, 2, medulla of hippocampal convolution continued over cornu Ammonis (*C*), as alveus, into fimbria; 3, layer of large pyramidal cells; 4, stratum radiatum; 5, stratum lacunosum; 6, stratum moleculare; 7, lamina medullaris involuta; *m*, termination of this lamina in longitudinal fibres; *n*, nucleus fasciæ dentatæ; *g*, stratum granulosum; *r*, reticulated neuroglia-layer covered by thin sheet of nerve-fibres. (After *Henle*.)

tion. The fibres, while pursuing a course generally **parallel to the ventricular surface**, run somewhat obliquely; on approaching the fimbria the layer increases in thickness and the nerve-fibres assume a disposition less oblique, until, within the fimbria, their direction almost coincides with the long axis of the cornu Ammonis.

2. The **stratum oriens,** representing the fifth layer of the cortex, and containing among the bundles of nerve-fibres numbers of **spindle-form cells,** whose processes extend parallel with the free surface.

3. The **stratum cellularum pyramidalium,** which corresponds to the deeper portions of the third cerebral layer, and is conspicuous on account of the **large pyramidal ganglion-cells.** The latter, moderate in size (30–40 μ), are arranged in several closely-packed rows, and send their **axis-cylinder processes** into the adjoining medullary substance of the alveus, while their long **apical protoplasmic processes** pass towards the periphery and give to the outer part of the third layer a **vertical striation,** which has received recognition as

4. The **stratum radiatum.** This layer consists almost entirely of the long, tapering **processes of the pyramidal elements,**

FIG. 345.

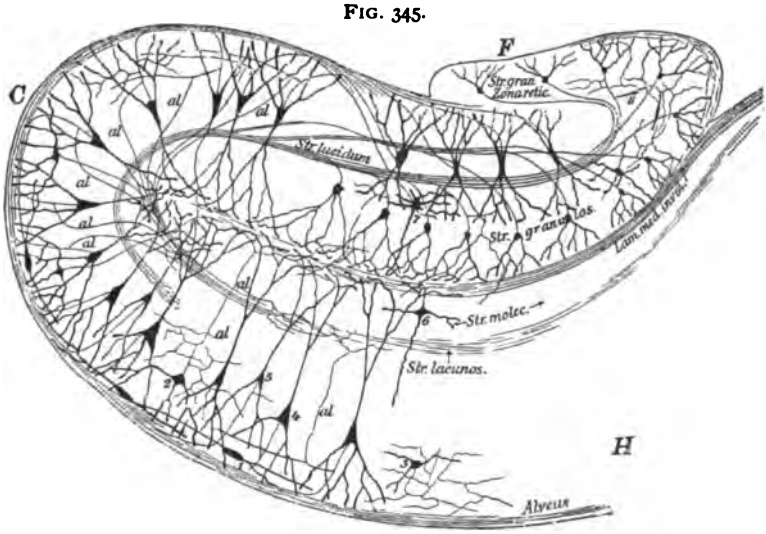

Diagram of the constituents of the cornu Ammonis, Golgi staining: *H*, hippocampal convolution; *C*, cornu Ammonis; *F*, fascia dentata; 1, fusiform, 2, 3, small and irregular, 4, 5, pyramidal, and 6, small, cells of respective layers; 7, 8, nerve-cells of fascia dentata; *al*, collaterals of pyramidal cells; course of axis-cylinder processes shown by fine lines. (After *Karl Schaffer.*)

which often show a disposition to divide into numerous branches before reaching the border of the zone.

5. The **stratum lacunosum,** composed principally of axis-cylinders, which extend parallel to the fibre-layer of the alveus, together with the collateral processes from the neighboring nerve-cells.

6. The **stratum moleculare,** which contains sparingly distributed **fusiform** or **pyramidal ganglionic elements,** whose **protoplas-**

mic processes extend vertically into the outer part of the zone of pyramidal cells, as well as laterally within the molecular layer; their **axis-cylinder processes,** on the contrary, are directed towards the peripheral nerve-fibres, among which they end.

7. The **lamina medullaris involuta,** constituting the outermost layer of the convolution, lying next the fascia dentata, from which it is separated by the intervening hippocampal fissure and its pial fold. This layer corresponds to the greatly thickened outer zone of the usual cortex, and is largely made up of **tangential nerve-fibres** which proceed from the gyrus hippocampi, together with numerous terminal fibrillæ derived from the **processes of ganglion-cells** situated in neighboring strata.

The **fascia dentata** must be regarded as the projecting thickened and specialized **free edge of the cortical gray matter,** lodged within the hippocampal fissure, which it almost fills. The divisions recognizable in this structure, from within outward, are—

1. The **nucleus fasciæ dentatæ,** which comprises an oval area containing **nerve-fibres** continued from the alveus and numerous **ganglion-cells.** The latter include **three varieties** of irregularly-disposed elements, the **pyramidal cells proper,** the representatives of the similar conspicuous constituents of the cornu Ammonis, the **polymorphous cells,** possessing very numerous processes, and the **fusiform cells.**

2. The **stratum granulosum,** distinguished as a conspicuous band of brilliantly staining small **pyriform nervous elements,** whose protoplasmic processes extend towards the periphery, while the axis-cylinder fibrils in general pass centrally.

3. The **stratum moleculare,** consisting of a broad **reticulated zone of neuroglia,** which contains numerous capillary blood-vessels, a few scattered cells, and the extensions of the processes of the nerve-cells; it almost completely encloses the stratum granulosum, and is itself covered by

4. The **stratum marginale,** an extremely thin sheet of **medullated nerve-fibres** representing the outer medullary layer of the cornu Ammonis, of which it is the direct, although attenuated, continuation.

The **fimbria** receives the fibres constituting the alveus, and is composed entirely of **bundles of medullated nerve-fibres,** together with the intervening connective-tissue septa; the thick fibre-bundles extend longitudinally, and are continued into the tracts of the posterior pillar of the fornix.

The **septum lucidum** represents a **rudimentary cortex** due to the arrest of development following the isolation of this part of the wall of the cerebral vesicle by the growth of the corpus callosum.

Since the so-called **fifth ventricle** is really a cut-off portion of the great longitudinal fissure, those surfaces directed towards the cleft correspond to the free surface of the hemispheres; the **rudimentary layer of gray matter,** therefore, forms the immediate lateral boundaries of this space, and is **homologous with the cortex** of other regions, while the thin **white stratum** next the lateral ventricles **represents the medulla.**

The mesially-placed **gray cortex of the septum lucidum** contains a thin superficial stratum of **medullated nerve-fibres** next the interseptal cleft; following this lies a layer of gray matter containing many **small pyramidal cells** (16–18 μ), the apical processes of which are directed towards the surface homologous with the periphery of the hemispheres; the deeper zone of the gray matter exhibits **spindle-cells.** The white substance of the hemisphere is represented by the thin **stratum of medullated fibres** interposed between the gray layer and the ependyma of the lateral ventricle.

The **blood-vessels supplying the cerebral cortex,** after a short course within the pia almost parallel to the free surface, enter the nervous tissue vertically; the **larger arteries** pierce the gray matter and **enter the medulla,** while those of **smaller size** break up **within the gray cortex** into capillary net-works. The law, applicable to all parts of the nervous system, that *regions rich in large nerve-cells are plentifully supplied with blood-vessels,* is illustrated by the distribution of the capillaries within the cortex, where a rich capillary net-work exists within the layer of large pyramidal cells, while the outer cortical zones, on the contrary, possess only a meagre capillary supply: the net-works within the deepest layers of the cortex are intermediate in the closeness of their meshes. The blood-vessels are surrounded by **perivascular lymph-spaces,** the pial tissue accompanying the vessels as a delicate sheath attached to the adventitia and enclosing a **prolongation of the subarachnoidean space.**

The **corpus striatum** consists of the special masses of gray matter, the **nucleus caudatus** and the **nucleus lenticularis,** and their associated tracts of nerve-fibres.

The **ventricular surface of the nucleus caudatus** is covered by a well-developed layer of **ependyma,** beneath which lies the zone of **gray substance,** containing nerve-cells of two kinds: **large multipolar cells** (25–30 μ), and much more numerous **smaller ganglionic elements,** whose size is about half that of the former. The **outer surface** of the caudate nucleus, directed towards the internal capsule, is broken up by numerous **bundles of fibres,** which penetrate deeply into the gray mass and produce the characteristic **white striæ** exhibited on section.

The **outer division**, or the **putamen**, of the **nucleus lenticularis** closely resembles, both in color and in structure, the caudate nucleus, with which, indeed, it anteriorly becomes continuous. The paler color of the **inner segments**, the **globus pallidus**, depends

FIG. 346.

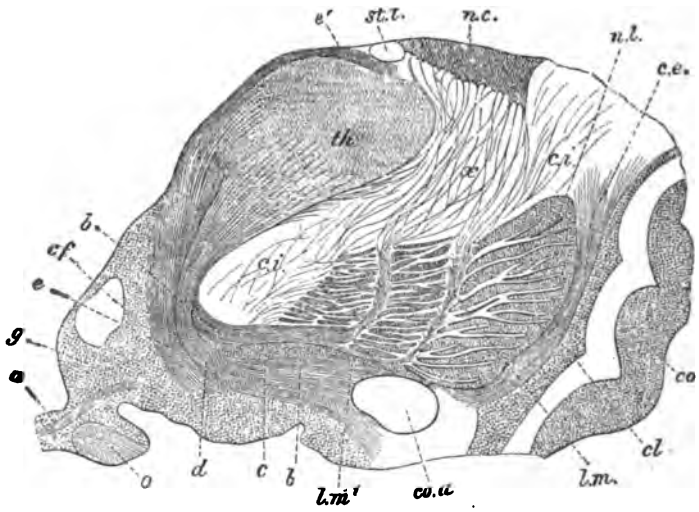

Section across anterior end of thalamus, striatum, and insula: *th*, anterior end of thalamus; *st.t.*, stria terminalis; *n.c.*, nucleus caudatus; *n.l.*, outer segment of nucleus lenticularis; *l.m.*, *l.m.'*, external and internal medullary lamina receiving fibres (*x*) from caudate nucleus; *c.i.*, internal capsule; *c.e.*, external capsule; *cl*, claustrum; *co*, cortex of island of Reil; *co.a.*, anterior commissure; *g*, central gray matter of third ventricle, *a*, its commissure; *cf.*, section of anterior pillar of fornix; *b*, *c*, *d*, *e*, elements of subthalamic region; *e'*, stratum zonale of thalamus; *o*, portion of optic tract. (After *Schwalbe-Meynert*.)

not only upon the presence of greater numbers of medullated fibres, but also upon the lighter tint of the yellowish pigment contained within the multipolar nerve-cells. The nerve-cells contained within the **claustrum** are principally **fusiform elements** whose long axes correspond in direction with the neighboring free surface.

The **optic thalamus** is composed chiefly of **gray matter**, through which extend various tracts of **nerve-fibres.** The surfaces directed towards the ventricles are sharply defined, the **upper** or **dorsal aspect** being covered by a layer of medullated nerve-fibres, the **stratum zonale**, about .8 mm. in thickness, which fade away on the mesial surface; the **outer** and **ventral borders** of the thalamus, on the contrary, are invaded by fibres from the respectively adjacent internal capsule and the subthalamic region.

The **gray matter** of the thalamus is divided by **tracts of fibres** into a shorter median segment, the **inner nucleus**, and a longer

external division, the **outer nucleus,** the fore-segment of the thalamus containing the **anterior** or **upper nucleus.** The gray substance composing these segments is traversed in many places by bundles of medullated nerve-fibres; in the **outer nucleus** the narrow fibre-bundles and the zones of gray substance alternate, **fusiform ganglion-cells** (20–30 μ), arranged parallel to the course of the fibres, occupying the gray bands. In addition to the comparatively large cells found within the anterior nucleus, the **bundle of Vicq d'Azyr,** reflected from the mammillary body below, enters the anterior ventral border of the segment and contributes numerous fibres to its mass. The **multipolar cells** of the **anterior nucleus,** as well as those of the posteriorly situated **pulvinar,** are of large size.

The **central gray matter** of the third ventricle is the direct continuation of that lining the Sylvian aqueduct and other parts of the neural tube. The middle or **gray commissure** of the ventricle contains **transverse fibres,** in addition to numerous **pigmented ganglion-cells;** posteriorly it is intimately blended with the gray substance of the thalamus, while anteriorly it is separated from the latter by a medullary layer, the inferior stalk of the thalamus.

The **corpus subthalamicum,** situated within the region of similar name, is composed of a very close net-work of **fine medullated fibres,** among which are distributed moderate-sized **multipolar nerve-cells;** the **capillary net-work** of this nucleus is remarkable for the closeness of its meshes. The continuation of the area of pigmented cells forming the **substantia nigra** within the cerebral crus separates the subthalamic region from the fibre-tracts of the crusta.

The **corpora quadrigemina,** the homologues of the optic lobes and corpora bigemina of the lower animals, comprise a **posterior** and an **anterior pair** of eminences.

The **posterior quadrigeminal bodies** consist in great part of gray substance which forms a **lenticular nucleus** on either side, and contains numerous small multipolar cells (16–18 μ), as well as a few elements of larger size; the nuclei of the two sides are united by a gray commissure. A thin superficial lamina of medullated nerve-fibres, the **stratum zonale,** covers in the gray matter.

The **anterior quadrigeminal bodies** differ from the posterior in the complexity of their structure brought about by the presence of the root-tracts of the optic nerve. In transverse section these bodies present **four layers,** which, from the upper or dorsal surface towards the Sylvian canal, are—

1. The **stratum zonale,** enveloping the superficial portions of

the bodies; in man and apes this layer is unusually well developed, reaching a thickness of 30–40 μ; the interlacing fibres, derived from the optic tract, form a lamina rather than distinctly-grouped bundles.

2. The **stratum cinereum,** a cap-like mass of gray matter, embracing the subjacent optic fibres, and containing numerous nerve-cells of varying size, the larger ones occupying the deeper parts of the layer.

3. The **stratum opticum,** consisting of the continuation of the preceding gray matter, through which extend the bundles of optic nerve-fibres entering by the superior brachium; posteriorly the fibres are fine, while anteriorly they become robust to take part in the

FIG. 347.

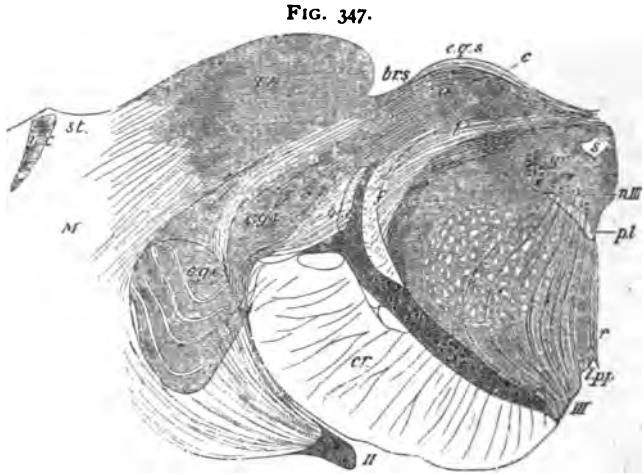

Section across superior corpora quadrigemina and adjacent part of thalamus: 1, Sylvian aqueduct; *gr*, gray matter of aqueduct; *c.q.s.*, quadrigeminal body, consisting of, *l*, stratum lemnisci, *o*, stratum opticum, *c*, stratum cinereum; *Th*, thalamus (its pulvinar); *c.g.i.*, *c.g.e.*, internal and external geniculate bodies; *br.s.*, *br.i.*, superior and inferior brachia; *f*, upper fillet; *p.l.*, posterior longitudinal bundle; *r*, raphé; *III*, third nerve; *n.III*, its nucleus; *l.p.p.*, posterior perforated space; *s.n.*, substantia nigra, above this tegmentum with circular nucleus; *cr*, crusta; *II*, optic tract; *M*, medulla of hemisphere; *n.c.*, nucleus caudatus; *st*, stria terminalis. (After *Quain-Meynert*)

constitution of the optic tract. Among the profusely distributed nerve-cells are elements of considerable size whose axis-cylinder processes extend largely within the underlying zone.

4. The **stratum lemnisci,** including gray matter as well as nerve-fibres, many of the latter being continuations of tracts connecting lower levels.

The **geniculate bodies,** lateral and mesial, are closely associated

respectively with the anterior and the posterior corpora quadrigemina by means of the corresponding **brachia.**

The **lateral** or **external geniculate bodies** exhibit a characteristic structure, consisting of alternate layers of white and gray matter; the **white striæ** are composed largely of fibres derived from the optic tracts, the **gray zones** probably also receiving collateral connections from the retina. The **nerve-cells** of the gray matter, many of which are large and deeply pigmented, send axis-cylinder processes as far as, possibly, the occipital cortex. The **mesial** or **inner geniculate bodies** contain numerous nerve-cells of medium size, together with fibres seemingly connected with the mesial root of the optic tract; an intimate relation between these bodies and the optic fibres, however, is questionable.

The masses of **gray matter** forming the structures along the fore part and the floor of the **third ventricle,** including the **lamina cinerea, tuber cinereum, infundibulum,** and **posterior perforated space,** contain scattered **ganglion-cells,** together with certain **special bundles of nerve-fibres.** The **corpora mammillaria** are composed of bundles of fibres, and contain **gray nuclei** within the **superficial layer of white matter.** The hollow conical **infundibulum** bears at its lower extremity the **pituitary body,** with part of which the funnel-shaped extension of the cerebral vesicle is at one time continuous.

THE OLFACTORY LOBE.

The structures described in human anatomy as the **olfactory nerves** represent the **rudimentary olfactory lobes,** which in many of the lower animals constitute conspicuous divisions of the brain. This lobe, as found in man, comprises three parts,—the **tuber olfactorium,** the **tractus olfactorius,** and the **bulbus olfactorius.**

The **tuber olfactorium** does not here call for attention, since its adequate consideration lies without the purpose of these pages.

The **tractus olfactorius,** on transverse section, exhibits **zones of white and gray matter,** together with a central flattened area of **neuroglia,** indicating the position of the **obliterated lumen,** which in the embryonic condition temporarily, and in the lower animals permanently, existed as a continuation of the ventricular cavity.

The **gray substance** is richest in the dorsal part of the tract, where it forms an **oval area** surrounded by medullated nerve-fibres; these latter become continuous at the lateral angles with the thick **medullary fibre-layer** occupying the ventral zone, the juncture between the two being marked by a thickening of the medullary

stratum. Enclosed within the continuous ring of fibres lies the flattened **gelatinous** or **neuroglia zone** corresponding to the area of the obliterated former lumen of the tract. Outside the fibre-layer, a **sheet of gray substance,** extremely thin on the ventral surface, **represents the cortex** of the convolution.

FIG. 348.



Section of portion of human olfactory bulb: 1, 3, bundles of transversely-cut nerve-fibres, enclosing central neuroglia (2); 4, 5, 6, granule layer; 7, zone of olfactory glomeruli (*g*); 8, layer of olfactory nerve-fibres, bundles (*o*) of which pass from olfactory mucous membrane. (After *Henle*.)

The Bulbus Olfactorius. While the layers present in the tract are continued into the terminal **olfactory bulb,** the greater development of the ventral zone considerably modifies the structure of this division of the olfactory lobe. In the bulb the **area of the obliterated ventricular cavity** lies eccentrically, closely approaching the dorsal surface, from which it is separated by a thin **layer of fibres** and the greatly attenuated **gray cortical stratum,** here reduced to a delicate lamina. The **ventral layers,** on the contrary, are greatly developed, and culminate in the nerve-fibres which pass through the cribriform plate as the true olfactory nerves.

In transverse section, the dorsal portion of the **olfactory bulb** is occupied by (1) the central neuroglia, the atrophic field representing the obliterated lumen of the lobe; this area is enclosed by (2) the **flattened ring** of **medullary substance,** consisting of closely-placed bundles of **longitudinal nerve-fibres.**

Next the ventral portion of the medullary ring lies (3) the **stratum granulosum,** a thick zone of **gray matter** containing numerous **ganglion-cells** of different size. Some of these are small irregular elements, and immediately beneath the ring constitute a dense aggregation. The most conspicuous elements of the gray matter, however, are the **large pyramidal** or **mitral cells** (30–50 μ) which occupy the deeper parts of this stratum.

The **protoplasmic processes** of the mitral cells extend ventrally and terminate in **two ways**, as shown by the investigations of Golgi, Ramón y Cajal, Retzius, and others. In addition to the apical fibrils, **lateral processes** diverge and terminate in **free arborizations** within the ventral portion of the gray matter. The **apical processes** take part in the formation of (4) the **olfactory glomeruli**, peculiar masses (.05–.3 mm.) composed of **dense interlacements** of terminal ramifications of the **apical processes** sent out by the mitral cells and of the **olfactory nerve-filaments.** The **axis-cylinder processes** of the mitral cells pass dorsally and become continuous with nerve-fibres of the medullary ring; during their course they give off recurrent **collateral branches.**

FIG. 349.

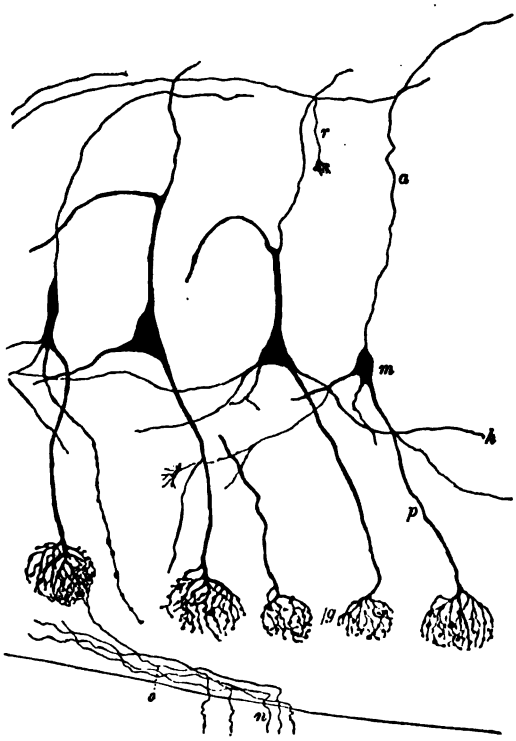

Sagittal section of part of olfactory bulb of young rabbit, stained after Golgi's silver method: *m*, mitral ganglion-cells from which pass axis cylinder processes (*a*), sending off recurrent collateral branches (*r*) and protoplasmic processes (*p*); *h*, horizontal processes extending tangentially; *g*, glomeruli from whose complex of nerve-fibrils pass olfactory nerves (*o*); *n*, filaments ascending from mucous membrane. (After *Retzius*.)

The layer of **olfactory glomeruli** is followed by (5) the **stratum of olfactory nerve-fibres.** These are **non-medullated,** and arise in the **olfactory cells** of the Schneiderian membrane, whence they pass into the cranium and end in **arborizations included within the olfactory glomeruli,** to whose formation they thus contribute. The exterior of the olfactory bulb is invested by a **layer of pia** broken by the passage of the nerve-fibres and the blood-vessels.

THE WHITE MATTER OF THE CEREBRUM.

The parts of the cerebrum thus far considered have included areas composed chiefly of gray substance; it remains to notice briefly the complex mass of **nerve-fibres** forming the conspicuous **medulla.** It has already been stated that the **nerve-fibres** constituting these central masses are mostly **medullated,** but **devoid of a neurilemma;** the fibres vary in diameter, those pursuing an extended course connected with the large motor cells possessing, in general, a greater diameter than those related with sensory areas.

The accurate determination of the arrangement of the various nerve-tracts included within the medulla is a labor of great difficulty and one still far from satisfactory completion; notwithstanding the great advances made in this field of investigation since the introduc-

FIG. 350.

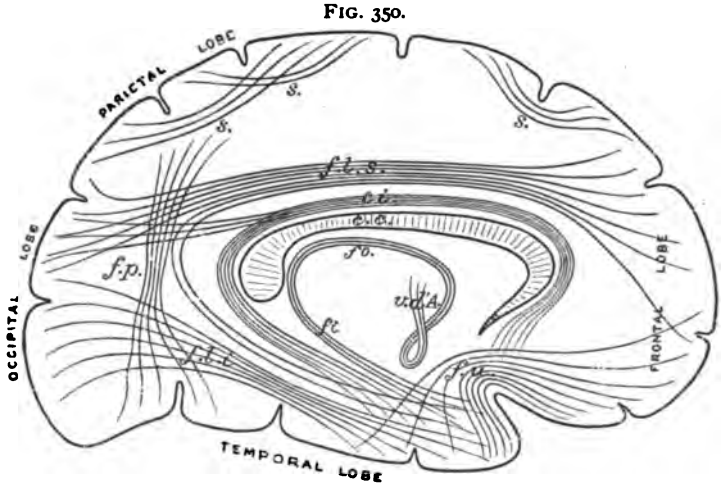

Diagram of association fibres of cerebrum: *s*, short fibres connecting adjacent gyri; *f.l.s.*, superior longitudinal, *f.l.i.*, inferior longitudinal, *f.u*, uncinate, and *f.p.*, perpendicular fasciculus; *ci*, cingulum; *fo*, fornix; *fi*, fimbria; *v.d'A.*, bundle of Vicq d'Azyr. (After *Schaefer-Meynert.*)

tion of the improved methods (Weigert's) for tracing medullated fibres, much remains to be learned regarding the course and the distribution of many tracts connecting the central nuclei with the cerebral cortex.

The great mass of the **cerebral medulla** is composed of **fibre-tracts,** which may be grouped into three systems:

1. The **association fibres,** connecting parts of the same hemisphere.

2. The **commissural fibres,** uniting parts of the two hemispheres,

and represented by the fibres of the **corpus callosum** and of the **anterior commissure.**

3. The **projection fibres,** streaming from the entrance of the brain-stalks, or cerebral peduncles, secondarily also from the basal nuclei, to spread out in the various parts of the cerebral cortex and thus constitute the conspicuous **corona radiata.**

The **association fibres** consist of bundles of various length, which unite : (*a*) **adjoining convolutions,** passing from the medulla of one, beneath the intervening fissure, into the white matter of the neighboring gyrus; (*b*) **adjacent convolutions,** but not immediately adjoining; (*c*) **more distant parts** of the hemisphere.

The most important of these longer tracts are :

1. The **fasciculus uncinatus,** connecting the inferior frontal convolution with the uncinate gyrus of the temporal lobe.

2. The **fasciculus longitudinalis inferior,** connecting the anterior part of the temporal with the apex of the occipital lobe.

3. The **fasciculus longitudinalis superior,** connecting the middle of the frontal partly with the occipital and partly with the apex of the temporal lobe.

4. The **cingulum,** extending along the corpus callosum within the gyrus fornicatus.

5. The **fasciculus perpendicularis,** connecting the inferior parietal with the fusiform lobe.

6. The **fornix,** connecting the uncinate process of the hippocampal convolution with the thalamus by means of the continuations effected by the fimbria behind and the bundle of Vicq d'Azyr, from the mammillary body to the thalamus, in front.

The majority of the **commissural fibres,** which connect similar regions on the two sides, take part in the formation of the great transverse bridge, the **corpus callosum;** these fibres, the prolongations of the axis-cylinder processes of the cortical ganglion-cells or of the collateral processes derived from the projection fibres, pass to all parts of the cerebral surface, with the exception, probably, of the anterior portions of the temporal lobes and the olfactory tracts, which parts are connected by the fibres of the **anterior commissure.** On either side of the closely-packed bundles constituting the immediate bridge the fibres spread out in a fan-like course to reach their destination.

The **projection** or **peduncular fibres** include many of the most important tracts by means of which communication between the presiding cortical centres and the more deeply lying nuclei and paths is established. The bundles of the **crusta** on reaching the subthalamic region become continuous with the **internal capsule** and spread out into the conspicuous **corona radiata.** The fibres which

gain the cortex, however, do not correspond exactly with those entering the cerebrum as the peduncular bundles, since some of the latter are deflected and pass to the caudate and the lenticular nucleus from the internal capsule; on the other hand, the peripherally-streaming bundles are augmented by fibres which come from the **thalamus** and the **subthalamic region.** The peduncular tracts continued to the cortex consist principally of the **pyramidal fibres,** the fibres from the caudate and lenticular nuclei, and the fibres to the temporo-occipital region from the optic thalamus and the pons.

The **tracts of the tegmentum** largely contain fibres related to the connections of the thalami, the cerebellum, and the corpora quadrigemina; regarding the exact course and communications of these bundles much still remains to be determined.

Two small but remarkable organs, the pituitary and the pineal body, are closely associated in their genetic relations with the cerebrum, since the first of these bodies originates partly and the second entirely as a diverticulum from the cavity of the primary inter-brain.

THE PITUITARY BODY.

The **pituitary body,** or **hypophysis cerebri,** consists of two portions, the large **anterior oral** and the small **posterior cerebral division.** These are entirely distinct both in structure and in development, since the **anterior lobe** is derived as a **diverticulum** from the **primitive oral cavity,** and, as such, is lined with the oral **ectoderm,** while the **posterior lobe** descends as an **outgrowth** from the floor of the **primary inter-brain,** its stalk remaining as the **infundibulum.**

FIG. 351.

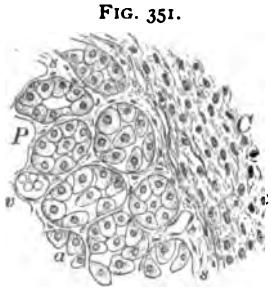

Section of human pituitary body: *C*, portion of posterior or nervous lobe; *P*, portion of anterior or glandular lobe, consisting of tubular acini (*a*); *s*, connective-tissue septa; *v*, blood-vessels.

In the embryo temporarily, and in many lower vertebrates permanently, the tissues composing the **posterior lobe** assume a distinctly **nervous type;** in the higher animals, however, this character is lost, the lobe remaining small and rudimentary and its cavity undergoing obliteration; the primary nervous character of the cerebral lobe disappears as the **ingrowth** of the **connective tissue** and the **blood-vessels** takes place. The **remains** of the immature nervous elements are sometimes recognized in the branched and spindle **pigmented cells** found in this part of the pituitary body, as well as in the partially-preserved **cavity** lined with ciliated columnar cells.

The **anterior lobe**, larger and darker than the preceding, for some time remains connected by its **tubular ectodermic stalk** with the primitive oral cavity; later the tube becomes atrophic and finally disappears, the end of the oral diverticulum then lying isolated and separated from the buccal cavity. The single primary tube undergoes **repeated division**, producing compartments which appear in the adult organ as slightly convoluted **tubular acini**. The **tubules** are held together by vascular connective tissue, and contain **polyhedral epithelial cells**, with spherical or oval nuclei, irregularly disposed and often almost filling the alveoli; the lumina of the tubules are sometimes occupied by **colloid masses** resembling those of the thyroid gland.

THE PINEAL BODY.

The **pineal body, epiphysis,** or **conarium**, since the comparatively recent investigations of Spencer and of de Graaf, although known and described previously for centuries, is now regarded as a **rudimentary sense-organ.** These investigators independently demonstrated that the structure seen in man and the higher animals is the rudiment of what was a functionating sense-organ in the extinct reptiles, and even in certain living members of the same class strongly resembles an imperfect invertebrate eye in its early embryonal condition. In the light of our present knowledge, therefore, this peculiar body must be looked upon as representing an imperfect organ of special sense, whether as an additional visual structure—the "**pineal eye**"—or as an organ for the perception of warmth still remains to be determined.

FIG. 352.

Sagittal section through part of head of lizard embryo, showing so-called pineal eye: *P*, specialized isolated extremity of pineal diverticulum from brain-vesicle (*B*); *b*, *c*, so-called retinal and lenticular areas of its walls; *a*, ectoderm; *d*, remains of diverticulum undergoing division into tubules (*d'*); *f*, blood-vessels; *e*, mesodermic tissue.

In man and other mammals the pineal body, instead of occupying its morphologically normal position on the superior surface of the brain, is covered over by the greatly developed cerebral hemispheres, so that its final position is well towards the base of the encephalon. The organ at no time in the higher ani-

mals assumes the characters of a sense-organ to the extent seen in the lower types.

The adult human **pineal body** is composed of a number of **tubular compartments** or **alveoli,** which are separated by septa of connective tissue and lined by **polyhedral epithelial cells;** in many places the tubules are almost occluded by **epithelium,** together with aggregations of gritty **calcareous matter,** the so-called "**brain-sand.**" The brain-sand, or **acervulus cerebri,** consists of irregularly round mammillated or mulberry-form **concretions** of variable size, composed of animal matter combined with earthy salts (calcium carbonate and phosphate with magnesium and ammonium phosphate). These deposits are not limited to the interior of the pineal body, but are encountered on its exterior and on the peduncles, as well as in the choroid plexus and in other parts of the brain-membranes; the concretions occur at all ages, even before birth, and within the perfectly normal organ.

FIG. 353.

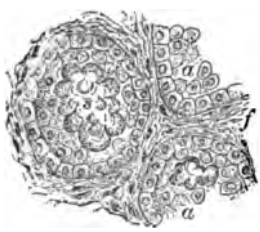

Section of human pineal body: *a*, *a*, acini lined and partially filled with epithelium and calcareous concretions (*s*); *f*, intertubular fibrous tissue.

FIG. 354.

Corpora amylacea from lateral ventricles of human brain.

Other bodies, the **corpora amylacea,** occur as round discoidal masses, and exhibit a distinct **concentric striation;** they are regarded as amylaceous in nature, since they respond to the tests for such substances, staining violet with iodine and sulphuric acid. These bodies are almost constant within both the gray and the white matter constituting the walls of many parts of the brain-cavities; the olfactory tract is a particularly favorite situation, along this region the amylaceous corpuscles occurring with especial profusion.

THE SUPRARENAL BODY.

The close relations of this organ with the nervous system, as evidenced by its early history, the profusion of its nervous elements, and the results of pathological processes, entitle the suprarenal body to place, provisionally at least, within the present chapter.

The **parenchyma** of the organ, composed of a peripheral zone, the **cortex,** and a central area, the **medulla,** is invested by a **fibrous capsule** of considerable thickness. From this envelope numerous **connective-tissue septa** penetrate deeply into the soft cellular substance, which is thus broken up into cylindrical masses.

The **cortex** consists of aggregations of irregularly rounded or

polygonal cells (13–17 μ), whose granular protoplasm frequently contains fat-particles in addition to clear nuclei. The arrangement of the cortical elements varies at different levels, the resulting disposition giving rise to the **three divisions** of the cortex recognized as the **zona glomerulosa,** the **zona fasciculata,** and the **zona reticularis.** The **cells** forming the first of these are grouped as **oval masses,** those of the middle layer are disposed as long **cylindrical groups,** and those of the third stratum are irregularly arranged as **anastomosing cords** supported within a reticulum of connective tissue. The **zona reticularis** is distinguished from the other cortical layers by the **pigmented condition** of its cells. The various groups of cellular elements are separated from one another by delicate **fibrous septa,** continuations from the outer connective-tissue envelope; the **larger septa** support the capillary net-works which surround the groups of cells.

FIG. 355.

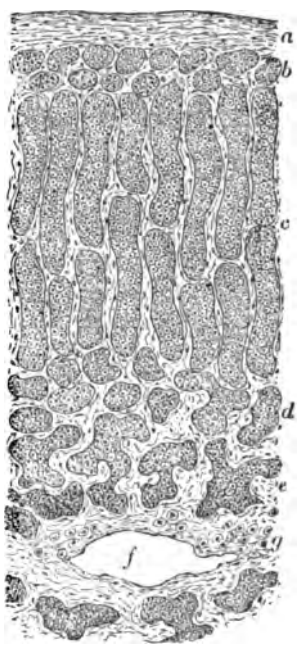

Section of human suprarenal body: *a*, fibrous capsule; *b*, zona glomerulosa; *c*, zona fasciculata; *d*, zona reticularis; *e*, medullary cords; *f*, venous channel; *g*, ganglion-cells.

The **medulla** contains granular, frequently feebly-pigmented, **polygonal cells** arranged as **cords** and **irregular net-works** within a framework of highly vascular connective tissue. Numerous **ganglion-cells** occupy the central portions of the medulla, along with a rich net-work of **non-medullated nerve-fibres** and the conspicuous **venous channels.**

The **blood-vessels** of the organ divide within the capsule into numerous smaller branches, which enter the parenchyma along the fibrous septa; **capillary net-works** surround the cell-groups of both cortex and medulla. The **veins** of the medulla are of large size and unite to form trunks which make their exit at the central hilus; the larger radicles are accompanied by **longitudinal bundles of non-striped muscle.**

The **nerves** of the suprarenal body are remarkable for their **number** and **size**; they bear the arteries company within the septa to reach the medulla, where they form an **intricate plexus** composed chiefly of **non-medullated fibres. Ganglion-cells** occur along

the course of the nerve-trunks, and are found within the medulla in considerable numbers.

The **lymphatics** are represented by delicate canals within the fibrous septa which communicate with the intercellular clefts of both cortex and medulla on the one hand, and with the larger lymph-vessels within the capsule on the other.

THE DEVELOPMENT OF THE NERVOUS TISSUES.

The consideration of the general changes involving the primary neural tube and its cephalic expansions, the brain-vesicles, by which are produced the various portions of the cerebro-spinal axis, belongs to embryology, and lies without our present purpose; an account of the **histogenesis** of the nervous tissues, however, is of much interest in indicating the true relations of the structural components of the great nervous masses.

The **essential parts** of the nervous system, including **the nerve-cells,** the **nerve-fibres,** and the **neuroglia,** are developed from the **ectoderm alone,** and all result from the differentiation and specialization of the **walls of the primary neural tube.**

This canal is formed by the gradual closure of the early furrow, the **medullary groove,** of the **invaginated ectoderm** along the dorsal line; by the approximation of the upper or dorsal edges of the involution the furrow is converted into a tube, the sides, or **medullary plates,** of the extreme anterior and posterior segments of which are the last to unite. Even before the closure of the groove has been completed a **differentiation** of two important regions is indicated; these are the **areas** giving rise to the **segmental ganglia** and to the general **axial nerves.**

FIG. 356.

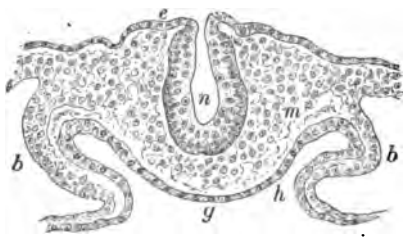

Section of nine-day rabbit embryo, showing open neural tube: *e*, ectoderm invaginated and thickened within neural canal (*n*); *m*, mesoderm; *b*, body-cavity; *g*, still open gut, lined by entoderm (*h*).

The area for the latter is represented by the **lining of the neural tube,** that for the former by the inconspicuous cell-groups lying on either side of the **line of closure.**

The **primary wall** of the neural tube consists of a single layer of **columnar epithelial cells,** whose nuclei occupy the middle third of the elements, leaving an outer and an inner free zone; within the latter appears very early a **second variety of cell,** which is distinguished by its large **spherical form** and conspicuous **nucleus.** The

round cells invading the inner zone represent the **ancestors** of the **nervous elements**—both cells and fibres—and are the **germ-cells**, while the **columnar cells** produce the **neuroglia** and are the **spongioblasts.**

FIG. 357.

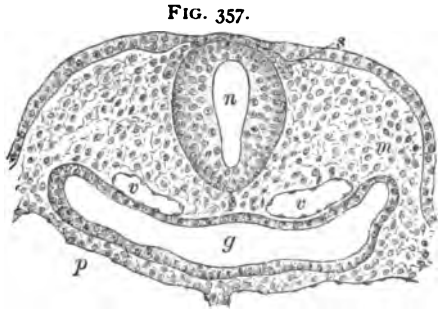

Section of ten-day rabbit embryo, showing closed neural tube: *n*, neural canal; *s*, area from which segmental ganglia develop; *m*, mesodermic tissue; *g*, gut-tube; *v*, *v*, primitive aortæ; *p*, pleuro-pericardial cavity.

The **development of the nerve-cells** proceeds from the **germ-cells**, which, as shown by the karyokinetic figures within their nuclei, undergo **active proliferation**, the resulting progeny being the **neuroblasts**, from which the **nerve-cells** are directly derived. The **germ-cells** are confined to the **zone next the brain-cavity**, which thus indicates the position of greatest formative energy.

The **neuroblasts** at first occupy the **innermost zone**, next the cerebral cavity, but soon migrate towards the outer boundary of the wall, at the same time becoming pyriform and elongated. The young **nerve-cells** for a long time possess but a **single process**,

FIG. 358.

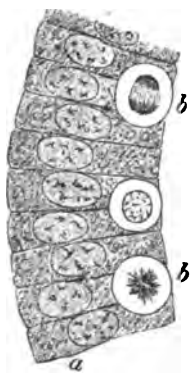

Primary wall of neural tube composed of single layer of epithelium (*a*); *b*, *b*, germ-cells occupying inner zone. (After *His*.)

FIG. 359.

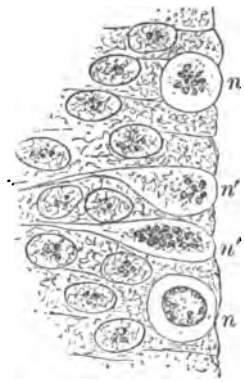

Portion of inner zone of wall of neural tube in which round germ-cells (*n*, *n*) and partially-developed neuroblasts (*n'*, *n'*) lie among the surrounding spongioblasts. (After *His*.)

which grows out to become a nerve-fibre, and therefore represents the **axis-cylinder**, or **nerve-process**; the **protoplasmic pro-**

cesses, whose ramifications later present such striking pictures, are **subsequently acquired,** after the lapse of considerable time.

FIG. 360.

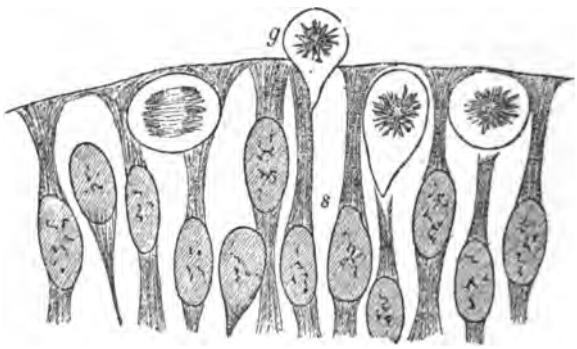

Portion of wall of neural tube, exhibiting germ-cells (*g*) among the differentiating spongioblasts (*s*). (After *His.*)

The **development of the neuroglia** depends upon the **specialization** of the columnar elements, the **spongioblasts.** The epithelial cells elongate, their protoplasm at the same time undergoing **vacuolation** and **partial absorption,** resulting in the production of an elongated framework of connected **slender trabeculæ.** The **extremities** of the changed epithelial elements, or spongioblasts, greatly differ; the **inner ends** of the cells extend to the inner boundary, where they are united to form a **continuous sheet,** the **membrana limitans interna,** and the **outer processes** break up into irregular branches, which ultimately form a **close reticulum.** The early spongioblasts extend the **entire thickness** of the neural wall, but with the subsequent increase in this structure their attachments become broken, the spongioblasts then lying free among the surrounding nervous elements. The general growth of the tissues is accompanied by great **extension** and **subdivision** of the **neuroglia fibres,** which eventually become the nucleated masses of fine, bristle-like processes

FIG. 361.

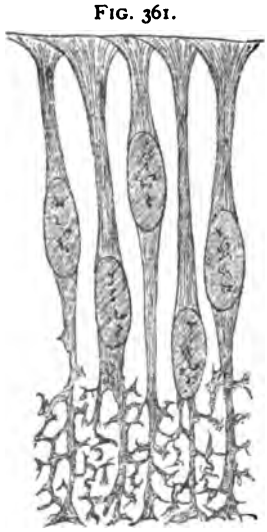

Spongioblasts from neural tube; their expanded upper ends unite to constitute the internal limiting membrane next the brain-cavity; their outer ends break up into reticulum. (After *His.*)

constituting **Deiters's** or **spider cells.** The **spongioblasts** immediately around persistent parts of the **neural canal** retain their inner connection and form a **continuous layer** of lining elements, which later constitute the **ciliated columnar epithelium** of the ependyma.

The **development of the nerve-fibres** includes the origin of **two sets** of primary fibres—those derived from the **nerve-cells of the medullary tube** and those growing out from the **cells of the ganglia. All nerve-fibres** are formed as the **direct extensions** and **continuations** of the processes of the **neuroblasts.** In the case of those proceeding from the **neural canal** the fibres **grow peripherally** and the cells remain attached to their **central ends,** thus early establishing the relations afterwards existing between the **motor** cells and the fibres; those originating from the **ganglia,** on the other hand, grow in **two directions,** towards the periphery and towards the nervous axis, representing the **sensory paths.**

The early **nerve-fibres** consist for some time of the **axis-cylinder alone,** the neurilemma and the medullary substance being not only much later acquisitions but also contributions from the **mesoderm.** The **neurilemma** first envelops the ectodermic axis-cylinder as a delicate sheath, and subsequently within this envelope the myeline of the **white matter of Schwann** is deposited. The appearance of this coat is often very late, and takes place at different times for the various tracts of nerve-fibres, although the **period** at which the several groups acquire their **medullary substance** is **constant** and **definite for each set.** The young fibres soon collect into groups, which represent the **early nerve-trunks,** whose further growth proceeds in a **straight path** corresponding with the general direction of the component axis-cylinders; a course once established is maintained until arrested by some obstacle or modified by changes in the position of the parts with which the nerve has formed attachments. The **terminations** of the growing nerves are **abrupt,** the finer ramifications appearing only after the trunk has undergone repeated branchings.

CHAPTER XVII.

THE EYE AND ITS APPENDAGES.

THE EYEBALL.

THE **bulbus oculi** consists of **three coats**: 1, **the external fibrous tunic,** comprising the sclerotic and the cornea, upon which devolves the maintenance of the form of the organ; 2, **the middle vascular tunic,** made up of the choroid, the ciliary body, and the iris, to which the principal vascular supply of the eye is distributed; 3, **the inner nervous tunic,** the retina, which receives the terminal expansion of the optic nerve and contains the specialized neuro-epithelium concerned in the perception of the visual stimulus. The aqueous humor, the crystalline lens, and the vitreous body are enclosed by these coats, and represent the refractive media of the eye.

Referred to their **embryonic origin,** the several parts of the eye may be grouped under two headings,—**those developed from the ectoderm** and **those derived from the mesoderm.** The members of the first group may be subdivided into (*a*) structures **derived directly** from the ectoderm, including the lens and its anterior epithelium, and the epithelium of the cornea and of the adjacent scleral surface, and (*b*) structures **derived secondarily** from the ectoderm through the optic vesicles protruded from the involuted ectoderm of the cerebral vesicles; to this class belong the primary retinal tissues, including the pigment-layer, as well as the atrophic retinal layers continued over the posterior surface of the ciliary body and the iris. All **other parts** of the eyeball, comprising the remaining portions of the sclera, the cornea, the iris, the ciliary body, the choroid, and the vitreous body, as well as the connective-tissue ingrowths of the retina, **are developed from the mesoderm.**

THE CORNEA.

The **cornea** consists of **five layers**:

1. *The anterior epithelium.*
2. *The anterior limiting membrane.*
3. *The substance proper.*
4. *The posterior limiting membrane.*
5. *The posterior endothelium.*

The **anterior epithelium,** the only part of the cornea derived from the ectoderm, all others being mesodermic, is **stratified squa-**

mous in character; it is thinnest over the central part of the cornea, where its six to eight layers of cells together measure about 45 μ, at the periphery reaching almost double that thickness. The **deepest cells** are **columnar** in form with their outer ends somewhat rounded off, while their bases are slightly expanded and conform to the surface of the basement-membrane upon which they rest. Succeeding the deepest layer the elements become **broader** and **polyhedral,** many possessing the protoplasmic threads characteristic of **prickle-cells.** The **superficial strata** are composed of **flattened cells** which lie parallel to the surface and contain oval nuclei.

FIG. 362.

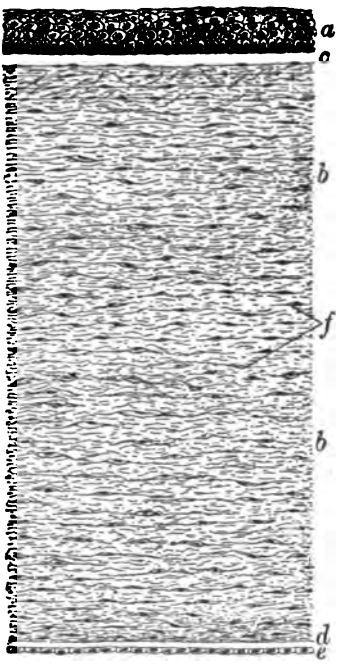

Section of human cornea: *a*, anterior epithelium; *c*, anterior limiting membrane; *b*, *b*, fibrous substantia propria, containing corneal corpuscles (*f*) lying within corneal spaces; *d*, posterior limiting membrane; *e*, endothelium lining anterior chamber.

The **anterior limiting membrane, membrane of Bowman,** or **lamina elastica anterior,** corresponds to a highly-developed basement-membrane, being continuous with the tissue of the substantia propria, of which it is a **special condensation.** The structure is especially conspicuous in the human cornea, where it appears as a seemingly **homogeneous glassy layer,** about 20 μ in thickness in the middle of the cornea, gradually diminishing towards the periphery. The **resolution** of this lamina into delicate **connective-tissue fibrillæ** after treatment with suitable reagents demonstrates its true nature as a specialized portion of the substantia propria.

The **fibrous stroma,** or the **substantia propria,** constitutes the chief bulk of the cornea, and is made up of parallel **lamellæ** composed of interlacing **bundles of fibrous connective tissue.** The exact number of corneal lamellæ is inconstant, since this depends upon the extent to which the artificial separation of the tissue is carried. The interlacing **bundles of the white fibrous tissue** composing the lamellæ are united by the **interfibrillar cement** substance, and cross one another obliquely at various angles, the adjacent bundles being intimately united by bands, the **fibræ arcuatæ,** which pass from one bundle to the other; the arcuate fibres are especially prominent

in the **anterior lamellæ.** The substantia propria resembles the matrix of cartilage in **yielding chondrin** on boiling, therein differ-

FIG. 363.



Interlacing bundles of fibrous tissue constituting substantia propria from cornea of ox; interstitial injection with silver nitrate.

ing from the sclera, which, like the usual connective tissues, produces gelatin.

The **cellular elements,** the **corneal corpuscles,** are plate-like or stellate **connective-tissue cells,** whose branched processes unite

FIG. 364.

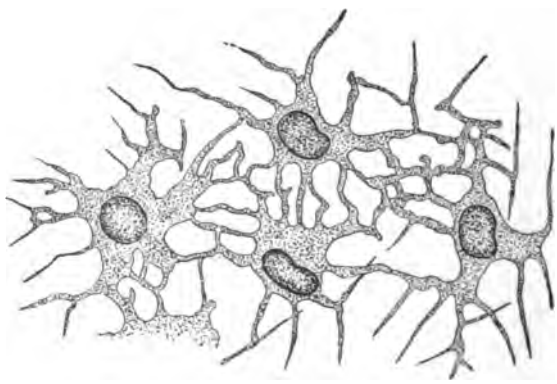

Corneal corpuscles from calf; gold preparation.

with those from adjacent cells to constitute a **protoplasmic reticulum** throughout the tissue. The corneal cells and their processes lie within a system of **intercommunicating lymphatic spaces**

hollowed out within the cement-substance, which consists of the large **lacunæ** or **corneal spaces** between the lamellæ and the small **canaliculi** extending from the former as fine branching tubes. The corneal corpuscles are usually applied to **one wall** of the spaces, which they by no means completely fill, while their processes extend within the branching canaliculi. In addition to the corneal corpuscles, **wandering cells,** together with the **tissue-juices,** occupy the spaces and canaliculi.

FIG. 365.

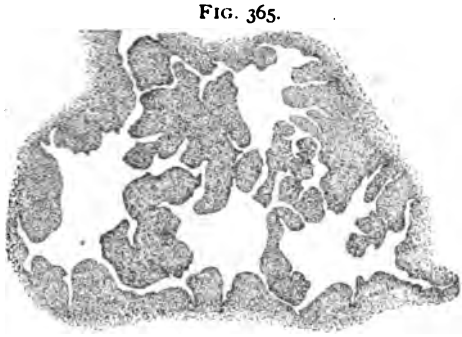

Corneal spaces from calf: silver preparation.

The **posterior limiting membrane, membrane of Descemet,** or **posterior elastic lamina,** appears as a clear **homogeneous band** at the inner boundary of the cornea, sharply defined from the deepest layers of the substantia propria and clothed on its inner surface by **endothelium.** The membrane differs from the corresponding anterior lamella in its less intimate attachment with the

FIG. 366.

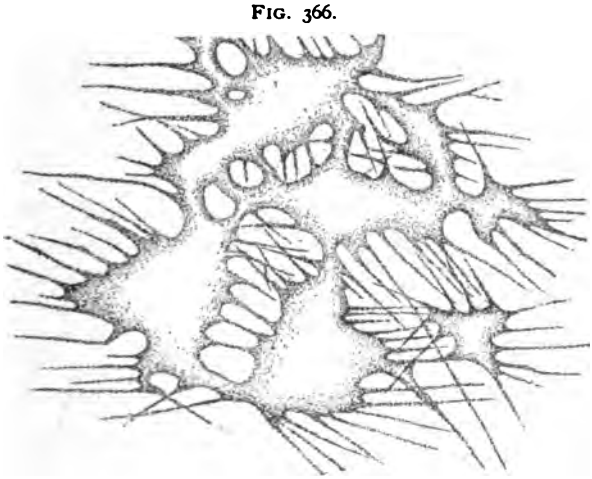

Corneal spaces from calf; exhibited spaces in positive picture after interstitial silver injection.

fibrous stratum and in possessing the greatest thickness (10–12 μ) at the periphery. After prolonged maceration or treatment with suitable reagents the resistant lamina is separable into a number of **thin**

homogeneous layers, which sometimes exhibit a delicate longitudinal striation.

The **posterior corneal endothelium,** or **endothelium of Descemet's membrane,** consists of a single layer of regular **polyhedral plates,** whose oval nuclei project slightly beyond the bodies of the cells.

Blood-vessels are absent in the cornea, except within a narrow zone, about 1 mm. in width, at the limbus or margin; in the **fœtus,** however, the vessels extend well towards the centre and form the **precorneal capillary net-work.**

The **lymphatics** of the cornea are represented by the system of **intercommunicating spaces** and **canaliculi;** these clefts open into lymphatic radicles at the periphery, which, in turn, communicate with the larger anterior lymphatic vessels. **Perineurial lymph-channels** enclose the larger nerve-trunks, which they accompany for a variable distance into the corneal tissue; these lymphatic channels communicate directly with the corneal spaces at frequent intervals.

The **nerves** of the cornea are very numerous, and are distributed largely within the anterior layers. They enter at the corneal limbus as some sixty radially-disposed twigs, each of which includes from

FIG. 367.

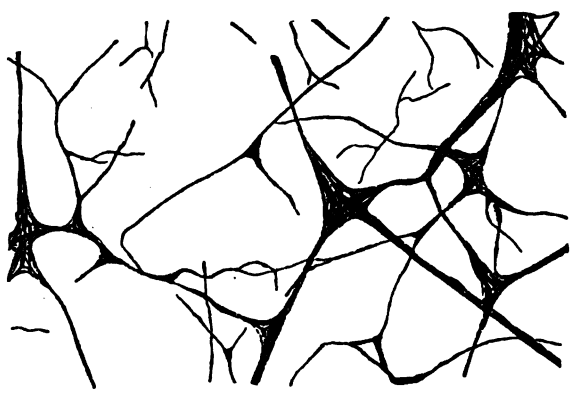

Subbasilar plexus of corneal nerves from rabbit; gold preparation.

three to twelve fibres; the latter almost at once, within .5 mm. of the limbus, become non-medullated.

Within the substantia propria the nerve-fibres form a coarse **ground-plexus** at a level corresponding to about the middle third of the corneal tissue; from this net-work twigs are sparingly given off to supply the **deepest layers,** while others pass towards the

anterior lamellæ, in which they form net-works. Immediately beneath the anterior elastic membrane the smaller fibres form the dense **subbasilar plexus,** while under the epithelium the finest fibrillæ constitute the **subepithelial plexus,** from which delicate naked axis-cylinders ascend and enter the epithelium, to end between the cells as the **intra-epithelial plexus.**

THE SCLERA.

The **sclera** is composed of the same elements as is the substantia propria of the cornea, but they are less regularly disposed and lack the remarkable transparency of the latter.

The **ground-substance** is made up of interlacing bundles of gelatin-yielding fibrous tissue mingled with elastic fibres; the **fibrous bundles** are arranged as **two** principal sets, those extending **longitudinally** or **meridionally** and those running **transversely** or **equatorially.**

The **interfascicular interspaces** are occupied by the stellate **connective-tissue plates,** which correspond closely to the corneal corpuscles; in addition, a few small **wandering cells** are usually present. The sclerotic and choroid coats are united by a layer of loose connective tissue, the **lamina suprachoroidea,** the extensive interfascicular clefts of which form part of the **subscleral lymph-space.**

FIG. 368.

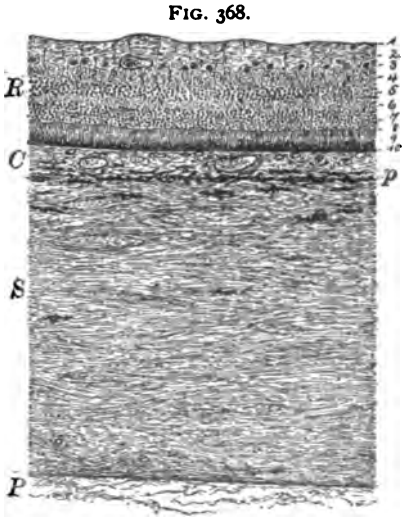

Section of human eyeball taken midway between equator and posterior pole: *S*, sclera; *P*, lamina fusca and lamina suprachoroidea; *P*, perischeral tissue; *C*, choroid; *R*, retina with its layers indicated by figures.

The **suprachoroidal tissue** consists of many imperfect lamellæ composed of a **fibro-elastic groundwork** supporting irregular groups of flattened endothelioid connective-tissue plates; the broad trabeculæ join one another at various angles, and include the imperfectly separated compartments of the general lymph-space. The **larger partitions** convey the numerous vascular and nervous trunks in their course to and from the choroid.

The deeply-pigmented tissue of the **innermost layer** of the sclera, next the **subscleral space,** constitutes the **lamina fusca,** and is covered with the **endothe-**

lial lining of the lymph-cavity. The **outer surface** of the sclera throughout a large part of its extent takes part in bounding the **episcleral space,** where it is likewise covered with **endothelium.**

The **blood-vessels** distributed to the tissue of the sclerotic coat are meagre, although the tunic is pierced by numerous trunks related with the supply of the underlying parts; such small vessels as are present break up into capillaries passing among the bundles of fibrous tissue.

The **lymphatics** are represented by the intercommunicating cell-spaces which connect with the larger lymph-cavities.

The **nerves** terminating within the sclera constitute fine twigs given off from the larger trunks passing between the sclerotic and choroid coats; they break up into fibrillæ which end as naked axis-cylinders between the bundles as an interfascicular plexus.

THE CHOROID.

The **choroid** consists of a **connective-tissue stroma** supporting numerous **blood-vessels.** Dependent largely upon the size and arrangement of the blood-vessels, certain layers are distinguished, these being, from without inward:

1. *The layer of choroidal stroma* containing large blood-vessels.
2. *The layer of dense capillary net-works*—the *choriocapillaris.*
3. *The homogeneous glassy lamina*, or *vitreous membrane.*

The **stroma-layer,** with its large blood-vessels, constitutes the greater part of the choroid. Within a **supporting tissue** made up

FIG. 369.

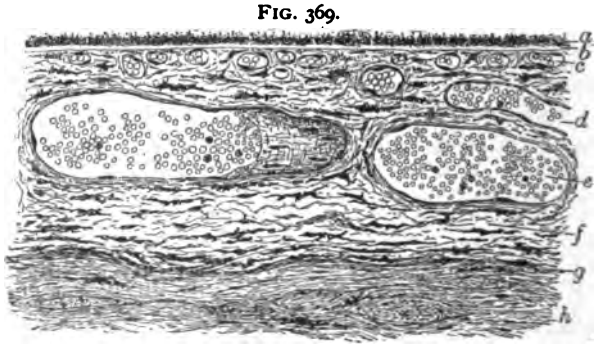

Section of human choroid: *a*, retinal pigment adhering to vitreous membrane (*b*); *c*, capillary layer, or choriocapillaris; *d*, *e*, large blood-vessels of stroma-layer (*f*); *g*, lamina suprachoroidea; *h*, tissue of sclera.

of closely united **connective-tissue lamellæ, elastic fibres,** and branched **pigmented cells,** the freely branching arterial and venous trunks take their course, appearing as lighter-colored channels within the darker surrounding matrix. The blood-vessels and the stroma

are so intimately united that they constitute a layer of considerable consistence. The **largest vessels** occupy the **most superficial part** of the stratum, those next in size the middle, while the **smallest** approach the **capillary zone.** The most conspicuous of the large superficial blood-channels are the four **venæ vorticosæ,** with their whorls of tributaries. These veins occupy positions around the equator at points about equidistant, towards which the smaller vessels converge from all directions, returning the blood not only from the choroid but also from the ciliary body and the iris. The veins of the choroid are often surrounded by **perivascular lymph-sheaths.** Many of the **larger arteries,** in addition to the well-marked circularly-disposed muscle with which they are provided, are accompanied by **external longitudinal bundles of involuntary muscle.**

The **innermost part** of the stroma-layer, next the choriocapillaris, forms a narrow stratum (10 μ in width) which is devoid, or nearly so, of pigment, and constitutes the **boundary zone.** In the eyes of many animals (horse, cow, sheep) this layer possesses wavy bundles of connective tissue, to whose peculiar arrangement

FIG. 370.

Human choroid seen from its inner surface, exhibiting surface view of capillary net-work, or choriocapillaris (*c, c*); *b, b,* large blood-vessels of stroma-layer beneath; *a, a,* intervening stroma-tissue.

is due the **metallic reflex** sometimes seen from such eyes; this shining structure is known as the **tapetum fibrosum,** as distinguished from the iridescent **tapetum cellulosum** of the carnivora which is dependent upon the presence of several layers of **plate-like cells** containing innumerable **small crystals.**

The **capillary layer,** or **choriocapillaris,** consists of a narrow

zone, about 10 μ in width, at the inner part of the choroid, composed of a structureless, apparently **homogeneous, matrix,** in which lie embedded the **close capillary net-works** derived from the terminal branches of the short ciliary arteries.

The **vitreous lamina,** or **glassy membrane,** forms the most internal layer of the choroid and supports the retinal pigment. The membrane presents a delicate **homogeneous stratum** (2 μ in thickness), ordinarily without appreciable structure, and is very intimately associated with the adjoining layer of the choroid; to its inner surface patches of **retinal pigment** frequently adhere on removal of the retina.

The **nerves** of the choroid, non-medullated fibres distributed to the blood-vessels, are derived from the plexus formed within the suprachoroidal tissue by branches given off from the long and short ciliary nerves in their transit through the subscleral space.

THE CILIARY BODY.

This structure includes that portion of the uveal tract situated between the **termination of the choriocapillaris,** opposite the ora serrata behind and the ciliary or **outer margin of the iris** in front. Within this important territory three areas may be distinguished: 1, the **ciliary ring**; 2, the **ciliary processes**; 3, the **ciliary muscle.**

FIG. 371.

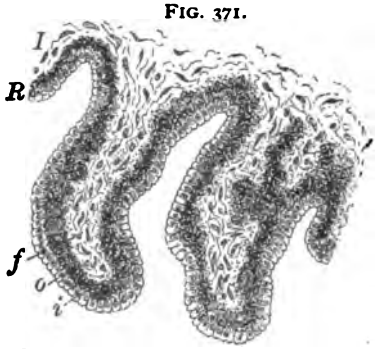

Section of human ciliary processes; *I*, interstitial connective-tissue stroma, covered by retinal layers (*R*); *i*, *o*, inner clear and outer pigmented layers of cells; *f*, fibrous tissue of processes.

The **ciliary ring,** or **orbiculus ciliaris,** is a circular tract about 4 mm. in breadth, situated immediately in front of the **ora serrata** and extending to the posterior ends of the ciliary processes. This zone differs from the choroid in the **absence of the choriocapillaris** and in the **presence of muscular tissue** prolonged from the mass of the ciliary muscle; the character of the stroma also changes, its bulk being here made up of fibrous connective bundles instead of elastic lamellæ.

The **ciliary processes** consist of an annular series of some seventy prominent radial vascular folds which project from the inner surface of the ciliary body and arise from the confluence of several of the low ridges on the ciliary ring; after attaining a height of about 1 mm., they abruptly end at the base of the iris, sinking

to the level of the underlying ciliary muscle. The **stroma** of the processes is a continuation of the connective tissue of the orbicular zone, this layer being the true prolongation of the choroid, since the muscular tissue must be regarded as an intercalation between the sclerotic and choroid coats. The **vitreous lamina** is continued as a delicate homogenous membrane, 3 to 4 μ in thickness, over the inner surface of the ciliary processes. Inside this layer the internal face of this entire region, including the ciliary ring and the ciliary body, as well as the iris, is covered by the **deeply-pigmented rudimentary layers of the pars ciliaris retinæ,** consisting of an **inner small** row of **tall columnar elements** and an **outer** sheet of **low pigmented epithelium.** Since these layers represent the rudimentary folded anterior laminæ of the ectodermic **optic vesicle,** the ciliary processes and the iris consist of **two genetically distinct parts,** the

FIG. 372.

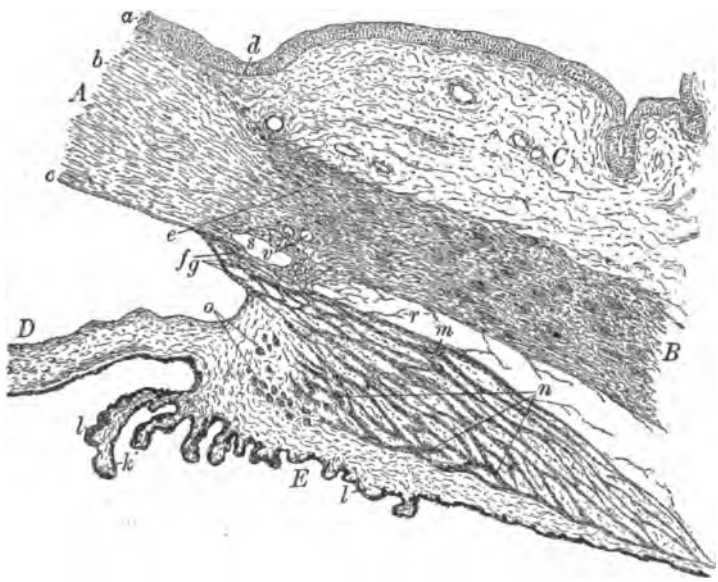

Section through ciliary region of human eye: *A*, cornea; *a*, *b*, *c*, its epithelium, substantia propria, and endothelium; *C*, scleral conjunctiva, terminating at *d*; *B*, sclera; *e*, sclero-corneal juncture; *D*, iris; *E*, ciliary body covered by pigment-layer, *l*; *k*, fibrous stroma of ciliary processes; *f*, bands of pectinate ligament; *g*, spaces of Fontana; *s*, canal of Schlemm; *v*, venous channels; *m*, *n*, *o*, meridional, radial, and circular (Müller's) fibres of ciliary muscle; *r*, subscleral space bridged by fibrous bands.

mesodermal connective-tissue stroma, containing blood-vessels and muscle-fibres, and the inner **deeply-pigmented ectodermal stratum.**

The **ciliary muscle** presents a conspicuous thickening for about 1 mm., which extends from the orbicular zone to the base of the iris and bears on its inner surface the connective-tissue stroma of the ciliary processes and the orbicular ring. In meridional sections its mass appears as a triangular area, the cross-section of a **three-sided annular band of muscle** entirely encircling the eyeball. The **triangle** thus formed closely approximates a right angle whose sides are unequal; the **shorter anterior side** extends from the sclero-corneal juncture towards the ciliary processes, and the **longer inner border** is prolonged to meet the outer side or hypothenuse at an acute angle at the anterior border of the choroid.

The mass of the **ciliary muscle** consists of interlacing **bundles of involuntary muscle,** the interspaces between which are filled by **connective tissue.** The **muscular fasciculi** are arranged as **three sets,** the **meridional,** the **radial,** and the **circular.** The **meridional fibres** lie generally parallel to the sclera, and form a compact layer attached **in front** at the **sclero-corneal junction,** near the anterior margin of **Schlemm's canal,** and **behind** at the **fore margin of the choroid,** where, in common with many of the radial fibres, it finds insertion; in recognition of this attachment, the meridional and radial fibres were named the **tensor choroideæ.** The **radial bundles** spread out fan-like from their anterior attachment, the most external fibres running nearly parallel to the meridional bundles, with which they become continuous, while the anterior pass off at a considerable angle. The **circular fibres,** the **ring-muscle of Müller,** constitute a distinct group of equatorially-disposed bundles, which occupy the internal angle of the ciliary muscle and extend at right angles to the preceding bundles.

The **blood-vessels** of the ciliary body are especially concerned in supplying the **ciliary muscle,** to which minute arterial twigs pass from the imperfect vascular circle lying behind the arterial circle of the iris.

The numerous **nerves** of the ciliary muscle are derivatives of the ciliary trunks, which on entering the muscle form a **plexus** within its substance; from this plexus fibres pass **internally to the iris, outwardly to the cornea,** while others are distributed **to the ciliary muscle** itself. Small **ganglion-cells** also occur, singly or in small groups.

THE IRIS.

The **iris** constitutes the anterior segment of the **uveal tract,** and consists of a principal **stroma-layer** covered in front by a reflection of the **corneal endothelium** and behind by the continuation of the **deeply-pigmented rudimentary retinal layers**—the *pars iridica*

retinæ. The various components of the iris and their morphological relations may be grouped as follows:

1. *Anterior endothelium.*
2. *Anterior boundary layer,*
3. *Vascular stroma-layer,*
4. *Posterior boundary layer,*

} Continuation of the tissues of the *uveal tract* proper, constituting the *stroma-zone.*

5. *Pigment-layer,* { *a.* Anterior layer of *pigmented spindle*-cells representing **outer layer**; *b.* Posterior layer of *pigmented polygonal* cells representing **inner layer** } of OPTIC VESICLE.

The **anterior endothelium** consists of a single layer of thin **nucleated polygonal plates,** the direct prolongation of the corneal endothelium. The protoplasm of the cells is finely granular, but always free from pigment.

The **anterior boundary layer** is formed by modification of the foremost stratum of the iris-stroma; the connective tissue consti-

FIG. 373.

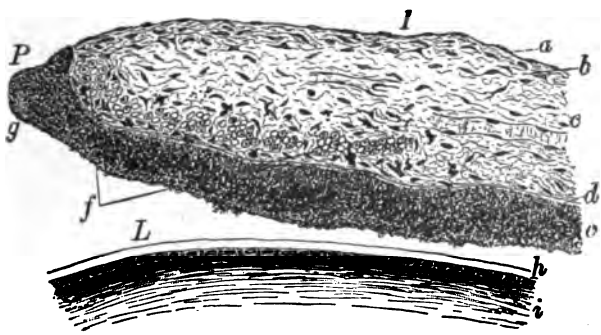

Section through part of iris and lens, from human eye: *I*, iris; *a*, anterior endothelium; *b*, anterior boundary layer; *c*, vascular stroma; *d*, posterior boundary layer; *e*, pigment-layer continued as far as *g* on pupillary margin (*P*); *f*, cut circular muscle-bundles of sphincter; *L*, surface of crystalline lens; *h*, anterior lens capsule, with anterior epithelium beneath; *i*, tissue of lens.

tuting this layer resembles the reticular tissue of lymphatic structures, comprising several layers of **net-works** within the interspaces of which lie **lymphoid cells** in greater or less profusion.

The **vascular stroma** constitutes the chief mass of the iris, and, in addition to its numerous **blood-vessels,** contains **involuntary**

muscle and **nerves.** The **stroma** consists of loose spongy **reticular connective tissue** greatly strengthened by the radially-disposed **blood-vessels** and **nerves,** around which the delicate stroma forms **ensheathing masses** of considerable density. The **clefts** situated between these adventitious sheaths and the included vessels and nerves form a system of **lymphatic channels** throughout the iris which communicate with the anterior chamber through the lymph-spaces at the irido-corneal angle.

The **arteries** of the iris spring from the anterior part of the **circulus arteriosus iridis major,** situated at the **ciliary border,** and pass towards the centre of the iris as radially-disposed, freely-anastomosing twigs; about 1 mm. from the inner edge of the iris these vessels unite to form a second delicate vascular ring, the **circulus arteriosus iridis minor,** which marks the division of the iris into its **pupillary** and **ciliary zones,** which are respectively 1 mm. and 3–4 mm. in breadth. From this circle the arterioles continue their course towards the pupillary border, and end in the **capillary network** distributed to the **sphincter muscle.** Capillary reticula exist also within the **anterior** and **posterior layers** of the stroma. All the capillaries are tributary to the radiating veins which pass to the ciliary border, where they join those of the ciliary processes and finally empty into the radicles forming the venæ vorticosæ.

FIG. 374.

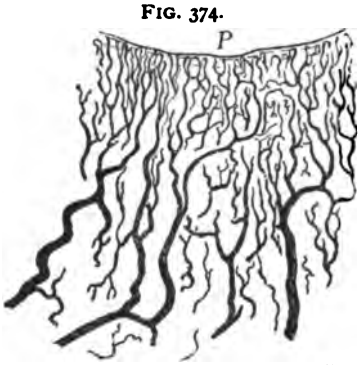

Injected iris from eye of dog: *P*, pupillary margin, around which capillary net-work is formed by vessels proceeding from lesser arterial circle.

Bundles of **involuntary muscle** occupy the **pupillary border** and the **posterior zone** of the stroma-layer; these are arranged as **two** sets,—the **annular bundles** encircling the pupillary margin of the iris and constituting the **sphincter of the pupil,** a muscular zone about 1 mm. in width, and the ill-developed **radially-disposed bundles** extending from the pupil towards the ciliary margin and forming an incomplete and very inconspicuous layer, the **dilator pupillæ.**

The **posterior boundary layer,** or **vitreous lamella,** appears as a glassy structureless membrane, about 2 μ in thickness, which stretches over the **posterior surface of the stroma** and **supports** the **pigment-layer**: in the nature of its substance this structure closely approaches **elastic tissue.**

The **pigment-layer,** or **pars iridica retinæ,** is usually so densely

packed with deeply-colored particles that its real constitution is masked. This stratum is composed of **two layers**, an anterior and a posterior. The **anterior or outer layer** is formed of radially-arranged **spindle-cells** which pass without interruption from the ciliary border of the iris to the pupillary margin; at the **ciliary border** the cells change their form and arrangement, becoming **polyhedral** and **circularly disposed** and continuous with the low pigmented elements constituting the corresponding layer of the ciliary processes.

The **posterior layer** presents a thicker zone (30–35 μ) of **pigmented cells**, in which the colored particles are so densely packed that the cell-boundaries and the nuclei are completely masked, the entire layer appearing as one continuous mass of pigment.

The **pigment-layer** covers the entire pupillary margin, and often ends as a somewhat thickened free edge slightly in advance of the plane of the iris; at this border, which **represents** the **free anterior lip** of the embryonic **secondary optic cup**, both strata of the pigment-layer become continuous.

The **posterior surface** of the pigment-layer is covered by a very delicate **cuticular membrane**, the **membrana limitans iridis**, which is continued from the similar structure extending over the ciliary processes; it appears first at the ora serrata as a new formation, since a true membrana limitans interna, in the sense of a distinct cuticle, does not exist over the retina proper.

The marked variation in the **color of the iris** is largely dependent on the **amount** and **position** of its **pigment**. In blue eyes the **stroma** of the iris is **entirely free from pigment**, the latter being confined to the posterior pigment-layer, from which position it is seen through the superimposed iridal strata. With the darker color of the iris its **stroma-cells** also **acquire pigment**; in light gray eyes this is small in amount, in brown eyes greater, while in the darkest eyes the colored particles are very numerous and sometimes appear as almost continuous pigmented areas; in albino eyes, on the other hand, even the retinal portion of the iris is devoid of pigment.

The **nerves** of the iris, derived from the **intra-muscular ciliary plexus**, enter the more superficial part of the stroma-layer as **medullated fibres**. Within the iris the nerve-fibres soon lose their medullary sheath and form one or two **irregular net-works**, the most constant of which is a **circular plexus** in the vicinity of the **sphincter muscle**; from this net-work pale fibres are distributed to the **substance** of the latter **muscle**. The principal plexus lies anterior to the plane of the chief vascular net-work, the posterior zone of the iris being poorly supplied with nerves.

The **irido-corneal angle**, marking the junction of the cornea, the

sclera, the iris, and the ciliary muscle, constitutes one of the most important regions in the eye, not only with regard to its anatomical details, but also in view of its practical clinical significance.

As already described, the substantia propria of the cornea passes directly into the ground-substance of the sclera; in consequence of the **rearrangement** of the tissue-elements of the two structures taking place soonest in the superficial planes of the cornea, the **line of transformation** becomes oblique, thereby producing an apparent overlapping of the sclera in front, and a corresponding extension of the cornea behind.

The **posterior elastic membrane,** on reaching the corneal margin, splits up into a number of stiff homogeneous fibres, many of which become attached to the base of the iris and constitute the **ligamentum pectinatum iridis.** By the union of the processes from the iris and Descemet's membrane with the elastic fibres derived from the anterior attachment of the ciliary muscle and a few bands from the sclera, a **reticulum** of **thin trabeculæ** is formed, which occupies the angle between the cornea and the iris. This spongy tissue constitutes an **annular mass** enclosing a system of intercommunicating cavities, the **spaces of Fontana.** These clefts, lined

FIG. 375.

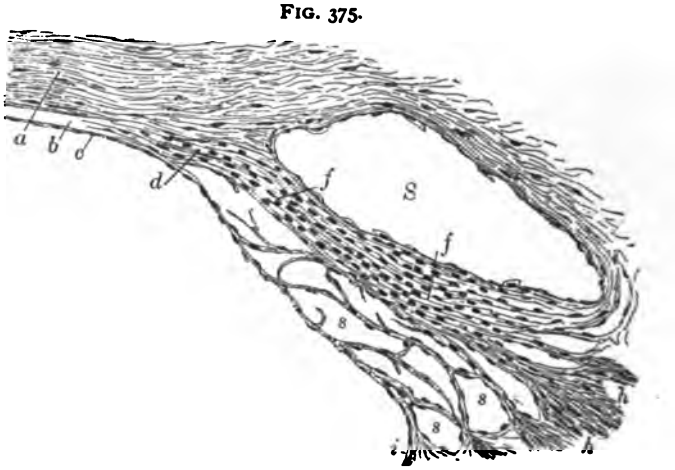

Section through irido-corneal angle of human eye, highly magnified: *a*, substantia propria of cornea; *b*, posterior limiting membrane, splitting at corneal margin into delicate lamellæ (*d*); *c*, endothelium continued over iris (*i*); *f*, elastic lamellæ separating Schlemm's canal (*S*) from spaces of Fontana (*s*, *s*) and giving attachment to fibres of ciliary muscle (*h*).

by an imperfect layer of **endothelium,** are more conspicuous in the eyes of some of the lower animals (horse, ox, pig, sheep), where they are far better developed than in man.

Within the sclera, close to its inner border and the corneal juncture,

lies a **flattened annular channel,** the **canal of Schlemm**; the inner wall of this canal is formed by intersecting delicate lamellæ whose loose disposition effects but **incomplete isolation** of the channel from the adjacent **spaces of Fontana.** Schlemm's canal, which may be regarded as a venous channel, is connected with the anterior ciliary veins; the communication thus established between the anterior chamber and the venous radicles is important as allowing the escape of the aqueous humor.

THE RETINA.

The inner **nervous tunic** of the eyeball includes the **retina** alone, which extends from the optic entrance throughout the posterior segment of the ball and as far forward as the pupillary margin of the **iris.** This extensive tract, corresponding in its morphological limits to the **secondary optic vesicle,** falls into three divisions: (1) the **pars optica retinæ,** including the entire posterior segment and ending at the ora serrata; (2) the **pars ciliaris retinæ,** covering the posterior surface of the ciliary zone and processes and extending from the ora serrata to the base of the iris; and (3) the **pars iridica retinæ,** passing over the posterior surface of the iris from the base to the anterior edge of the pupil, where it terminates as a slightly-thickened margin, which corresponds to the free lip of the double-layered optic cup.

The **retina proper,** or **pars optica retinæ,** consists of an **inner** and an **outer lamina,** which correspond to the inner and outer layers of the optic vesicle; the **outer lamina** includes the pigment-layer alone, while the **inner lamina** embraces the remaining layers of the retina. The inner lamina permits further subdivision of its structures into the **neuro-epithelial** and the **cerebral layer.** The relations of these divisions to the individual retinal layers may be expressed:

I. Outer layer of optic vesicle.	Pigment-layer.	*A. Pigment layer.*
II. Inner layer of optic vesicle.	Layer of rods and cones;	*B. Neuro-epithelial layer.*
	Limiting membrane;	
	Outer nuclear layer;	
	Outer reticular layer;	*C. Cerebral layer.*
	Inner nuclear layer;	
	Inner reticular layer;	
	Ganglion-cell-layer;	
	Nerve-fibre-layer.	

The retinal structures consist of two parts,—the **nervous elements** and the **supporting neuroglia.** The **supporting tissues** contribute a considerable part of the entire retina, but differ in their amount in the several layers. The most conspicuous constituents of the supporting framework are long **neuroglia-fibres,** the **radial**

fibres of Müller, which extend through the entire thickness of the retina. The expanded **inner ends** of the supporting fibres are so closely applied that they produce a seemingly continuous membrane, the so-called **membrana limitans interna.** The **radial fibres** rapidly diminish in diameter beyond their bases, and are continued as narrow irregular stalks giving off lateral branches in profusion to the reticular layers; within the inner nuclear layer each fibre presents an irregular **nucleated enlargement,** and gives off lateral processes for the support of the nervous elements of the inner nuclear layer, as well as to each of the succeeding layers. At the

FIG. 376.

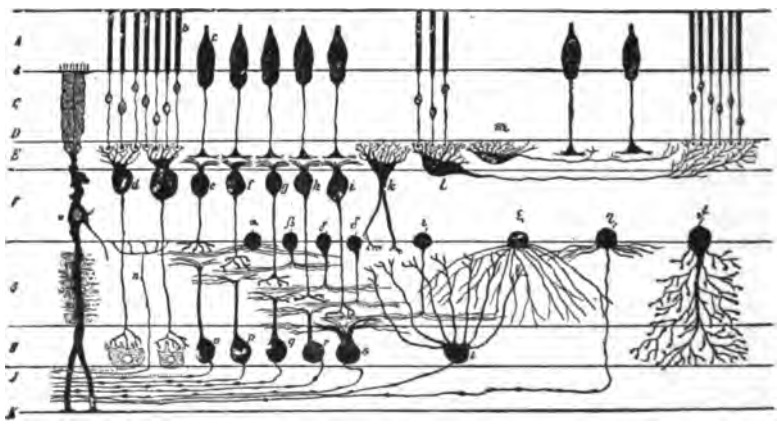

Diagram illustrating the relation of the retinal elements. *A*, layer of rods and cones; *B*, limitans externa; *C*, outer nuclear layer; *E*, outer reticular layer (between the two (*D*) Henle's fibre-layer); *F*, inner nuclear layer; *G*, inner reticular layer; *H*, layer of ganglion-cells; *I*, fibre-layer; *K*, limitans interna. *a*, supporting fibres of Müller; *b*, *c*, rod- and cone-visual cells; *d*, bipolars belonging to rod-cells; *e–i*, bipolars belonging to cone-cells; *k–m*, horizontal nerve-cells; *n*, centrifugal nerve-fibres; *o–t*, ganglion-cells connected with optic fibres; *α–ε*, spongioblasts or amacrines arranged in layers; *ζ*, *ϑ*, diffuse amacrines; *η*, nervous amacrine. (*Kallius after Ramón y Cajal.*)

inner border of the rods and the cones the expanded ends of the neuroglia-fibres form the **external limiting membrane,** delicate processes extending from the latter between the bases of the rods and the cones, which they surround and embrace as the "**fibre-crates.**" In addition to the long radial fibres, richly-branched **neuroglia-cells** occur within the outer reticular layer to the fibre-complex of which they contribute.

Within the meshes of the framework just described the **nervous elements** of the retina are distributed in a manner characteristic for each layer: a brief consideration of these is therefore necessary.

The **nerve-fibre-layer** contains the **continuations** of the **optic fibres** which, after having lost their medullary substance in their passage through the lamina cribrosa, radiate as **naked axis-cylinders** to all parts of the retina as far as the **ora serrata.** The fibre-layer is **thickest** at the edge of the optic disk and **thinnest** at the extreme retinal periphery. Sooner or later the fibres forsake their peripherally-directed course, and, bending sharply, pass almost perpendicularly to the ganglion-layer and other strata.

FIG. 377.

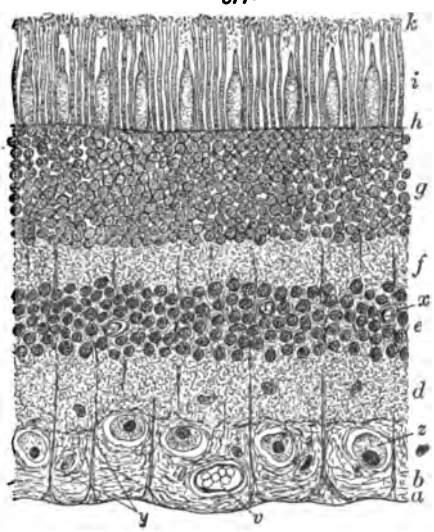

Section of human retina: *a*, internal limiting membrane formed by apposition of expanded basis of Müller's fibres (*y*); *b*, fibre-layer; *c*, layer of ganglion-cells (*z*); *d*, *e*, inner reticular and inner nuclear layer; *f*, *g*, outer reticular and outer nuclear layer; *h*, outer limiting membrane; *i*, layer of rods and cones; *k*, portion of pigment-layer; *v*, *x*, blood-vessels.

The **ganglion-cell-layer** consists of a **single row** of large **multipolar nerve-cells** (15 to 30 μ), whose **axis-cylinder processes** are directed towards the fibre-layer; their **branched protoplasmic processes,** when well developed, pass into the inner reticular zone, to meet the arborizations of the cone-bipolars. The **ganglion-cells** in the central part of the retina are densely packed in the **macula,** constituting overlying rows, but towards the periphery they are less plentiful, and at the ora serrata infrequent.

The **inner reticular layer** presents a characteristic reticulated tissue composed of **neuroglia net-works** and the **rich arborizations** of various nerve-cells; the processes originate from both the elements of the **ganglion-layer** and the cells of the adjacent **nuclear stratum.**

The **internal nuclear layer** includes a number of distinct elements, and presents two subdivisions: (*a*) an **inner layer** of nerve-cells, the **spongioblasts,** or **amacrines,** and (*b*) an **outer layer** of the rod- and cone-bipolars forming the **ganglion retinæ.** The "**spongioblasts**" are not concerned in the production of the sustentacular tissue, as their name—given under erroneous ideas regarding their function—would imply, but are **nervous elements** whose branched **protoplasmic processes** are resolved within the inner reticular layer into arborizations. The **cone-bipolars** send their

axis-cylinder processes into the inner reticular layer, to end at various levels in arborizations in relation with the terminal filaments of the ganglion-cells; their **protoplasmic processes** extend as far as the outer reticular layer, where they terminate in ramifications beneath the cone-cells. The **protoplasmic processes** of the **rod-bipolars** end beneath the rod-cells, their **axis-cylinder processes** penetrating the inner reticular stratum, to end in close relation with the ganglion-cells.

The **outer reticular layer** appears as a narrow zone made up of an intricate **net-work of fine fibres** with sparingly distributed **nuclei.** The fibrillæ are derived from the **neuroglia** and from the **processes of nerve-cells,** among which are the **horizontal cells** whose axis-cylinder processes extend horizontally within the layer, often for considerable distances, to end beneath the visual cells.

The **outer nuclear layer** and the **layer of rods and cones,** the remaining strata of the inner lamina of the retina, together constitute the **neuro-epithelium.** Since the rods and the cones and the outer nuclear layer are parts of a **single** lamina of tall **neuro-epithelial elements,** the **visual cells,** of which they are respectively the outer and inner segments, these strata must be regarded as subdivisions of the **one broad zone,** and not as independent retinal layers. The **outer** and **inner segments** are sharply separated by the intervening **membrana limitans,** through the openings in which the rods and the cones protrude. The constituents of the **neuro-epithelium** are, therefore, the **rod-visual cells** and the **cone-visual cells,** supported by the sustentacular tissue.

The **rod-visual cells** are composed of **two parts,** the one situated **without the limitans,** including the non-nucleated and highly-specialized segments, the **rods,** and the other **within the limitans,** consisting of slender varicose elements, the **rod-fibres,** provided with fusiform enlargements, the **rod-spherules,** which contain the **nuclei** of the visual cells. The **rods** are slender cylindrical structures, about 60 μ in length and 2 μ in breadth, composed of **two** chemically and optically **distinct parts,** the **outer** and **inner segments.**

The **outer segments** of the rods are cylindrical, apparently homogeneous, highly-refracting bodies, which, after certain reagents, exhibit a disposition to break up into thin **transverse disks.** The outer segments of the rods are further distinguished as being the **exclusive seat** of the peculiar **visual purple** or **rhodopsin.** The **inner segments** of the rods are slightly broader and less regularly cylindrical, and present a finely granular appearance, the parts of the segments nearest the membrana limitans possessing a peripheral **longitudinal striation.**

The **inner segments of the rod-visual cells** include the **rod-fibres** and their nucleated expansions, the **rod-granules.** The **rod-fibres** are slender, greatly extended, and often varicose, and reach from the membrana limitans into the external zone of the outer reticular layer. Each rod-fibre represents the greatly **attenuated protoplasmic body** of a visual cell, the situation of whose **nucleus** is indicated by the ellipsoidal enlargement. These enlargements, the **rod-granules,** vary in position, sometimes lying near the outer end, at other times close to the middle or the inner extremity of the fibres. The **granules** are almost entirely occupied by the **nuclei** of the visual cells, which are covered by an extremely thin layer of the cell-protoplasm. The nuclei of the cells are oval in form, about 6 μ in length, and characterized by a remarkable differentiation of their substance into **lighter** and **darker transverse bands.**

The **cone-visual cells** consist also of two parts, the outer divisions, the **cones,** situated beyond the membrana limitans, and the inner portions including the **cone-fibres** and their nucleated **cone-granules.** The **cones,** like the rods, present **inner** and **outer segments,** which in physical and chemical properties resemble the corresponding parts of the rods; the cones, however, are little more than half (32–36 μ) the length of the rods.

The **inner segments** of the cones are much wider than their outer divisions, and appear as **truncated conical bodies** whose sides are not absolutely straight, but slightly convex. The outer part of these segments is occupied by an **ellipsoidal group** of fine longitudinal **fibrillæ, the fibre-body,** which corresponds with the similar structure sometimes present within the rods.

The **inner segments of the cone-visual cells,** representing the **bodies** of the elongated cells, include the **cone-fibres** and their **granules.** The cone-fibres differ from the rod-fibres in being broader at the inner ends and more regular in their general contour; the cone-granules always lie, except in the macular region, next the membrana limitans.

The **distribution** of the two kinds of **visual cells** varies in the different retinal regions; the arrangement prevailing throughout the greater part of the retina is such that the adjacent cones are separated by three or four rods, the latter far outnumbering the cones. On approaching the **macula** the **number of cones increases,** the cones being so closely placed that they are separated by only a single row of rods; within the **fovea** itself the **rods entirely disappear,** the entire percipient layer being composed of **cones alone.** On the other hand, towards the **periphery** the number of these visual cells diminishes, and at the **ora serrata** the **cones** are **widely separated,** while the relative number of rods is very large. The

conclusion inferable from the distribution of these elements in the human retina, that the cones are the essential perceptive instruments, is not applicable as a generalization, since in many of the lower animals the cones are in the minority or even entirely wanting (hedgehog, shark, sturgeon), and the rods predominate; it seems, however, probable that the highest acuity of vision requires the presence of cones. The entire **number of cones** in the human retina has been computed at something over three and one-half millions (Salzer), while the **rods** are supposed to aggregate one hundred and thirty millions.

The **pigment-layer** represents the **outer lamina** of the embryonal optic vesicle, and consists of a single layer of **polyhedral epithelial cells** containing pigment-granules in varying amount. These cells (12–18 μ) are usually six-sided, but may have fewer or more borders; the cells in the vicinity of the ora serrata are of exceptionally large size and dark color. The elements of the pigment-layer exhibit a differentiation into an **outer zone** next the choroid, **free from pigment** and containing an oval **nucleus**, and an **inner zone loaded** with **pigment-granules.**

The **inner part** of the pigment-cells includes **protoplasmic processes** directed towards the layer of neuro-epithelium, **between the rods** and **the cones** of which they extend for a variable distance; the depth to which the pigment-granules penetrate along the processes between the cells depends upon the **influence of light**, since under strong illumination the granules wander along the protoplasmic processes as far as the inner segment of the rods and the cones, while in eyes kept in the dark for some time before death the intercellular processes remain uninvaded.

The structural details above described represent the construction of the retina throughout the greater part of its extent: two regions, however, present such **marked variations** from the typical arrangement as to call for brief special mention; these are the macula lutea and the ora serrata.

The **macula lutea** and the contained **fovea centralis** correspond to the posterior pole of the **visual axis**, and are distinguished physiologically by the **acuity of vision**, which here attains its highest degree. The **macula lutea** is characterized, in addition to its yellow color, by a distinct **thickening** of certain of the retinal layers and by the **absence** of the **rod-visual cells** within its area. The **distinctive color** of the macula depends upon the presence of **diffuse yellowish pigment** within the layers internal to the visual cells, the latter elements remaining colorless; in consequence of this arrangement the **fovea**, in which the neuro-epithelium alone exists, is **devoid of pigment**, and therefore appears as a light spot within the colored area.

The **increased thickness** of the retina at the **macular margin** depends almost entirely upon the **extraordinary development** of the layer of **ganglion-cells**, which progresses until a stratum from seven to nine cells deep replaces the usual single row.

The **fovea**, on the other hand, is produced by the hollowing out of the centre of the macula consequent upon the gradual thinning, to almost suspension, of the **retinal layers lying internal** to the

FIG. 378.

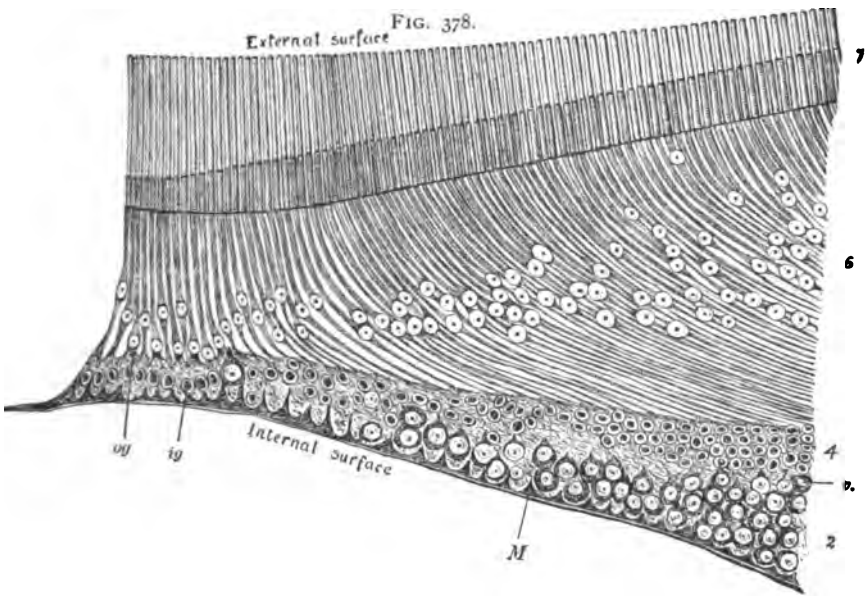

Diagrammatic section of the human fovea. Magnified 375 diameters. (Golding-Bird and Schäfer.)—2, ganglion layer; 4, inner nuclear layer; 6, outer nuclear layer, the cone-fibres forming the so-called external fibrous layer of Henle; 7, cones; *v*, section of a blood-vessel; *M*, membrana limitans externa; *og*, *ig*, outer and inner granules (cone-nuclei and bipolars) at the centre.

outer nuclear zone; the centre of the foveal depression, the **fundus foveæ**, consists chiefly of the **neuro-epithelium.** Within a central area the fovea is devoid of blood-vessels.

The **ora serrata** marks the **termination** of the **optical part** of the retina and the transition into its anterior continuations, the **pars ciliaris** and the **pars iridica.** The ora is distinguished, in addition to its irregular serrated border, by the **abrupt diminution** in the thickness of the retina, brought about by the sudden termination at this point of many of its layers. The regular diminution in the retinal thickness proceeds gradually from the fundus towards the periphery, when, on reaching a point near the ora serrata, many layers end abruptly, the ciliary continuation measuring only about one-third of the thickness of the adjacent retina.

The nerve-fibre and the ganglion-cell layer having already ended before reaching the ora, the sudden **reduction** is caused principally by the **abrupt termination** of the **two reticular strata.** The

FIG. 379.

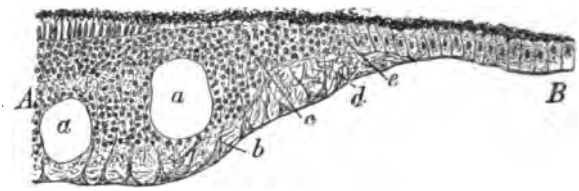

Section of human retina through ora serrata: *A*, *B*, visual and ciliary portion of retina; *a*, vacuoles; *b*, robust fibres of Müller; *c*, remains of nuclear layers; *d*, termination of supporting fibres; *e*, transformation of inner nuclear layer into columnar cells within continuation of pigment-layer.

region of the ora serrata is also noteworthy on account of the **remarkable development** of the **radial fibres of Müller,** which here occur not only in unusual numbers but also of exceptional strength.

Beyond the ora serrata the retinal laminæ are continued as the **pars ciliaris** and the **pars iridica retinæ.** These prolongations consist of an **outer** and an **inner lamina.** The **outer layer** is the direct and only slightly modified **extension of the retinal pigment**; the **inner lamina,** the attenuated representative of the remaining retinal layers, consists of a single row of **slender columnar cells,** which originate at the ora by the transformation of the elements of the **inner nuclear layer.** A delicate **cuticle,** the **limitans interna,** extends over the **posterior surface** of both the **ciliary body** and the **iris**; this membrane is a **true cuticular formation,** and begins at the ora as a **new structure** not present within the optical part of the retina.

THE OPTIC NERVE.

The **optic nerve** corresponds to a highly-developed **single funiculus,** enveloped by stout connective-tissue sheaths, which are prolongations of the brain-membranes. **Externally** the optic nerve is invested by a robust fibrous membrane, the **dural sheath,** derived directly from the dura; this covering extends the entire length of the nerve, and on the entrance of the latter into the eyeball **becomes continuous** with the outer part of the **sclera.** The **surface** of the optic nerve is closely invested with the **pial sheath,** an extension of the pia, while between the latter and the dural covering lies a delicate partition from the **arachnoid,** constituting the **arachnoidean sheath.** The **clefts** included between these sheaths con-

stitute the **subdural** and the **subarachnoidean lymph-spaces** of the optic nerve, which communicate with the corresponding intercranial cavities.

On reaching the eyeball the tissue of the **dural sheath** passes uninterruptedly into the **outer** two-thirds of the **sclera**; the greater part of the **pial sheath** blends with the **inner** third of the **sclera**, some of its fibres, however, joining the **choroid.** The **arachnoidean sheath** unites with the **dural,** in consequence of which arrangement the subdural and subarachnoidal spaces become continuous at their ocular extremities.

FIG. 380.

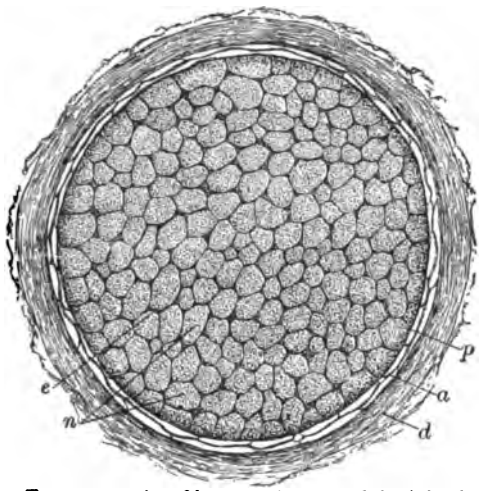

Transverse section of human optic nerve: *d*, dural sheath: *a*, arachnoidean sheath; *p*, pial sheath; *n*, bundles of nerve-fibres separated by fibrous septa (*e*).

The **trunk of the optic nerve,** about 3 mm. in diameter, consists of a great number (almost 800) of **bundles of medullated nerve-fibres** separated by intervening **fibrous partitions,** offshoots from the pial sheath. **Each bundle** is composed of small **medullated fibres** (2 μ), which are **without neurilemma.**

FIG. 381.

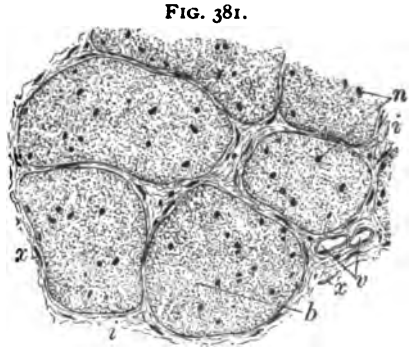

Section of human optic nerve under higher magnification: *b*, bundles of nerve-fibres enveloped in connective-tissue sheaths (*x*); *n*, neuroglia nuclei; *x*, nuclei of interfascicular connective tissue (*i*); *v*, blood-vessels.

On reaching a level corresponding with the confluence of the sheaths of the nerve with the sclera, the optic fibres pass through the sieve-like **lamina cribrosa** and **lose** their **medullary coat,** continuing to their retinal distribution as **naked axis-cylinders.** Occasionally the medullated fibres retain their **medullary substance** after their passage through the lamina cribrosa, such conditions presenting very striking ophthalmoscopic appearances.

The **lamina cribrosa** consists of five to eight lamellæ, composed of **transversely extending fibrous trabeculæ,** the direct prolongations of the scleral tissue. These bands bridge across what otherwise would be a canal, and unite in such manner that the openings occupied by the nerve-bundles present less area than the intervening fibrous tissue. The **fibrous lamellæ,** additionally connected with one another by vertical bands, pass from the margins of the scleral ring to the connective tissue supporting the blood-vessels within the optic nerve. The lamina cribrosa marks the **narrowest diameter** of the **optic nerve,** the loss of the medullary substance, together with the decrease in the neuroglia, reducing the size of the nerve about one-half. On arriving at the margin of the **optic papilla,** the bundles of nerve-fibres bend over its edges, constituting a thick layer, which rapidly thins away during its radial distribution over the retinal area.

FIG. 382.

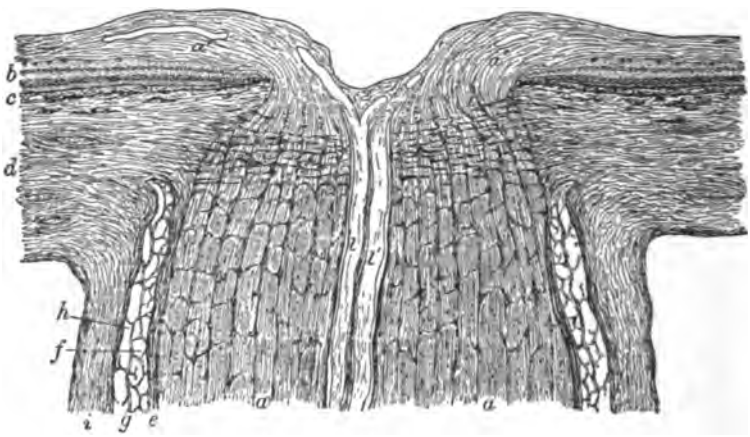

Longitudinal section through optic entrance of human eye: *a*, *a*, bundles of optic fibres, which spread over retina at *a'*, *a'*; *b*, layers of retina terminating at edge of optic papilla; *c*, choroid; *d*, sclera, continued across optic nerve as lamina cribrosa; *e*, *g*, *i*, respectively pial, arachnoidean, and dural sheaths, including subdural and subarachnoidean lymph-spaces; *l*, *l'*, retinal vessels cut longitudinally.

The centre of the optic papilla not infrequently presents a **funnel-shaped depression,** at the bottom of which the retinal vessels enter; this depression, variable in size and form, but always retaining **sloping walls,** is known as the **physiological excavation,** as distinguished from those possessing the **vertical** or **overhanging** walls indicative of grave pathological change.

At some distance (15–20 mm.) from the eyeball the **retinal blood-vessels** pierce the exterior of the optic nerve to take up a **central**

position, surrounded by connective tissue, which they maintain until their final branching on the papilla.

The **blood-vessels** of the retina constitute an independent system composed of **end-arteries**; the only communication between the retinal and ciliary vessels is established within the sclera, **close to the optic nerve,** by means of minute scleral and choroidal branches. The **larger retinal vessels** are situated within the inner part of the **fibre-layer** and supply twigs to the **cerebral division alone,** the **epithelial portion** being **non-vascular** and deriving its nutrition from the adjacent **choriocapillaris.**

The **capillaries** are arranged as **two net-works,** an inner and an outer. The **inner net-work** lies within the **fibre-layer,** is wide-meshed and derived directly from the division of the retinal vessels; the **outer net-work,** situated within the **inner nuclear layer,** is dependent upon the former, since its capillaries are derived from the branches given off from the inner vascular reticulum. The retinal arteries and veins are surrounded by **adventitious sheaths,** the spaces included between these sheaths and the walls of the vessels constituting **perivascular lymph-clefts.**

THE CRYSTALLINE LENS.

The **crystalline lens** comprises two genetically distinct portions, the **lens-substance** and the **lens-capsule.**

The **lens-substance** consists of the **epithelium** of the lens and the **lens-fibres**—both epithelial structures directly derived from the invaginated ectoderm.

The **epithelium of the lens,** the representative of the anterior wall of the primary lens-vesicle, consists of a **single layer** of **low polyhedral cells,** about 20 μ in diameter, whose granular protoplasm contains an oval nucleus, also often vacuoles. These cells lie **immediately beneath** the **anterior capsule** and extend backward as far as the **equator,** at which point the epithelial cells are transformed into the **lens-fibres.** A thin **subcapsular stratum** of albuminous substance exists as a connecting medium between the epithelium and the capsule, the same substance being continued between the posterior lens-capsule and the lens-fibres behind. Beneath the epithelium a **subepithelial stratum** of somewhat similar albuminous substance unites the epithelium and the lens-fibres and occupies the cleft representing the **remains** of the **original cavity** of the **lens-vesicle**; sometimes a few drops of fluid—the **liquor Morgagni**—occupy this subepithelial stratum.

The **lens-fibres** are greatly elongated **modified epithelial cells,** whose ancestors constituted the posterior wall of the lens-sac, but whose more recently formed fellows result from the transforma-

tion of the peripherally situated anterior epithelium at the equator. They are elongated **compressed six-sided prisms** varying in size with their position; those at the periphery of the lens are the largest (12 mm. in length by 10–12 μ in breadth), their size decreasing towards the centre. In the young lens all the fibres contain **oval nuclei**, but in the adult organ only those recently formed lying in the vicinity of the equator possess these. The fibres constituting the softer **cortical zone** have **smooth straight contours**, while those of the **central part** display a **finely-serrated outline** and are without nuclei. The lens-fibres are united by albuminous **cement-substance**, which, after suitable maceration, is dissolved, so that the fibres may be readily isolated; since the amount of the cement-substance is less between the broader than between the narrow surfaces of the fibres, after suitable maceration the lens evinces a disposition to separate into **concentric lamellæ**, somewhat after the fashion of an onion. The apposition of the ends of the fibres takes place along definite lines which appear on the anterior and posterior surfaces of the lens as **stellate figures**, the **lens-stars**. In the simpler conditions of the new-born child, as well as in most mammalia, each star consists of **three rays**, one of which in the **anterior star** is directed upward, while the others are disposed at an angle of 120° down and outward; in the **posterior star** the rays form an angle of 60° with those of the anterior surface, so that the figures of both surfaces

FIG. 383.

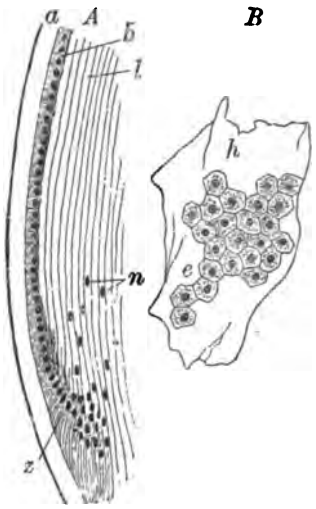

Portions of human crystalline lens: *A*, section through periphery at equator; *a*, anterior capsule; *b*, anterior epithelium converted into lens-fibres (*l*) at equator (*z*); *n*, nuclei of young lens-fibres. *B*, fragment of anterior capsule with adherent epithelium, viewed from under surface; *h*, capsule; *e*, epithelial cells.

FIG. 384.

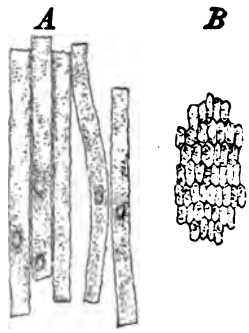

Fibres of human crystalline lens: *A*, portions of young isolated fibres; *B*, fibres in transverse section.

together constitute a **six-rayed star.** In the adult lens, however, the typical arrangement of the rays is greatly complicated by the addition of secondary lines which obscure the figures.

The **capsule** of the lens is a strong transparent **elastic membrane** completely enclosing the lens and, at the periphery, intimately uniting with the suspensory fibres of the **zone of Zinn.** The **anterior capsule** covering the front lens-surface is thicker (11–15 μ) than the corresponding **posterior capsule** (5–7 μ), the maximum thickness being at the centre of the anterior lens-surface and the minimum at its posterior pole.

The **zone of Zinn, zonula ciliaris,** or **suspensory ligament of the lens,** is the radially plicated, modified anterior continuation of the **hyaloid membrane** of the vitreous body. At the ora serrata the hyaloid becomes intimately united to the posterior surface of the ciliary body as far as the ciliary processes, from whose sum-

FIG. 385.

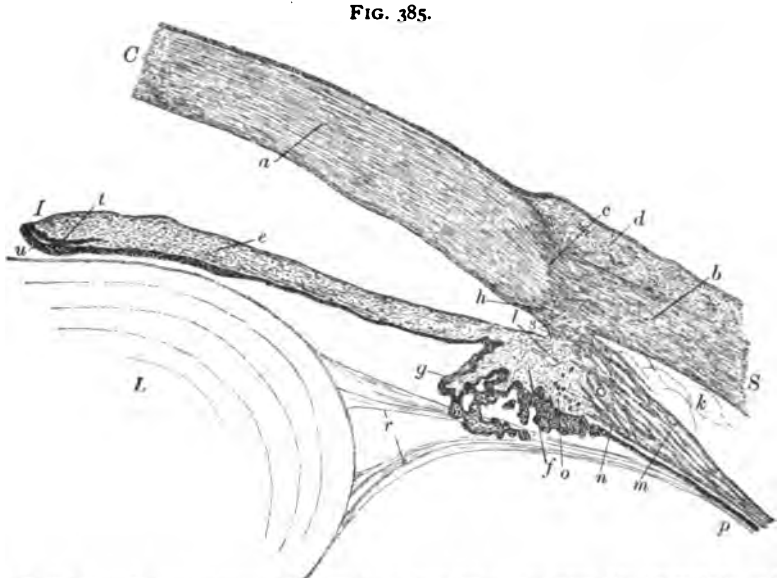

Section through anterior segment of human eye, including cornea, sclera, iris, ciliary body, and lens: *a*, *b*, substantia propria of cornea (*C*) and of sclera (*S*); *c*, sclero-corneal juncture; *d*, conjunctival tissue; *e*, stroma of iris (*I*); *f*, connective tissue of ciliary processes (*g*); *h*, canal of Schlemm; *k*, trabeculæ connecting sclera and ciliary body; *l*, section of blood-vessel; *m*, *n*, *o*, meridional, radial, and circular fibres of ciliary muscle; *p*, continuation of hyaloid membrane into ligament (*r*) of lens (*L*); *s*, spaces of Fontana; *i*, muscular tissue of pupillary sphincter; *u*, pigment-layer marking termination of retinal layers at pupil.

mits thickened bands bridge across the intervening space and become attached principally to the anterior surface and to the periphery of the lens. Owing to the plication of the ciliary body over which the

hyaloid is reflected, its surface is marked by **radiating folds**, which at the edge of the ciliary processes become converted into the **stiff fibres** distinguishing the free part of the zonula. These fibres form **two series**, the one comprising the fibres springing from the **summit** of the ciliary processes, the other consisting of those fibres which take their origin in the **depressions** between the ciliary processes; the fibres extending **from the valleys** pass to the **anterior surface** of the lens, where they blend with the outer lamella of the anterior capsule, while those springing **from the summits** of the processes are inserted into the **periphery** and the immediately **adjoining** parts of the **posterior capsule.**

The narrow **annular cleft**, triangular in section, bounded in front by the zone of Zinn, mesially by the lens, and behind by the membrane of the vitreous body, constitutes the **canal of Petit.** Owing to the constrictions produced by the shorter bridging fibres, the canal presents a **series** of **alternate constrictions** and **dilatations**, which, on inflation, map out the position of the canal by a ring of bead-like enlargements.

THE VITREOUS BODY.

The **vitreous body** occupies the space between the lens in front and the retina behind; it consists of the **vitreous substance** enclosed by the glassy **hyaloid membrane**, which in front, where it supports the lens within the **patellar fossa** on its anterior surface, comes in direct contact with the posterior capsule.

The **substance of the vitreous body** is remarkable, in addition to its beautiful transparency, for its great fluidity, consisting of 98.6 per cent. of water, the remaining small portion being made up of solids, including its organized parts. Histologically, the adult vitreous substance corresponds to **connective tissue** containing an enormous **watery infiltration** whose fixed elements have undergone degeneration. In its **embryonal** condition the vitreous body is composed of delicate **gelatinous** or **mucoid mesodermic tissue** containing numerous frail **stellate cells.**

The **formed elements** of the vitreous are of two kinds, **fibres** and **cells.** The **fibrous elements** occur in the superficial part of the vitreous, in the vicinity of the ora serrata, as fibrillæ of extreme delicacy, which take part in the formation of the **zone of Zinn.** Other fibrous structures are present as the **remains** of the minute blood-vessels permeating the vitreous in its embryonal condition.

The **cells** of the vitreous body belong to the category of **wandering corpuscles** or **leucocytes**, the fixed connective-tissue cells being wanting in the matured organ.

In the central part of the vitreous body, the **central** or **hyaloid**

canal extends from the optic papilla to the vicinity of the posterior lens-capsule; during fœtal life it transmits the **hyaloid artery**, and afterwards contains the remains of the supporting connective tissue, and, rarely, the atrophic artery itself. The canal is defined by a thin **membranous wall**, the continuation of the hyaloid membrane. The existence of other additional **small lymphatic spaces** has been demonstrated within the **periphery** of the vitreous body.

The minute arrangement and ultimate distribution of the blood-vessels in the various parts of the eye have already been described in connection with the individual structures; it here remains to outline briefly the general relations of the larger trunks.

The **blood-vessels of the eyeball** belong to two distinct systems, the **retinal** and the **ciliary**, which are connected by meagre anastomoses **only around the optic nerve entrance**, otherwise they remain entirely separate.

The **retinal system** is formed by the ramifications of the retinal artery and vein, which constitute the **permanent circulation** within the nervous layer. During fœtal life an additional **transient supply**, represented by the hyaloid artery, is distributed to embryonal structures which disappear before birth.

The **ciliary system** consists of the ramifications of the short, the long, and the anterior ciliary arteries and their complementary veins, and furnishes the blood-supply to the bulbar conjunctiva, the sclera, the choroid, the ciliary body, and the iris, and indirectly aids in maintaining the nutrition of the cornea, the lens, and the epithelial division of the retina.

The **short ciliary arteries** supply principally the choroid, and form the choriocapillaris, at the same time giving off twigs, before piercing the sclerotic coat, to the posterior segment of the sclera and to the dural sheath of the optic nerve. The **long ciliary arteries** pierce the sclera and pass in the horizontal meridian between the scleral and choroid coats as far forward as the ciliary body, in which they form the **larger arterial circle** of the iris; additional recurrent twigs are given off to the choroid and the ciliary muscle. The larger arterial circle sends branches to the ciliary processes and to the iris, as well as a few twigs to the choroid.

The **anterior ciliary arteries** pass to the anterior segment of the ball, and pierce the sclera near the corneal margin to gain access to the ciliary muscle behind the canal of Schlemm. Before entering the eyeball they send branches to the anterior segment of the sclera, to the scleral conjunctiva, and to the corneal limbus. From the branches which pierce the eyeball twigs communicate with the larger arterial circle of the iris, and supply the ciliary muscle and the fore part of the choroid.

The **venous vessels** of the eyeball culminate in two principal sets, the **posterior** and **anterior ciliary veins.** The former, or the **venæ vorticosæ,** collect the blood from the iris, the ciliary processes, part of the ciliary muscle, and the choroid, and on emerging from the sclera receive also the episcleral veins; they, therefore, drain the entire territory supplied by the ciliary arteries, except a part of the region nourished by the anterior ciliary arteries.

The **lymphatics** of the eyeball constitute the **anterior** and **posterior lymph-tracts,** which do not comprise definite lymphatic vessels, but a series of intercommunicating lymph-spaces varying in size from the microscopic tissue-spaces to the anterior chamber.

The **anterior lymph-tract** includes:

1. The systems of the **lymph-spaces** within the **cornea** and the **sclera.**

2. The **anterior chamber** of the eye, containing the aqueous humor, which possesses in small number the usual histological elements of lymphatic fluid, the leucocytes. The anterior chamber communicates with the posterior chamber through the cleft between the iris and the lens, and indirectly, by means of the spaces of Fontana, with the canal of Schlemm.

3. The **canal of Petit,** connected by means of the interfascicular clefts with the posterior chamber, and thus indirectly with the anterior, these three spaces standing in close relation.

The **posterior lymph-tract** includes two groups, the lymphatics of the **retina** and of the **vitreous body** and those of the **perichoroidal space.**

The constituents of the first group are:

1. The **hyaloid canal** of the vitreous, which empties into the lymph-clefts of the optic nerve.

2. The **perivascular lymph-channels** surrounding the retinal vessels, which likewise pour their contents into the lymph-spaces of the nerve.

3. The **lymph-clefts of the optic nerve,** terminating within the subarachnoidean space of its sheaths.

The **perichoroidal space,** lying between the scleral and the choroid coat, drains the choroid and communicates with the sac enclosed by Tenon's capsule; the **perivascular lymphatics** surrounding the **venæ vorticosæ** lead from the perichoroidal cleft into Tenon's space, from which channels connect with the **supra-vaginal** space, embracing the optic nerve; finally, communications exist between this space and the great intercranial lymphatic cavities. Connections between the lymph-clefts of the optic nerve and the perichoroidal space probably also exist in the vicinity of the optic entrance.

The **nervous supply** of the several parts of the eye has already been considered in detail; it remains to add a short description of their general relations.

The **long** and **short ciliary nerves** pierce the sclerotic coat in the vicinity of the optic nerve and pass between the sclera and the choroid, giving off branches for the supply of the latter, and unite to form the **ciliary ganglionic plexus** on the outer part of the ciliary body. From this plexus twigs pass to the tissues of the ciliary muscle, the iris, and the cornea, to be distributed in the manner already described.

THE APPENDAGES OF THE EYE.

THE EYELIDS.

The **eyelids** are protecting folds which include between their tegumental and mucous surfaces connective tissue, muscular and glandular structures. The constituents of the eyelids are arranged as general layers from without inward, these being: (1) the **integument** and **subcutaneous tissue,** (2) the **muscular layer,** (3) the **median connective tissue,** (4) the **tarsal plate,** and (5) the **conjunctiva.**

The **skin** covering the external surface of the eyelid is thin, thrown into folds, and beset with fine hairs and small sweat-glands; the **corium** possesses slightly-developed papillæ, except at the edge of the lid, where the fibrous tissue is denser and displays more conspicuous elevations. The constant occurrence of **pigment-cells** within the corium is a noteworthy peculiarity.

The loose **subcutaneous tissue** is rich in elastic fibres, but **fat** is **wanting,** or, if present, is found only in meagre amount. At the outer border of the margin of the lid large stiff hairs, the **cilia,** extend obliquely outward; they are arranged as two or three rows, their hair-follicles extending deeply into the corium and being supplied with small sebaceous glands. The life of the cilia is short, being about **four months** in duration; as a result, hairs in all stages of growth are usually included among the eyelashes.

The **muscular bundles** of the orbicularis palpebrarum constitute the layer next the subcutaneous tissue. At the lower margin of the lid the muscle-bundles are divided by the outer structures occupying this region; an especially robust bundle separated by the lashes lies near the posterior margin of the lid-edge and constitutes the **ciliary** or **marginal muscle** of the lid.

The succeeding **connective-tissue layer** is composed largely of the fibrous extensions of the **tendon of the levator palpebræ,** which are partly inserted into the areolar tissue—**fascia palpe-**

bralis—and partly attached to the upper edge of the tarsus; the tarsal portion contains bundles of **non-striped muscle**, which collectively form the **lid-muscle of Müller.**

The **tarsus** consists of a semilunar plate of **dense fibrous tissue**

FIG. 386.

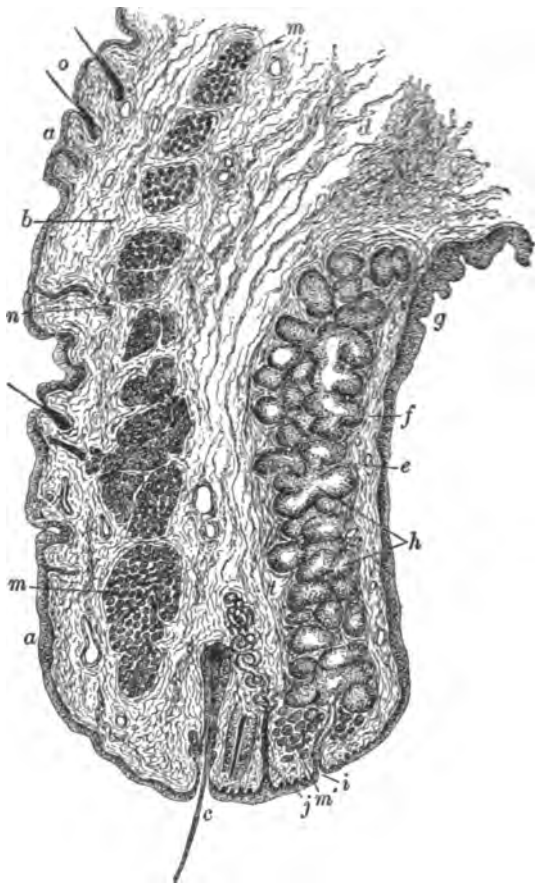

Section of human eyelid: *a*, *a*, skin; *b*, subcutaneous tissue; *c*, cilium; *d*, median connective tissue; *e*, tarsal plate containing Meibomian glands (*h*); *f*, tunica propria of conjunctiva covered by its epithelium (*g*); *i*, duct of Meibomian glands; *j*, Moll's glands; *m*, *m*, cut fibres of orbicular muscle; *m'*, marginal bundle of same; *n*, sections of sweat-glands; *o*, hairs; *t*, anterior boundary of tarsus.

lying immediately in front of the conjunctiva, and extending as a firm but elastic lamina from the sharply-defined palpebral border deeply into the substance of the lid. The tarsus is composed of **closely-felted bundles** of dense **fibrous tissue**, whose tough

resistant mass gives form and support to the softer tissues of the lids and partly covers the Meibomian glands embedded within its substance.

The **Meibomian** or **tarsal glands** constitute a series of about thirty elongated **tubulo-acinous** structures **embedded** within the **substance of the tarsal plate,** nearer the anterior than the posterior surface. Each gland consists of a long **vertical duct,** whose general course is perpendicular to the margin of the lid; into this canal numerous short **lateral tubular acini** open. Since the extremities of the glands occupy the outer arched border of the tarsus, these structures are longest in the middle of the lid and progressively shorten towards either end. The **ducts** open on the straight palpebral border as a **row of minute orifices** situated parallel to, but at some little distance from, the sharply-defined inner palpebral border. In their histology the **Meibomian glands** so closely resemble the **sebaceous follicles** of the skin that they must be regarded as **modifications** of these structures; their secretion consists of a **fatty substance** similar to the sebum lubricating the integument. The ducts of these glands, about .1 mm. in diameter, are lined by an epithelium possessing the character of the surrounding epidermis, while the **acini** (.08–.15 mm.) contain several layers of **polyhedral cells,** most of which are in various stages of **fatty degeneration.** In the upper part of the tarsus, especially in the nasal half, **additional branched tubular glands** lie partially surrounded by the fibrous tissue; these structures correspond in composition to the tear-glands, and are known as the **accessory lachrymal glands.**

The **conjunctiva** constitutes the innermost layer and surface of the lid, being continuous at the base of the lid with the bulbar conjunctiva and at its palpebral border with the integument. The conjunctiva consists of the **epithelium** covering the free surface and the **connective-tissue matrix,** or **tunica propria.** The **epithelium** is less squamous in type and resembles **stratified columnar;** at the margin of the lid the columnar epithelium passes over into the squamous cells of the epidermis. The surface of the conjunctiva covering the tarsal plates is smooth, but beyond its epithelium forms **irregular pockets,** which in section somewhat resemble glands.

Numerous **lymphoid cells** within the reticulated tunica propria, in certain localities, strongly suggest the presence of **diffuse adenoid tissue;** the amount of such lymphoid tissue is subject to much individual variation; it is, however, usually best marked in the retrotarsal portions of the conjunctiva. **Circumscribed lymph-follicles** are occasionally observed, although these structures are less constant in man than in many of the lower animals—dog, cat, sheep, or ox.

Additional minute **lymphoid nodules** and **mucous glands** occur within the **conjunctival fornix.** The **ocular conjunctiva** presents changes in the vicinity of the transitional folds, where the **epithelium** loses its columnar character and assumes the **stratified squamous** type in its further extension.

The edge of the lid presents two borders, the **outer,** rounded off and tegumental in character, and the **inner,** distinguished by its sharply-defined margin and dense fibrous structure. In addition to the orifices of the Meibomian glands, the palpebral border is penetrated by the ducts of the **glands of Moll,** structures properly regarded as **modified sweat-glands.**

The vertical fold of conjunctiva occupying the inner canthus, the **plica semilunaris,** represents the third eyelid, or **membrana nictitans,** of the lower animals. In exceptional cases the base of the fold contains a minute plate of hyaline cartilage; a small **racemose gland,** the homologue of the Harderian gland, is also sometimes present at the base of the semilunar fold.

The **lachrymal caruncle** within the inner canthus is an isolated and modified **island of skin,** possessing an **epithelium,** a **corium,** and **subcutaneous tissue** similar to the adjacent integument; the epithelium, however, is without the stratum corneum. The caruncle contains **adipose tissue,** fine **hairs** with relatively large hair-follicles, and modified **sweat-glands** closely resembling the glands of Moll. A small amount of **involuntary muscle** usually exists in the caruncle, and sometimes a few additional fibres of **striped muscle.**

The **blood-vessels** of the eyelids pass from the outer and inner angles towards the centre of the lid, forming an arch, the **arcus tarseus,** along the edge of the lid, and a second anastomosis, the **arcus tarseus externus,** at the upper margin of the tarsal plate; from these arterial bows smaller twigs are given off, which, in addition to supplying the integument, the Meibomian glands, and the glands of Moll, form the conjunctival capillary net-work; additional branches pass to the fornix conjunctivæ and to the conjunctiva of the eyeball.

The **lymphatics** of the lid are arranged as **two sets**: the close-meshed **conjunctival net-work** within the tarsal mucous membrane, and the wide-meshed **peritarsal net-work** on the front of the tarsus at its upper border. The first set include the lymphatics running near the palpebral border, as well as the narrow channels surrounding the Meibomian glands. The conjunctival lymph-vessels communicate with the peritarsal net-work by means of the coarse reticulum within the tarsus surrounding its glands, as well as by direct connections established by the twigs which pierce the tarsus to join the net-work within the conjunctiva. The peritarsal lymphatics possess valves.

The **nerves** of the eyelids form the rich **marginal plexus** close to the palpebral border; the trunks taking part in the formation of this plexus before their union give off branches to the orbicular muscle and the skin, as well as additional twigs for the supply of the conjunctiva. From the plexus itself fibres are distributed to the hair-follicles of the cilia, the Meibomian glands, the tarsal conjunctiva, and the tissues of the edge of the lid. The ultimate nervous distribution includes the formation of subepithelial net-works of fine non-medullated fibres, together with the special endings, the spherical end-bulbs, occurring within the bulbar conjunctiva.

THE LACHRYMAL APPARATUS.

The lachrymal apparatus includes the **lachrymal gland** and the **system of canals** carrying off the fluid secreted under usual conditions.

The **lachrymal gland** represents the **serous racemose** type, closely resembling the **true salivary glands** in structure; the organ differs from the usual racemose gland in the **independent course** and the **number of its ducts,** of which about a dozen are usually present. It appears, therefore, more accurate to regard the lachrymal gland as a **group** of closely-placed small individual racemose glands rather than as a single organ.

The **ducts** of the lachrymal gland are lined by **simple columnar epithelium.** The structure of the **acini** and the relations of their groups correspond to those of the **serous salivary glands,** the **secreting cells** possessing similar spherical forms and granular protoplasm.

FIG. 387.

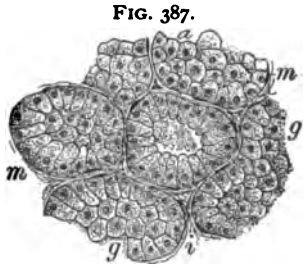

Section of human lachrymal gland: *a*, acini, limited by basement-membranes (*m*) and lined by secreting cells (*g*); *i*, interacinous connective tissue.

The **blood-vessels** of the lachrymal gland form the usual capillary net-works supplying the acini and their secreting cells.

The **nerves** distributed to the glandular tissue pass between the acini and form net-works beneath the basement-membrane; their ultimate relations to the secreting cells are uncertain.

The **lachrymal canals** or **canaliculi** consist of three coats—the **epithelium,** the **tunica propria,** and the **muscular tissue.** The **epithelium** is **stratified squamous,** and forms a layer about .12 mm. in thickness, in which the deepest cells are columnar and the superficial greatly flattened. The **tunica propria** is composed of bundles of fibrous tissue among which lie especially rich circularly-disposed **elastic net-works.** Outside the tunica propria the lachry-

mal canals are surrounded by a layer of **striped muscle** derived from that part of the orbicularis known as Horner's muscle; this tissue is arranged as small bundles, which possess a general **longitudinal course** parallel with the axis of the greater part of the lachrymal canals. The vertical **papillary division** of the tube, however, lies at right angles to the muscle-bundles, which, consequently, seem to enclose this part of the canal within circular or **sphincter fibres**; some of these occupy the edge of the lid and surround the **puncta** with muscular loops.

The **mucous membrane** of the **lachrymal sac** and of the **naso-lachrymal duct** is connected with the periosteum of the neighboring bony surfaces by loose areolar tissue, within which is lodged a rich **venous plexus.**

The **mucous membrane** of the lachrymal **sac** and of the **duct** partakes largely of the nature of **lymphoid tissue,** consisting of a connective-tissue **reticulum** infiltrated with **lymphoid cells.** From the tear-sac to the nasal termination of the duct the lining **epithelium** is **stratified columnar** in character, with the occasional presence of cilia within the lower part of the tube.

The eyeball is separated from the surrounding structures within the orbit by the intervention of a fibro-elastic membrane or fascia, the **capsule of Tenon,** covered by a continuous layer of **endothelial plates**; the enclosed **episcleral space,** or **space of Tenon,** communicates with the perichoroidal space on the one hand and with the supra-vaginal cleft on the other. In effect, the capsule of Tenon corresponds to a synovial sac, whose lubricated surfaces of contact facilitate the movements of the eyeball.

DEVELOPMENT OF THE EYE.

The earliest indication of the visual organ is the **optic vesicle,** a large diverticulum extending on either side from the primary anterior brain-vesicle, and later becoming connected by a constricted stalk with the **interbrain,** or **thalamencephalon.**

In the early stage the optic vesicle lies in contact with the ectoderm reflected over the prominently protruding optic diverticulum, the surrounding mesoderm at first showing no differentiation. Shortly after the optic vesicle has reached the surface ectoderm the latter exhibits proliferation and thickening opposite the external pole of the vesicle. This **ectodermic area,** the earliest trace of the future **crystalline lens,** soon becomes depressed, the invagination progressing until the pit- and the cup-stage give place to the closed vesicle, which finally separates from the ectoderm and lies beneath the surface as the **lens-sac.**

Simultaneously with the progress of these changes in the ectoderm,

the anterior segment of the **primary optic vesicle** undergoes an important **invagination**, whereby the front wall of the sac is pushed into the cavity of the vesicle until eventually the anterior and posterior walls are in apposition and the included cavity is largely obliterated. The new space within the indented anterior walls of the sac constitutes the **secondary optic vesicle** and corresponds to the later vitreous chamber. These important changes probably are not entirely attributable to the mechanical influence exerted by the developing lens-sac on the closely-applied optic vesicle, but must be referred also to deeply-lying formative forces.

FIG. 388.

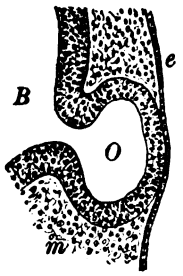

Section through head of ten-day rabbit embryo, exhibiting primary optic vesicle (*O*) protruding from fore-brain (*B*) and coming in contact with surface ectoderm (*e*): *m*, surrounding mesoderm.

FIG. 389.

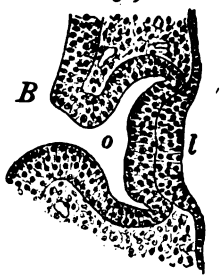

Section through developing eye of eleven-day rabbit embryo: *B*, fore-brain connected by stalk with optic vesicle (*o*), whose anterior wall is partly invaginated; *l*, thickened and depressed lens-area.

The **invagination** of the optic vesicle is not confined to the anterior pole, but takes place likewise along the **under side of the sac** as well as along the **optic stalk**; in consequence the vesicle is imperfectly closed below, the cleft, or **choroidal fissure**, thus established affording an entrance for the surrounding mesodermic tissue which takes part in the production of the primary vascular structures occupying the vitreous chamber. The relations of the parts to the fissure are well shown in frontal sections, where the cleft appears as a conspicuous break in the continuity of the walls of the vesicle.

FIG. 390.

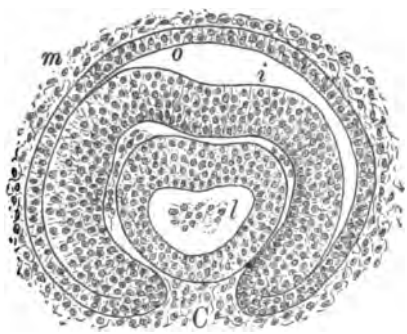

Sagittal section through developing eye of eleven-and-a-half day rabbit embryo, exhibiting choroidal fissure (*C*) through which mesodermic tissue (*m*) reaches interior of secondary optic cup: *o*, *i*, outer and inner layers of optic vesicle; *l*, lens-sac.

The Retina. The layers of the optic vesicle very soon exhibit marked difference in their rate of growth, since the anterior depressed lamina rapidly overshadows the posterior layer by its much greater thickness and more active proliferation. The **posterior wall** becomes reduced in thickness, owing to the increase in the size

of the sac, and later is distinguished by the appearance of deeply-pigmented granules, which mark the beginning of the **pigment-layer** of the retina, to the formation of which the posterior lamina of the optic vesicle is entirely devoted; the pigment is first seen in the vicinity of the lip of the cup, from which point the colored particles spread towards the posterior pole.

The invaginated **anterior lamina** becomes greatly thickened and differentiates into the remaining highly-specialized **layers of the retina.** The process by which these are formed corresponds in the main points with the differentiation of the nervous centres, the resulting tissues being of two kinds, the **supporting neuroglia** and the **nervous elements.**

The **retinal lamina** early presents a narrow **inner zone,** distinguished by its meagre nuclei as contrasted with the richly-nucleated broad **outer division;** this latter, next the pigmented lamina, with many strata of nuclei, differentiates into an **outer layer** characterized by **small,** deeply-staining nuclei, and an **inner layer** of **larger** elements. The **outer layer** subsequently divides into three strata, the **outer nuclear,** the **outer reticular,** and the **inner nuclear,** while the **inner layer** produces two zones, the **inner reticular** and the **ganglion-cell.**

The **rods** and **cones** appear later as minute hemispherical elevations on the outer surface of the external limiting membrane, and at first possess their **inner segments** alone, the outer members later growing out from the inner. At birth in many animals (as cats, rabbits, etc.) the rods and cones are wanting, and even in man they are rudimentary; the **macula** at birth is still undifferentiated.

The **nerve-fibres** of the retina are derived probably from **two sources,** from the neuroblasts of the **retina** itself and from those of the **interbrain.** The hollow optic stalk becomes solid and converted into the **primary optic nerve,** which acquires its nerve-fibres from the ingrowing and outgrowing processes of the retinal and the cerebral elements.

The **retinal blood-vessels** develop within mesodermic tissue, which spreads over the inner surface of the nervous layer at a comparatively late period; the vessels first appear around the optic nerve and spread peripherally. They are not connected primarily with the central vessels of the retina, but with branches entering at the periphery of the nerve (O. Schultze).

The **crystalline lens** proceeds from the **ectodermal vesicle** already noted. The walls of this sac very early exhibit marked variation in thickness, the **anterior lamina** being relatively thin and composed of a single layer of cuboidal cells, which persist as the flattened **polyhedral epithelium** of the **anterior lens-capsule.**

The **posterior wall** of the lens-sac plays the active *rôle* in the formation of the lens-substance, since the production of the lens-fibres is entirely due to the transformation of its greatly-elongated cells. After the obliteration of the original cavity of the sac has been completely effected by the apposition of the enormously-thickened posterior wall and the anterior lamella, the lens further increases in size by the addition of new fibres at the equator, where the metamorphosis of the epithelial elements into the lens-fibres is continually taking place.

FIG. 391.

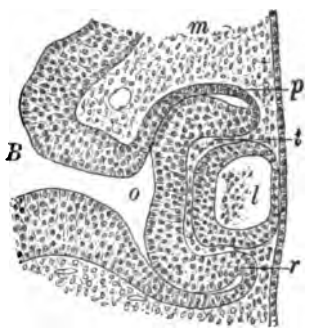

Section through developing eye of eleven-and-a-half-day rabbit embryo: *B*, fore-brain connected with optic vesicle (*o*) nearly effaced by apposition of invaginated anterior segment (*r*) with posterior wall (*p*); *l*, lens-sac, completely closed and separated from ectoderm; *t*, tissue within secondary optic cup derived from surrounding mesoderm (*m*).

The **anterior** and **posterior capsules** of the lens are genetically distinct from the lens-substance, since they are **mesoblastic** in origin; for a time they are closely associated with the transient lamellæ of vascular mesodermic tissue which invest the surfaces of the lens and constitute the **tunicæ vasculosæ.** The **development** of the **fibrous tunic**—the sclera and the cornea—proceeds from the surrounding **mesoderm,** which undergoes condensation immediately around the ectodermic structures representing the retina and the lens. The **mesodermic tissue** at the sides of the anterior segment grows between the epidermis and the lens, and constitutes a layer of considerable thickness; subsequently this sheet becomes unequally divided by the appearance of a cleft, the **primary anterior chamber,** into two laminæ of unequal thickness; of these the **anterior** and thicker becomes the **cornea** and the **posterior** and thinner the connective tissue of the **iris** and the transient **vascular tunic** of the lens.

The mesodermic **corneal stratum** undergoes specialization into the substantia propria, the anterior and posterior limiting membranes, and the endothelium, the anterior epithelium alone being ectodermic.

The **choroid** and the **iris** are closely associated in their origin with the mesodermic tract producing the fibrous tunic, the rich vascular net-works characterizing the choroid appearing relatively late. The iris does not grow forward until the anterior chamber begins to form, when it proceeds as a blunt continuation of the choroidal tract; while the **stroma** of the iris is contributed by the mesoderm, the **pigment-layer** is derived from the extension

of the rudimentary portions of the optic cup, whose double-layered lip corresponds in position with the pupillary margin.

The **vitreous humor** is derived from the mesodermic tissue occupying the interior of the optic cup. This tissue appears very early, in consequence of the **ingrowth** of the mesoderm through the choroidal fissure; the early vitreous possesses delicate branched cells as well as numerous blood-vessels, and corresponds to soft embryonal connective tissue; later the corpuscles and blood-vessels disappear and the mass assumes its characteristic semi-fluid almost structureless condition. The **peripheral zone** of the vitreous undergoes condensation and forms the **hyaloid membrane,** which in the ciliary region becomes thickened and constitutes the **suspensory ligament** of the lens, or the **zone of Zinn.**

FIG. 392.

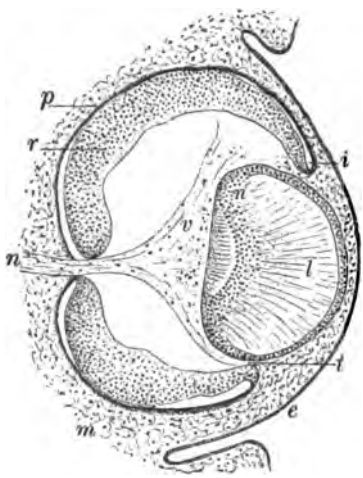

Section through developing eye of thirteen-day rabbit embryo: *e*, ectoderm; *l*, lens, consisting of anterior nucleated division representing thin front wall of lens-sac and greatly thickened posterior division, completely filling cavity of sac by elongated fibres whose nuclei present crescentic zone (*n*); *p*, posterior pigmented layer; *r*, specialized anterior retinal layer; *i*, point where layers of optic vesicle become continuous; *n*, extreme peripheral section of tissue of primitive optic nerve connected with vascular tunic (*v*) occupying posterior surface of lens; *m*, surrounding mesoderm, which at *t* grows between lens and retina.

The **eyelids** develop as folds of integument above and below the corneal area; these grow towards one another and finally **fuse,** all epidermal demarcation for a time disappearing. Shortly before birth the centre of the epithelial layer undergoes degeneration and the lids become permanently separated.

The **epithelium** of both the tegumentary and conjunctival surfaces is derived from the **ectoderm,** as are also such **epidermal appendages** as the hairs and the glands, the **Meibomian glands** corresponding to sebaceous follicles in their formation.

CHAPTER XVIII.

THE ORGAN OF HEARING.

THE complicated organ of hearing of man and the higher animals, reduced to its essential factors, consists of two parts,—the system of intercommunicating **epithelial tubes**, certain parts of whose walls are differentiated into special structures for the perception of the sound-waves, and the elaborate **conducting apparatus** for the transmission, direct and indirect, of the sound-impulses to the perceptive structures.

THE EXTERNAL EAR.

The **external ear**, including the **pinna** and the **external auditory canal**, possesses a **bony** or **cartilaginous basis** over which extend the **integument** and a layer of **subcutaneous tissue**. The **cartilage** is of the yellow, elastic variety, forming a thin, tough, yielding plate, displaying the various depressions and elevations seen on the outside; the lobule, however, contains no cartilage, but only tough fibrous tissue and fat.

The **skin** covering the pinna corresponds with the surrounding integument; within the auditory canal, however, it presents some change. The skin covering the **cartilaginous division** of the meatus, together with part of the roof of the bony division, is characterized by its **thickness**, the subcutaneous tissue also constituting a layer of considerable depth, which includes some fat and many bundles of dense fibrous tissue. Fine **hairs**, with relatively very large **sebaceous glands**, occur in all parts of this surface, as do also the **ceruminous glands**, which constitute conspicuous structures and closely correspond to the glands of Moll within the eyelid, being, like them, modified sweat-glands. Their long, narrow **ducts** during early life open with the sebaceous glands into the hair-follicles, but later acquire independent orifices. The **ceruminous glands** possess a well-marked basement-membrane, within which lies a single layer of **cuboidal epithelial cells**, with a thin, longitudinal stratum of **non-striped muscle-cells** interposed. The **secreting cells** contain numerous brown particles, but the presence of fat is questionable, the fatty constituents of the cerumen being probably contributed by the adjoining sebaceous glands. The coiled masses of the gland-tubes are situated within the subcutaneous tissue, where they sometimes reach as far as the cartilage or the bone.

The skin covering the greater part of the **bony canal,** on the contrary, is very thin and intimately united to the periosteum. **Hairs** and **glands** are **wanting** in this part of the canal, as they are also in the integument reflected over the external surface of the tympanic membrane.

FIG. 393.

Section of bony portion of human external auditory canal: *s*, cutaneous layer closely united with periosteal fibrous tissue; *o*, osseous tissue of wall. (After *Rüdinger*.)

The **membrana tympani** consists of three layers: (1) the central ground-stratum, or **lamina propria,** composed of fibrous connective tissue, (2) the **cutaneous layer** reflected over the external surface of the drum, and (3) the **mucous layer** covering the inner side of the membrane as the representative of the lining of the tympanic cavity.

The **tegumental layer** consists of the usual **epidermis** and connective-tissue **corium,** the latter being only about half as thick as the epithelial layer.

The central connective-tissue **ground-plate,** or **lamina propria,** constitutes the fibrous basis of the tympanic membrane and represents its mesodermic portion. This layer consists of closely-felted bundles of fibrous tissue arranged as two strata, the **outer** or **radial fibre-layer,** composed of fibrous bundles, which in their general course radiate from the periphery of the tympanum towards the point of attachment of the head of the malleus, and the **inner** or **circular fibre-layer,** consisting of concentrically-disposed bundles, whose greatest development is at the periphery in the vicinity of the annular attachment of the membrana tympani.

The **mucous layer** is a part of the general lining of the middle ear, and consists of a thin connective-tissue **tunica propria** or groundwork, composed of delicate bundles of fibro-elastic tissue, upon which rests the **epithelium**; the latter consists of a single layer of **low cuboidal polyhedral cells** without cilia.

The **blood-vessels** supplying the tympanic membrane are derived from **two sources,** the one set proceeding from the branches of the external auditory canal to end in capillaries which ramify within the

cutaneous layer, the other group coming from the vessels of the tympanic cavity to break up into the net-works distributed to the **mucous layer.**

The **lymphatics** of the tympanum correspond in their arrangement with the principal strata of the membrane. In the corium of the **skin-layer** lies a close net-work of capillary lymphatics; these increase in size towards the periphery, where they are collected into larger trunks, which in turn empty into the lymphatic channels of the

FIG. 394.

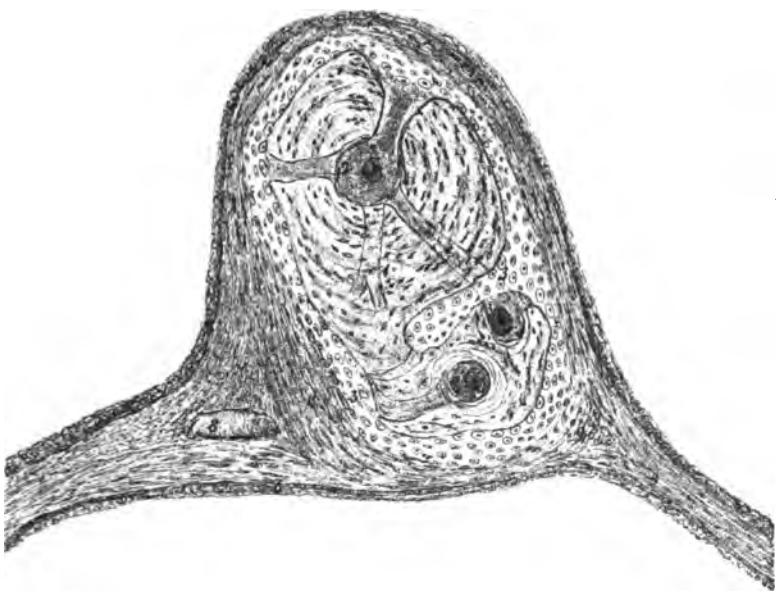

Section through human malleus and tympanic membrane: 1, bony tissue of manubrium, containing medullary canal (2); 3, hyaline cartilage of malleus; 4, 5, lamina propria of tympanic membrane attached to malleus; 6, cutaneous layer; 7, mucous membrane covering hammer; 8, blood-vessel; 9, fragment of fibro-cartilage. (After *Rüdinger*.)

external auditory canal. Within the **mucous stratum** a much less important lymphatic net-work exists, which communicates at the periphery with the lymphatics of the mucosa of the tympanic cavity. Suitable silver staining shows the existence of **lymph-spaces** in certain places, in both the fibrous layer and the mucous membrane.

The **nerves** of the membrana tympani follow the blood-vessels in their distribution so far that they also comprise **two sets** destined for the cutaneous and mucous layers. The nerves of the **cutaneous stratum,** chiefly derived from the tympanic branch of the auriculo-temporal, pass behind the manubrium of the malleus to divide at the

lower third of the process into two terminal twigs. In addition to these **central nerves,** small stems enter the drum-membrane at various points at the **periphery,** both sets of twigs taking part in the formation of a wide-meshed **ground-plexus.** From the latter fine pale fibres pass to the blood-vessels which they surround, while other fibres extend to the superficial part of the layer, where, beneath the epidermis, they constitute a **subepithelial plexus.** The nerves of the **mucous layer** originating in the tympanic plexus are largely distributed to the lymphatics as well as to blood-vessels; an additional **subepithelial plexus** bears close relations to the epithelium; a few fibres extend into the fibrous tissue of the lamina propria.

THE MIDDLE EAR.

The **middle ear,** the entodermic division of the auditory apparatus, comprises the **tympanic cavity,** with its extension into the **mastoid cells,** and the **Eustachian tube,** together with the series of minute **ear-ossicles.**

The **walls of the tympanic cavity** consist of the surrounding bony structures with their periosteum, over which is reflected the mucous lining, indirectly continuous with that of the pharynx. The **mucous membrane,** closely united with the underlying periosteum, not only covers the inner surface of the membrana tympani, but is also reflected over the ear-bones and their ligaments as well as over the nerves and blood-vessels crossing the cavity. The **mucosa** consists of a thin fibrous **tunica propria** (50–60 μ) which in places resembles the reticulum of adenoid tissue and includes leucocytes; the mucous layer is intimately blended with the denser fibrous structure of the periosteum. Connected with the trabeculæ of the mucosa **peculiar oval bodies** are occasionally encountered, which are composed of an axial band and concentric lamellæ of connective tissue; these bodies are normal but probably not constant constituents of the middle ear.

The **epithelial lining** (18–21 μ) of the tympanic cavity differs in character in the several regions; over the ear-ossicles, the tympanic membrane, and the promontory, as well as within the mastoid cells, the epithelium consists of a **single layer** of **low cuboidal polygonal cells without cilia**; over the remaining parts of the middle ear a layer of **ciliated columnar cells** exists. In those places where nerve-trunks or blood-vessels are covered, the greatly-thickened mucosa forms **local ridges,** within which the trunks are enclosed. Small **tubular glands,** about .1 mm. in length, occur in the mucous membrane of the **anterior part** of the tympanic cavity; they are sparingly distributed and subject to individual variation.

The mucous lining of the **antrum** and the **mastoid cells,** clothed

by a single layer of **low polyhedral cells,** is very thin and intimately united with the delicate periosteal layer; numerous fibres, trabeculæ, or lamellæ pass between neighboring surfaces and partially occlude the spaces within the bone, thereby reducing the lumina and still further adding to the complexity of the mastoid cells.

The **secondary tympanic membrane,** closing the fenestra rotunda, consists of three layers, a central fibrous **lamina propria,** which is covered on the tympanic surface by a reflection of the **mucous membrane,** and on the other side by the extension of the **lining** of the vestibular perilymphatic space. The **lamina propria,** the unossified part of the wall of the labyrinth, is composed of radially-disposed bundles of fibrous tissue passing from the indented point of its base towards the periphery. The **mucous stratum** is formed of a thin fibrous tunica propria invested by a single layer of **flattened non-ciliated polyhedral epithelial cells,** similar to those covering the neighboring promontorium. The **innermost stratum** of the membrane is composed of a thin layer of **subendothelial fibrous tissue,** over which extends the single layer of **endothelial plates.**

The larger **blood-vessels** supplying the mucous lining of the tympanum lie within the deeper periosteal layer of the mucosa and give off smaller branches, which pass superficially to form a capillary net-work beneath the epithelium. The vessels distributed to the mucosa covering the promontorium are remarkable for the **absence of anastomoses,** the arteries dividing into twigs possessing relatively large lumina; the terminal arterioles pass very rapidly into venous radicles, so that intervening capillaries scarcely exist, in places being entirely wanting.

The **lymphatics** of the tympanic mucous membrane form a system of channels within the deep periosteal layer, where the lymph-vessels are supplemented by spherical enlargements and lateral dilatations. The reticular connective tissue of the mucosa exhibits local **accumulations of lymphoid cells,** which strongly suggest the presence of lymphatic nodules.

The principal **nerves** of the tympanum, derived from the tympanic plexus, run within the periosteal layer of the mucosa, and are composed almost entirely of medullated fibres. From the deeper trunks fine twigs pass towards the surface and form a wide-meshed plexus, which contributes delicate bundles of pale non-medullated fibres to a **subepithelial net-work.** Along the course of the larger trunks and their immediate branches groups of **ganglion-cells** occur in exceptional cases, these being found in proximity with the epithelium.

The **ear-ossicles** consist of compact bone, in which Haversian

canals and concentric lamellæ are present in the thicker parts, as the head and the base of the short process of the malleus. All **surfaces of contact,** including the articular facets, are invested by **hyaline cartilage.** The cavity of the **ambo-malleal articulation** is subdivided by a minute intra-articular plate of fibrous cartilage. An investment of cartilage covers the **malleus** on all parts of the surface of its attachment to the tympanic membrane, the perichondrium becoming firmly united with the fibrous tissue of the lamina propria. The entire **base of the stapes** also is covered with a plate of cartilage directly applied to the **fenestra ovalis;** the space intervening between the stapes and the margin of the oval window is occupied by the ring of fibrous tissue constituting the **annular ligament.**

The **Eustachian tube** consists of two parts,—the **supporting framework,** composed partly of bone and partly of cartilage, and the **mucous membrane.** Neither the osseous nor the cartilaginous tissue of the canal constitutes a **complete wall,** since the tube is imperfect, being completed by the fibrous and other tissue which bridges the cleft left by the insufficient hard parts.

FIG. 395.

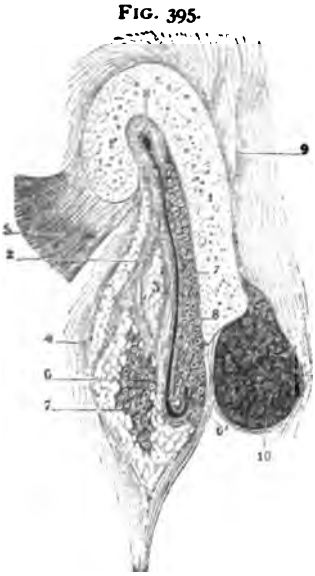

Section through cartilaginous portion of human Eustachian tube: 1, bent plate of cartilage with its hook (1'); 2, fibrous tissue with fat (3); 4, tubo-pharyngeal fascia; 5, dilator tubæ muscle; 6, mucous membrane of tube with prominent fold (6') below; 7, mucous glands; 8, lumen of tube expanding above into so-called safety-tube (8'); 9, connective tissue uniting tube with base of skull; 10, levator palati muscle. (After *Testut.*)

Within the canal formed by the osseous, cartilaginous, and fibrous tissues the soft tube of **mucous membrane** lies, its lower division supplemented by a stratum of **submucous tissue,** its upper part closely united with the periosteum of the bony walls.

The **epithelium** lining the Eustachian tube is **ciliated stratified columnar** in type, the cells clothing the pharyngeal division of the tube being **tall columnar elements,** while those lining the upper bony part are **low cuboidal,** although ciliated, and resemble the epithelium of the tympanum.

The **tunica propria** presents a stratum of loose connective tissue, rich in cells and defined from the submucous tissue by a denser layer; in many places the **reticular connective tissue** is infiltrated with **lymphoid cells** and constitutes an adenoid structure. The profusion and distribution of this **lymphoid**

tissue vary greatly with age; in early childhood it is present almost in all parts of the tube, but in adolescence it is plentiful only in the lower third, in the upper third being entirely wanting and in the middle third very sparingly distributed. Small **mucous glands** are also present, and open on the surface of the mucosa within the depressions between the longitudinal folds; these glands may exist throughout the length of the tube, but they occur with constancy only towards its **pharyngeal end.**

The **submucous layer** is well developed in the cartilaginous division of the tube, particularly in the outer membranous wall; it consists of loosely-arranged fibro-elastic tissue, which supports the mucous glands and the larger vessels and nerves, and often contains a considerable mass of fat.

The **blood-vessels** supplying the tubal mucous membranes are derived from the pharynx and from the tympanum; the larger longitudinal stems run within the submucosa or the deep periosteal layers and send twigs into the mucosa to form capillary net-works.

The **nerves** derived from the pharyngeal and tympanic plexuses occupy the deeper layers of the mucosa; the twigs given off from the larger trunks form a plexus within the superficial parts of the tunica propria, fine non-medullated fibrillæ passing to the epithelial structures; ganglion nerve-cells are found at the nodal points within the plexus.

THE INTERNAL EAR.

The **internal ear** in its fully-developed condition consists of two concentrically arranged parts, the **bony** and the **membranous labyrinth,** separated by an intervening space containing the **perilymph.**

THE SACCULE AND THE UTRICLE.

While the **bony labyrinth** in the cochlea and the semicircular canals quite closely repeats the general arrangement of the corresponding parts of the enclosed membranous tube, the central division of the osseous capsule, the **bony vestibule,** differs somewhat in its details from the enclosed membranous compartments.

These are two almost completely **separated vesicles** of unequal size, the anterior and smaller **sacculus** and the posterior and larger **utriculus;** the compartments communicate indirectly with each other by means of the **ductus endolymphaticus,** while the saccule connects additionally with the cochlear division of the membranous labyrinth through the narrow **canalis reuniens,** the utricle directly opening into the semicircular canals.

The **bony wall** of the vestibule is lined by a very thin **periosteum,** composed of a felt-work of resistant **fibrous tissue,** in which **pigmented connective-tissue cells** are not infrequent. From

this peripheral lamella **trabeculæ** extend across the intervening perilymphatic space to the fibrous wall of the membranous labyrinth. The **endothelium** of the inner surface of the periosteum invests the fibrous trabeculæ as well as the outer or perilymphatic surface of the membranous labyrinth.

The **walls** of the **saccule** and the **utricle** consist of the **connective-tissue lamella,** composed of the bundles of fibrous tissue and the delicate **epithelium.** At the positions where the filaments of the auditory nerve enter the **maculæ cribrosæ** and **acusticæ** the fibrous stratum is best developed and densest, forming a layer .15 to .20 mm. thick. Within other parts of the vestibule, especially in the roof of the utricle, the thickness of this layer may be reduced to 5–6 μ.

The **lining** of the **saccule** and the **utricle** consists everywhere, except at the maculæ acusticæ, of a single layer of thin **flattened polyhedral cells.** Over the regions receiving the terminations of

FIG. 396.

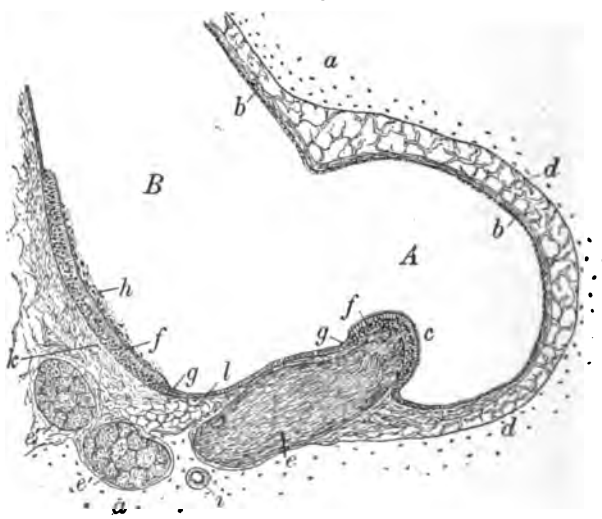

Section through membranous labyrinth of cat, showing specialized areas within ampulla (*A*) and utricle (*B*): *a*, surrounding bony wall separated from membranous tube (*b*) by layer of areolar trabeculæ (*d*); *c*, crista acustica covered with specialized epithelium (*f*); *e*, *e'*, bundles of nerve-fibres; *g*, ordinary epithelium; *h*, layer of otoliths overlying neuro-epithelium of matula acustica (*f*); *i*, blood-vessel; *k*, fibrous layer; *l*, adipose tissue.

the nerve-fibres, the **maculæ acusticæ,** on the contrary, the **epithelium** undergoes marked alteration, changing from the indifferent covering cells into the highly-specialized **neuro-epithelium.** At the margin of these areas the cells are at first cuboidal, then low

nar, and progressively increase in length until they measure
μ in contrast with their usual height of 3–4 μ.

character and arrangement of the cells of the acoustic areas
saccule and the utricle are the same, including **two kinds** of
ıts, the **sustentacular** or **fibre cells** and the **hair-cells.**

sustentacular cells are elongated irregularly cylindrical,
ctend the entire thickness of the epithelial layer to rest upon
ll-developed basement-membrane by their expanded or divided
processes. The oval **nuclei** are frequently wider than the
e diameter of the cells, and produce corresponding enlarge-
in the contour of the elements; the nuclei occupy various
within the inner half of the cells, but are never situated beyond;
ll-contents appear faintly granular, and contain **yellowish**
nt-particles.

hair-cells are broader but shorter than the sustentacular ele-
, and reach from the surface only to about the middle of the
lium, where they terminate in rounded margins; these cells
s large **spherical nuclei,** which usually lie well towards the
y-expanded inner ends. The **protoplasm** of the hair-cells is
ılar, and contains **yellow pigment;** the outer part, next the
ırface, exhibits a differentiation into a **cuticular zone,** cov-
he outer ends of the cells. From the free border of each cell a
ıgly **single stiff robust hair** (20–25 μ long) projects into the
mph; this conical process, how-
is **resolvable into a number**
lutinated finer hairs or rods.

FIG. 397.

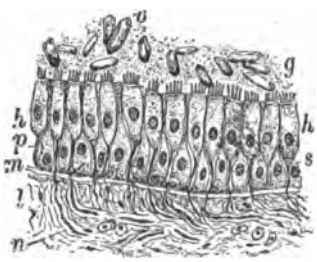

Section of wall of utricle through macular region, from rabbit, showing otoliths (*o*) embedded within granular substance (*g*): *h*, hair-cells with processes (*p*) extending between sustentacular elements (*s*); *n*, nerve-fibres within fibrous tissue (*l*) passing towards hair-cells and becoming non-medullated at basement-membrane (*m*).

free surface of the neuro-
lium within the **saccule** and
tricle is covered by a remark-
tructure, the so-called **otolith**
brane. This consists of num-
s small crystalline bodies, the
hs, or **ear-stones,** embedded
a soft gelatinous ground-sub-
. The **otoliths** are minute
ls of calcium carbonate, 1–15 μ
ıgth, usually six-sided prisms
slightly-rounded angles. The
-**fibres** proceed to the **acoustic**
and unite beneath the epithelial
in a **plexus,** from which fine
es of fibres pass towards the surface; the nerve-fibres usually
their **medullary substance** in their transit through the base-
membrane and enter the epithelium as **naked axis-cylinders.**

After ascending about half-way to the free surface the fibres break up into their **fibrillæ**, many of which are distributed to the **hair-cells**, with which they probably stand in close relation, while others pass as free axis-cylinders **between the epithelial elements** to a higher level.

The **blood-vessels** of the **saccule** and the **utricle** form a wide-meshed capillary net-work within the fibrous wall of the membranous sacs, the vascular supply being especially rich within the maculæ acusticæ.

THE SEMICIRCULAR CANALS.

The inner surface of the **bony capsule** constituting this part of the osseous labyrinth is lined by a thin **periosteum** similar to that of the vestibule already described. Along the line of attachment of the membranous canal this layer sends off numerous connecting bundles of fibrous tissue; in other parts of the circumference of the canal only widely-separated, occasional **trabeculæ** bridge across the perilymphatic space to aid in maintaining the position of the membranous tube. The **inner surface** of the periosteum, the trabeculæ, and the outer face of the fibrous tunic of the membranous canals are invested by the **endothelium** which forms the immediate lining of the **perilymphatic space.**

FIG. 398.

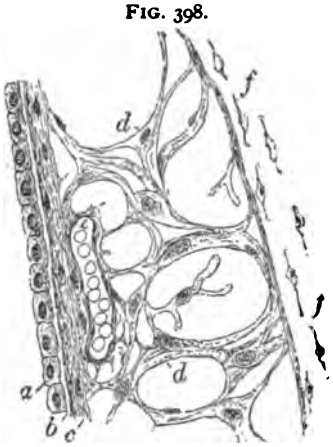

Section of wall of cat's semicircular canal: *a*, epithelial lining of canal; *b*, basement-membrane; *c*, fibrous tunic united with osseous lamella (*f*) by trabeculæ (*d*, *d*); *e*, blood-vessel.

The walls of the **membranous semicircular canals** closely resemble those of the saccule and the utricle, being made up of an outer **fibrous lamella** and an inner **epithelial lining.** The **fibrous coat** is further differentiated into an **external layer** of felted connective-tissue bundles, containing many cells, and an **inner,** more compact, almost homogeneous **layer,** which corresponds to a highly-developed **basement-membrane.**

The **epithelium** of the semicircular canals, supported by the outer fibrous coat, consists throughout the greater part of its extent of a **single layer** of **flattened polyhedral cells** (12–18 μ) similar to those lining the saccule and the utricle.

The areas receiving the terminal filaments of the auditory nerve, the **cristæ acusticæ,** are distinguished by **specialization of the**

epithelium to constitute the perceptive apparatus of the semicircular canals.

These specialized areas are limited to the **floor of the ampullæ, in** which position the fibrous wall of the canal is distinguished by a **local thickening** forming the **transverse ridge, or septum transversum.**

FIG. 399.

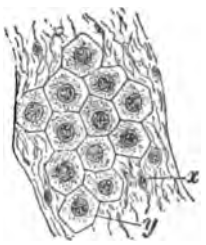

Surface view of membranous semicircular canal of cat: *x*, fibrous tissue supporting single layer of polyhedral epithelial cells (*y*).

On approaching the base of the crest the **epithelial cells** become more columnar, being much taller and narrower than those of the general surface. The **specialized cells** crowning the **summits** of the cristæ acusticæ, like other examples of neuro-epithelium, consist of elements of **two kinds,** the **sustentacular** or **fibre cells** and the **hair-cells.**

The **sustentacular elements** resemble those of the maculæ of the saccule and the utricle, extending the entire thickness of the epithelial layer and presenting an elongated narrow irregular cylindrical body, with prominent projecting oval nucleus.

The **hair-cells,** or **auditory cells,** reach only part-way to the basement-membrane and bear on their free surfaces enormously long **hair-processes,** the **auditory hairs,** which project at least as far as the middle of the lumen of the ampulla. The **auditory hairs** spring from the ends of the cells by minute conical expansions, and under high amplification are **resolvable** into a number of finer component hairs. The **nuclei** of the auditory cells usually lie within dilated rounded inner extremities of the cells, with which also the terminations of the auditory nerve come in close relations.

In sections of the ampullæ in tissue preserved with approved reagents the inner **free ends** of the **auditory hairs** are embedded within a peculiar dome-like structure, the **cupola,** regarding whose nature, and even existence during life, opinions greatly differ. As usually seen in well-preserved tissue, this structure appears as a faintly-striated **cuticular formation** covering in the ends of the hair-processes.

The fibres of the **auditory nerve** pass into the septum transversum, where they unite into net-works from which finer diverging **fibrillæ** pass into the overlying epithelium after losing their medullary substance. Small groups of **naked axis-cylinders** extend between the epithelial cells and separate into the individual fibrillæ, some of which are applied to the bases of the hair-cells, while others apparently seek their ultimate distribution at higher levels.

The **blood-vessels** supplying the semicircular canals comprise those destined for the **bony capsule** and those distributed to the

membranous structures. These vessels form a wide-meshed **capillary net-work** within the **fibrous tunic** of the canals and the ampullæ, which supplies both the endo- and perilymphatic surfaces.

THE COCHLEA.

The **cochlea** consists of the **tapering bony tube** wound spirally about its axis and containing the highly-**specialized** but much smaller **epithelial canal,** the **ductus cochlearis.** This latter tube,

FIG. 400.

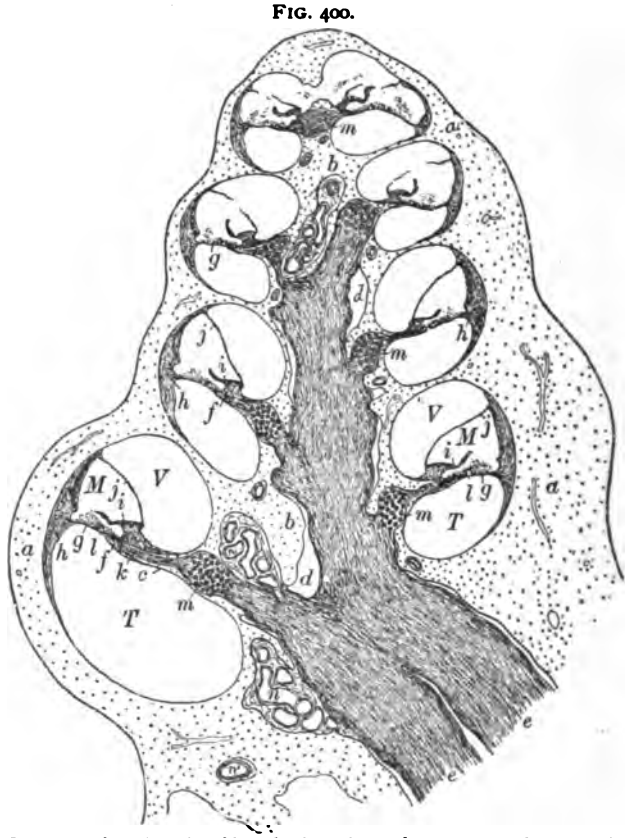

Longitudinal section of cochlea of guinea-pig: *a*, bony capsule; *b*, central shaft or modiolus; *c*, lamina spiralis; *d*, canal of modiolus containing bundles of nerve-fibres (*e*); *f*, terminal bundles; *g*, basilar membrane; *h*, spiral ligament; *i*, limbus; *j*, membrane of Reissner; *l*, Corti's organ; *m*, spiral ganglion; *n*, blood-vessels; *V*, *T*, *M*, respectively scala vestibuli, tympani, and media.

triangular in transverse section, is attached along its base to the outer wall of the bony tube, and along its narrow opposite border to the projecting osseous **spiral lamina**; in consequence of this arrange-

ment the **perilymphatic space,** instead of constituting a single cavity in which the epithelial tube is suspended, is divided into the **scala vestibuli** above and the **scala tympani** below, which **communicate** respectively with the **vestibule** and the **tympanum.**

The **ductus cochlearis,** or **scala media,** consists, like other portions of the membranous labyrinth, of the **epithelial tube,** the oldest part of the cochlea representing the specialized outgrowth from the primary ectodermic otic vesicle, and the supporting **fibrous tunic** derived from the differentiated surrounding mesoderm.

The **ductus cochlearis** is triangular in section; its **base** or **external wall** is attached to the outer wall of the bony capsule, its **apical border** is joined to the end of the **osseous spiral lamina,** and the converging **sides** are formed by the delicate **membrane of Reissner** above and the **basilar membrane** below, which separate respectively the scala vestibuli and the scala tympani from the scala media.

The **vestibular wall** of the cochlear duct is formed by **Reissner's membrane,** an extremely fragile partition dividing the duct from the scala vestibuli; the membrane begins on the vestibular border of the lamina spiralis, about .2 mm. inside the free edge of the crista, and extends at an angle of about forty-five degrees until it meets the outer bony wall. **Reissner's membrane** consists of **three layers:** an extremely thin central, almost homogeneous **connective-tissue stratum,** one side of which is covered by the **endothelium** of the vestibular surface and the other by the **epithelium** of the cochlear duct. Notwithstanding the extreme thinness of this layer, the presence within it of sparingly distributed **capillary blood-vessels** has been demonstrated. The **vestibular endothelium** consists of a single layer of delicate plates, which here and there enclose **pigment.** The surface towards the duct is covered by the general **ectodermic lining** of the canal, represented by a **single layer** of **flat polyhedral epithelial cells.** The three layers contribute equally to the 3 μ representing the entire thickness of the membrane.

The **outer wall** of the cochlear duct rests against a greatly thickened **crescentic cushion of connective tissue,** whose convex border is intimately united with the bony wall, and whose generally concave margin looks towards the cochlear duct. This area of connective tissue, the **ligamentum spirale,** extends both above and below the boundary of the cochlear duct, its two horns forming part of the outer walls of the adjacent vestibular and tympanic canals.

The **concave surface** of the **ligamentum spirale** is interrupted opposite the level of the tympanic wall of the cochlear duct by a projecting ridge, the **crista basilaris** (Schwalbe), to which the basilar

membrane or tympanic wall of the duct is attached. Near the base of the basilar crest the outer wall of the cochlear duct is marked by an **additional** smaller **projection, the prominentia spiralis, or accessory spiral ligament,** distinguished usually by the presence

FIG. 401.

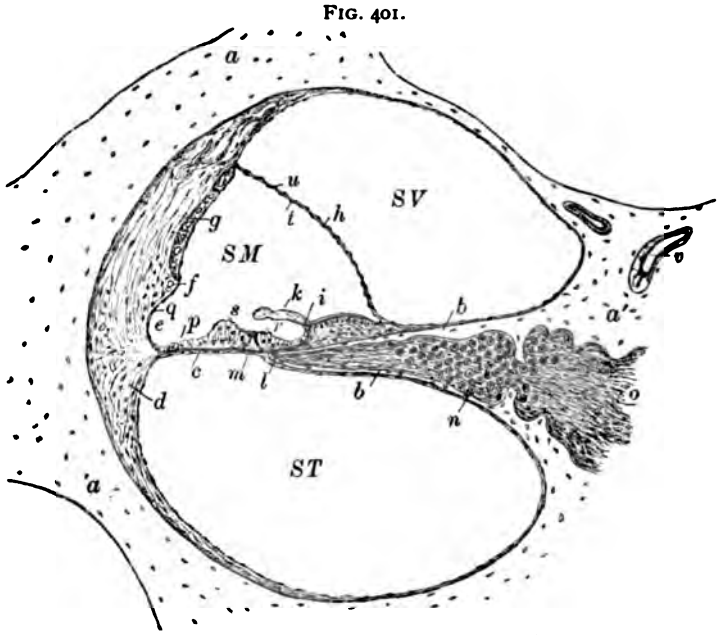

Section of single turn of cat's cochlea: *SV, SM, ST*, scala vestibuli, media, and tympani: *a*, osseous tissue projecting as spiral lamina (*b*); *c*, basilar membrane attached to spiral ligament (*d*) on outer wall; *e*, concave surface lined by flat cells (*q*) interrupted by spiral prominence (*f*) containing blood-vessel; *g*, stria vascularis; *h*, Reissner's membrane covered by epithelium (*t*) of cochlear duct and by endothelium (*u*) of scala vestibuli; *i*, limbus from which extends membrana tectoria (*k*) overhanging Corti's organ; *m*, tunnel of Corti; *r*, *s*, inner and outer hair-cells; *p*, cells of Claudius; *n*, spiral ganglion; *o*, nerve-bundles; *v*, blood-vessel.

of several small **blood-vessels.** The part of the wall lying between this prominence and the point of attachment of Reissner's membrane is occupied by a peculiar vascular structure, the **stria vascularis.**

The **epithelium** covering the **outer wall** of the cochlear duct varies in different positions; the usual **low flat cells** become higher and more cuboidal within the area corresponding to the **stria vascularis;** over the prominence the cells again become flat and polyhedral, but increase in height on approaching the basilar membrane.

The **stria vascularis** is remarkable on account of the existence of capillary blood-vessels **within an epithelial structure.** The presence of numerous vessels within the area is readily estab-

likewise the undoubted **epithelial** character of the innermost cells next the endolymph, but uncertainty exists concerning the true nature—whether epithelium or endothelium—of the cells filling the intercapillary spaces and lying between the epithelial layer and the adjacent connective tissue.

The **tympanic wall** of the cochlear duct consists of **two portions,**—the **limbus,** which includes the wall from the attachment of Reissner's membrane to the end of the lamina spiralis, and the **basilar membrane,** which extends from the end of the bony spiral lamina to the basilar crest on the outer wall.

The **limbus** corresponds to a conspicuous **local increase** in the periosteum and the fibrous coat at the point where the apical border of the cochlear duct is attached to the bony spiral lamina. The **greatest thickening** of the periosteal tissue occurs within the half of the limbus next the membrane of Reissner, the half adjoining the basilar membrane exhibiting an **abrupt decrease** in the layer, marked by a sharp edge overhanging the **sulcus spiralis,** the concavity formed by the receding border of the suddenly-diminished stratum; the upper and lower **edges** of the recess constitute the **superior** and **inferior labia.**

The **thicker portion** of the limbus between the membrane of Reissner and the superior labium is **remarkably modelled,** since its surface is **broken by clefts** and **furrows,** which become deeper as well as larger towards the margin of the superior labium; this peculiar arrangement culminates in the deeply-cleft edge of the superior labium, where irregular tongue-like processes separated by lateral clefts form the so-called **auditory teeth,** the entire number of which in the human cochlea has been estimated at about 2500.

The **epithelium** covering the **limbus** differs in various parts; **flat polyhedral cells** cover the **elevated portions,** including the auditory teeth, the intervening **furrows** and **clefts** being clothed by **columnar elements.** The epithelium lining the **sulcus spiralis** consists of a single layer of low cuboidal or **flattened polyhedral cells** continuous with the investment of the auditory teeth on the one hand and with the highly-specialized elements of Corti's organ on the other.

The **basilar membrane,** the outer zone of the tympanic wall, stretches from the end of the osseous spiral lamina to the basilar crest of the spiral ligament of the outer wall. The membrane bears upon part of its surface directed towards the cochlear duct the remarkably modified **neuro-epithelium** constituting the **organ of Corti,** and is consequently divided into the inner **zona tecta,** over which this end-organ lies, and the outer **zona pectinata,** covered with the more usual epithelium.

The basilar membrane includes **three** distinct layers,—the **epithelium,** the **substantia propria,** and the **tympanic lamella.** The **substantia** or **membrana propria** consists of almost homogeneous connective tissue, and represents an enormously-developed basement-membrane beneath the highly-specialized epithelium of the tympanic wall. This stratum is covered by a layer of peculiar connective tissue, the **tympanic lamella,** directly continuous with the **tympanic periosteum.**

The lamella contains numbers of **fusiform cells** of immature character interspersed with fibres; in this position the differentiation of the mesodermic cells lining the tympanic canal has never advanced to the production of typical endothelial plates, the free surface of the lamella being invested by the short fusiform cells alone.

FIG. 402.

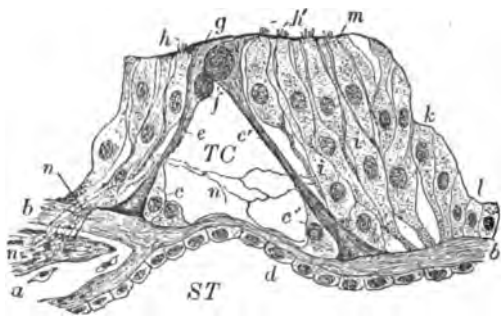

Section of Corti's organ from guinea-pig's cochlea: *ST*, scala tympani; *TC*, tunnel of Corti; *a*, bony tissue of spiral lamina; *b*, fibrous tissue covering same continued as substantia propria of basilar membrane; *c*, *c'*, protoplasmic envelope of Corti's pillars (*e*, *e'*); *d*, endothelial plates; *f*, heads of pillars containing oval areas; *g*, head-plates of pillars; *k*, *k'*, inner and outer hair-cells; *m*, membrana reticularis; *h*, *l*, cells of Hensen and of Claudius; *n*, nerve-fibres; *i*, cells of Deiters.

The **epithelium** covering the basilar membrane within the inner zone forms the remarkable **organ of Corti,** the highest example of specialization of neuro-epithelium anywhere encountered.

The **organ of Corti** extends the entire length of the cochlear duct, with the exception of a short distance within the blind terminal sacs at the two ends of the canal, where the neuro-epithelium is wanting. In general it consists of a **series of epithelial arches** formed by the interlocking of the ends of two converging greatly modified epithelial cells, the **pillars** or **rods of Corti,** upon the inner and outer sides of which rest groups of **neuro-epithelium;** the triangular space included between the converging pillars of Corti above and the basilar membrane below constitutes the **tunnel of Corti,** which is, therefore, only an **intercellular space** of unusual size, containing probably a soft semi-fluid intercellular substance serving to support the nerve-fibrils traversing the space.

Examined in detail, the **pillars** or **rods of Corti** prove to be composed of two parts, the denser **substance** of the **pillar proper** and a thin imperfect **protoplasmic envelope,** which presents a

triangular nucleated thickening at the base directed towards the cavity of the tunnel.

Each **pillar** possesses a slender slightly-S-shaped longitudinally-striated **body,** whose upper end terminates in the triangular **head,** and whose lower extremity expands into the **foot** resting upon the basilar membrane. The **inner pillar** is shorter, more perpendicular, and less curved than the outer; its head exhibits a single or double **concave articular facet** for the reception of the corresponding convex surface of the head of the outer rod. The **cuticular substance** of both pillars adjoining the articular surfaces is distinguished by a circumscribed seemingly homogeneous **oval area** of different nature. The upper straight border of the head of both pillars is prolonged outwardly into a thin process or **head-plate,** that of the inner rod lying uppermost and covering over the head and inner part of the plate of the outer pillar; the head-plate of the latter is longer and projects beyond the termination of the plate of the inner

FIG. 403.

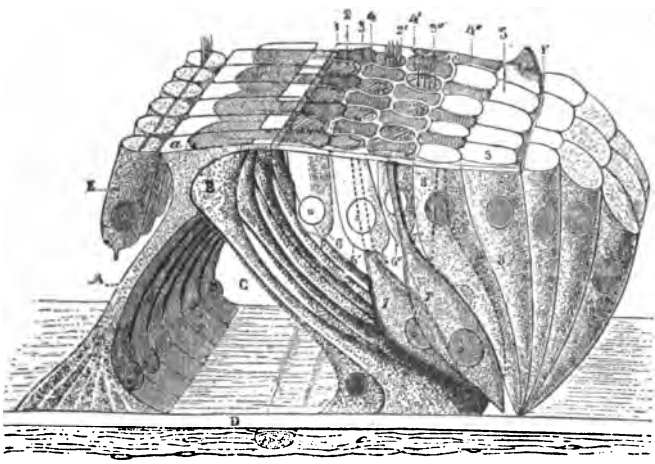

Diagrammatic view of Corti's organ: *A*, inner pillars of Corti (with head-plates *a*); *B*, outer pillars; *C*, tunnel of Corti; *D*, basilar membrane; *E*, inner hair-cells; 1, 1′, membrana reticularis; 2, 2′, 2″, rows of outer auditory hairs projecting between phalanges (4–4″); 5, terminal plates; 6–6″, outer hair-cells; 7–7″, cells of Deiters; 8, cells of Claudius. (After *Testut.*)

rod as the **phalangeal process,** uniting with the adjacent phalanges of the cells of Deiters to form the **membrana reticularis.** The **inner pillars** of Corti are **more numerous** but narrower than the outer elements, from which arrangement it follows that the broader **outer rods** articulate with two and sometimes three of the **inner pillars,** the number of the latter in man being estimated by Retzius at 5600, as against 3850 of the outer rods.

Immediately within the **arch of Corti,** resting upon the inner rods, a single row of **specialized epithelial elements** extends as the inner **hair-cells.** These elements, little more than half the thickness of the epithelial layer in length, possess a **columnar body,** whose dark granular protoplasm contains an **oval nucleus;** the **outer** somewhat constricted **end** of the cells is limited by a sharply-defined **cuticular zone,** from the free surface of which project, in man, some twenty **fine rods** or "**hairs.**" The **inner hair-cells** are less numerous, as well as shorter and broader, than the corresponding outer elements; their **numerical relation** to the inner **rods of Corti** is such that to every three rods two hair-cells are applied.

The **inner sustentacular cells** extend throughout the thickness of the epithelial layer, and exhibit a slightly-imbricated arrangement as they pass over the sides of Corti's organ to become continuous with the lower cells of the **sulcus spiralis.**

The **cells covering** the **basilar membrane** from the outer pillar to the basilar crest comprise **three groups:** those composing the outer part of Corti's organ, including the **outer hair-cells** and **cells of Deiters,** the **outer supporting cells,** or **cells of Hensen,** and the low cuboidal elements, the **cells of Claudius,** investing the outermost part of the basilar membrane.

The **outer hair-cells** are far **more numerous** than the corresponding inner elements, and in man and apes are disposed in **three** or **four rows,** alternating with the peculiar **end-plates** or "**phalanges**" of Deiters's cells which separate the ends of the hair-cells and join to form a cuticular net-work, the **membrana reticularis,** through the openings of which the hair-cells reach the free surface. The **inner row** of these cells lies directly upon the **outer rods of Corti,** so placed that each cell, as a rule, rests upon two rods; the cells of the **second row,** however, are so disposed that each cell lies opposite a single rod, while the **third layer** repeats the arrangement of the first; in consequence of this grouping these elements, in connection with the "phalanges," appear in surface views like a **checker-board mosaic,** in which the oval free ends of the **auditory cells** are included **between** the peculiar compressed and indented **octagonal areas** of the end-plates of **Deiters's cells.**

The **outer auditory** or **hair cells** are cylindrical in their general form, terminating about the middle of the epithelial layer in slightly-**expanded rounded ends** near which the **spherical nuclei** are situated. The **outer** sharply-defined **ends** of the cells are distinguished by a **cuticular border** supporting about twenty fine, rigid **auditory rods** or "**hairs**" which project beyond the level of the membrana reticularis.

The **sustentacular elements,** the **cells of Deiters,** have much

in common with the rods of Corti, being **specialized epithelial cells** which extend the entire thickness of the epithelial stratum to terminate in the peculiar **end-plates** or **phalanges.** It follows that while the **free surface** of Corti's organ is composed of both **auditory cells** and **sustentacular cells,** the elements resting upon the **basilar membrane** are of one kind alone,—the **cells of Deiters.** The **bodies** of the latter consist of two parts,—the elongated **cylindrical chief portion** of the cell, containing the **spherical nucleus** and resting upon the basilar membrane, and the greatly-attenuated **pyramidal phalangeal process.** A system of communicating **intercellular clefts,** the **spaces of Nuel,** lies between the auditory and supporting cells; these are occupied by a **semi-fluid intercellular substance,** like the tunnel of Corti, which they connect.

The **membrana tectoria,** or **Corti's membrane,** stretches from the upper lip of the limbus above the sulcus spiralis and Corti's organ as far as the last row of the outer hair-cells. The membrane is a **cuticular production** originally formed by the cells covering the region of the **auditory teeth** and the **spiral sulcus**; at first it rests upon the epithelial cells, but later it becomes separated from those lying external to the free edge of the auditory teeth and assumes its conspicuous position over the organ of Corti. The membrane seems to be composed of fine **resistant fibres** held together by an **interfibrillar cement-substance.** During life the membrane is probably **soft** and **gelatinous** and much less rigid than its appearance after reagents indicates.

The **outer sustentacular cells,** or **cells of Hensen,** form an outer zone immediately external to the last Deiters's cell; these elements resemble the inner sustentacular cells, but differ somewhat in form and arrangement. In consequence of their **oblique positions** the bodies are not only greatly elongated but also imbricated.

The **cells of Claudius** are the direct continuations of Hensen's cells, and pass uninterruptedly into the **low columnar elements** covering the remaining part of the basilar membrane. These cells possess clear faintly **granular protoplasm,** in which **pigment-granules** are frequently seen as well as **spherical nuclei.** At the outer extremity of the basilar membrane these cells are continuous with the epithelium covering the upper surface of the basilar crest.

The **nerves of the cochlea,** branches of the cochlear division of the auditory nerve, present an intricate arrangement, the exact mode of their ultimate termination being still in many points uncertain. With the exception of bundles for the supply of the **first turn,** which run in channels leading **directly** to the peripheral spiral canal, the cochlear nerves pass into the **central canal** of the modiolus, from which a series of large-sized lateral branches diverges at quite regular intervals through canals communicating with the

peripheral spiral canal within the base of the bony spiral lamina. Within the **peripheral canal** the nerve-fibres are augmented by numerous **nerve-cells,** continuing along the spiral canal as the **ganglion spirale.** From this numerous twigs are given off, which pass along the canals within the spiral lamina towards its margin, the twigs meanwhile subdividing to form an **extensive plexus** contained within corresponding channels in the bone. At the edge of the spiral lamina bundles of fine fibres are given off, which escape at the **foramina nervina** and enter the epithelium close to the inner rod of Corti. During or before their passage through the foramina the nerve-fibres **lose** their **medullary substance** and proceed to their destination as fine, naked axis-cylinders.

The **radiating bundles** pass within the epithelium to the inner side of the base of the **inner pillar,** where they divide into **two sets** of fibrillæ, one going to the **inner hair-cells,** the other passing between the inner pillars to reach the **tunnel.** After crossing this space the fibrillæ escape between the **outer rods** into the **epithelium** lying on the outer side of the arch. The further course of the fibrillæ seems to be such that **some fibrillæ** extend between the **outer pillar** of Corti and the **first row** of hair-cells, while succeeding groups of fibrillæ course between the rows of Deiters's cells to reach the remaining hair-cells. The exact relation between the nerve-fibrils and the auditory cells, as to whether the fibrillæ actually join the cells or only come in close contact, is yet a matter of uncertainty, although renewed investigations render it still improbable that direct **anatomical continuity** exists.

The **ductus** and **saccus endolymphaticus** possess walls which closely correspond with those of the saccule and the utricle, composed of a thin connective-tissue **tunica propria** supporting the lining of **ectodermic epithelium**; the latter consists of a single layer of **flat polyhedral cells.** The **duct** lies within the bony aqueduct, closely united with the periosteal lining, unsurrounded by an extension of the perilymphatic space; in a few localities a meagre layer of loose connective tissue forms a less intimate bond between the periosteum and the fibrous coat of the duct.

The **cochlear perilymphatic spaces,** the **scalæ vestibuli et tympani,** include within their walls the same tissues that bound similar cavities within other parts of the internal ear. The **periosteum** of the bony cochlea constitutes the **fibrous tunic,** which is usually covered on the surface in contact with the enclosed perilymph by a single layer of **endothelial plates**; in some localities, however, as on the tympanic surface of the basilar membrane, the lining cells retain their primitive mesodermic character, never becoming fully differentiated into endothelium.

The **blood-vessels supplying the cochlea** constitute **two groups,**—the branches distributed to the **membranous cochlea** and the numerous twigs destined for the **bony capsule.** The cochlear branch of the auditory artery, just before its passage through the bony wall, divides into fifteen to twenty twigs, which pass either directly through canals to supply the lowest turn of the cochlea or into the modiolus. The vessels within the **central canal** of the modiolus, after supplying the nerve-trunks and the spiral ganglion with nutritive twigs, send off lateral branches, which form two remarkable masses of coiled vessels, the **glomeruli cochleæ;** from the **larger** of these, situated somewhat above the point of origin of the bony spiral lamina, arterioles proceed to Reissner's membrane and to the limbus, breaking up to form the capillary net-works of these structures. The **smaller glomeruli,** within the base of the partitions separating the adjoining cochlear turns, send off branches forming two independent capillary systems. These are the net-works within the **basilar membrane** and those of the **stria vascularis,** which, while having a common origin, do not communicate. The **capillaries** of the membranous cochlea are collected into two principal trunks, the **vas prominens** on the outer wall and the **vas spirale** beneath the basilar membrane opposite the inner rods of Corti; from these channels the blood is conveyed to the larger venous trunk, the **vena spiralis modioli,** lying below the spiral ganglion within the base of the osseous spiral lamina.

The **lymphatics of the internal ear** are represented by the large **lymph-spaces** included between the membranous labyrinth and its bony capsule,—the **perilymphatic spaces** of the semicircular canals, the utricle, the saccule, and the cochlea. These large intercommunicating spaces are in **direct exchange** with the **subarachnoidean** and probably also the **subdural** intra-cranial lymph-cavities. The demonstrated communication between the **cavity of the endolymph** and the **subdural space** by means of the saccus endolymphaticus brings the contents of the membranous labyrinth into closer relations with the lymphatic system than was formerly recognized.

THE DEVELOPMENT OF THE EAR.

The development of the ear includes the formation of two morphologically distinct divisions, the **membranous labyrinth,** the essential auditory structure, and the **accessory parts,** comprising the middle ear, with its ossicles and associated cavities, and the external auditory canal and the pinna.

The developmental history of the organ of hearing proper in its early stages is largely an account of the growth and differentiation

of the **ectodermic otic vesicle,** since from this is produced the important **membranous tube,** the enveloping **fibrous** and **osseous structures** being comparatively late contributions from the **mesoderm.**

FIG. 404.

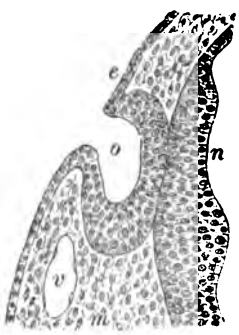

Section through developing ear of nine-and-a-half-day rabbit embryo: *e*, ectoderm thickened and invaginated to form auditory pit at *o*; *m*, surrounding still undifferentiated mesoderm; *n*, lining of neural tube; *v*, blood-vessel.

The **internal ear** first appears as a thickening and soon after depression of the **ectoderm** within a small area on either side of the cephalic end of the neural tube at a level corresponding to about the middle of the future medulla. This **auditory pit** is widely open for a considerable time and distinguished by the great **thickness** of its depressed wall, which contrasts strongly with the adjacent ectoderm. After a time the lips of the pit approximate until by their final union the cup-like depression is converted into a closed sac, the **otic vesicle.**

The **otic vesicle,** after severing all connection with the ectoderm, gradually recedes from the surface in consequence of the growth of the intervening mesodermic layer; it next loses its spheroidal form and becomes **pear-shaped,** with the smaller end directed dorsally. This diverticulum is the first appearance of the **recessus vestibuli,** a division of the embryonal labyrinth disproportionately conspicuous compared with its perm representative, the **ductus endolymphaticus.**

FIG. 405.

Sagittal section through developing ear of ten-day rabbit embryo: *o*, otic vesicle becoming pear-shaped, due to formation of recessus vestibuli (*r*); *m*, surrounding mesoderm.

FIG. 406.

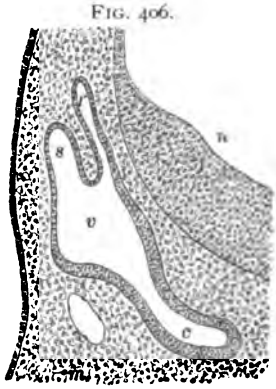

Section through developing ear of twelv rabbit embryo: *v*, primitive vestibule, which extend (*r*) recessus labyrinthi a semicircular canal above and (*c*) cochlear below; *n*, neural tube with thickened lining; *m*, mesoderm.

The **semicircular canals** next form as tubular projections from the vesicle and rapidly assume great prominence; the **superior vertical canal** appears first, and the **external** or **horizontal canal** last. The growth of the epithelial diverticula is later accompanied by a **condensation** of the surrounding **mesoderm**, which differentiates into an **external layer**, the future cartilaginous and later bony capsule, and an **inner layer** of fibrous tissue. The latter suffers partial atrophy and absorption, in consequence **clefts** appear among the delicate bundles, an arrangement permanently represented by the fibrous **walls** and intervening **trabeculæ** of the spaces occupied by the **perilymph** surrounding the membranous canals. Within the **ampullæ**, which early develop, the epithelial lining undergoes **specialization**, accompanied by thickening of the mesodermic wall within circumscribed areas to form the **cristæ acusticæ**.

Coincidently with the development of the semicircular canals a diverticulum—the **cochlear canal**—appears at the lower anterior end of the membranous sac; this tube, oval in section, grows forward, downward, and inward, and represents the future **cochlear duct**, or **scala media**. After attaining considerable length, further elongation is accompanied by coiling and the assumption of the permanent disposition of the tube.

The **epithelium** of the **cochlear tube** early exhibits a distinction, the cells of the upper surface of the somewhat flattened canal becoming **attenuated**, while those on the lower wall undergo **thickening** and further **differentiation**; the flattened cells form the covering of **Reissner's membrane** and the **outer wall**, and the taller elements are converted into the complicated structures of the **tympanic wall** of the scala media, including the **crista**, the **sulcus**, and the **organ of Corti**.

The development of these structures includes the differentiation of **two epithelial ridges**; from the **inner** and larger of these is derived the lining of the **sulcus spiralis** and the overhanging **membrana tectoria**, and from the **outer** and smaller ridge is produced the elaborate and complicated **organ of Corti**. The **crista** appears between the sulcal cells and the cochlear axis as a thickening of the spiral lamina.

The **cochlear outgrowth** of the primary otic vesicle forms the **membranous cochlea**, or **scala media**, alone, the walls of the adjacent divisions, the **scala vestibuli** and **scala media**, resulting from the changes within the surrounding **mesoderm**. The latter differentiates into **two zones**, an **outer**, which becomes the **cartilaginous**, and finally **osseous**, **capsule**, and an **inner**, lying immediately around the membranous canal, which for a time constitutes a **stratum** of delicate **connecting tissue** between the denser

capsule and the ectodermic canal. Within this layer **clefts** appear, which gradually extend until **two large spaces** bound the membranous cochlea above and below.

These spaces, the **scala vestibuli** and the **scala tympani,** are separated for a time from the scala media by a **robust septum** consisting of a **mesodermic layer** of considerable thickness and the wall of the **ectodermic tube.** With the further increase in the dimensions of the lymph-spaces the partitions separating them from the cochlear duct are correspondingly reduced, until, finally, the once broad layers are represented by frail and attenuated structures, the **membrane of Reissner** and the **basilar membrane,** which consequently include an **ectodermic stratum,** the epithelial layer, strengthened by a **mesodermic lamina,** represented by the substantia propria and its endothelioid covering.

FIG. 407.

Section through developing cochlea of twenty-one-day rabbit embryo: *e*, sections of ectodermic cochlear duct, or scala media, surrounded by delicate mesodermic tissue (*m*), within which large lymph-spaces later appear; *c*, condensed cartilaginous capsule; *n*, bundles of nerve-fibres.

The main sac of the **otic vesicle** from which the foregoing diverticula arise constitutes the **primitive membranous vestibule,** and later subdivides into the **saccule** and the **utricle.** This separation begins as an **annular constriction** of the primitive vestibule, incompletely dividing the vesicle into two compartments; the **ductus endolymphaticus** unites with the narrow canal connecting these vesicles in such manner that each space receives one of a pair of converging limbs, an arrangement foreshadowing the permanent relations of the parts.

Even before the subdivision of the primitive vestibule is established the vestibular end of the **cochlear canal** becomes constricted, so that communication between this tube and the future saccule is maintained by only a narrow passage, the **canalis reuniens.** The development of the **maculæ acusticæ** of the saccule and the utricle depends upon the **specialization of the epithelium** within certain areas associated with the distribution of the auditory nerves. The **nerve-fibres** form their ultimate relations with the sensory areas by secondary growth into the epithelial structures.

From the foregoing it is apparent that the **membranous labyrinth** is genetically the **oldest part** of the internal ear, and that it is in fact only the greatly modified and specialized closed **otic vesicle** surrounded by secondary mesodermic tissues and spaces.

The **middle ear** is derived from the expanded and metamor-

phosed **outer end** of the **first pharyngeal pouch**, or **inner visceral furrow**, the **Eustachian tube** representing the **inner segment.** The **tympanic membrane** results from the changes affecting the **septum** between the outer and inner first visceral furrows ; this partition, originally thick, consists of a **mesodermic** middle stratum, covered on its outer and inner surfaces respectively by the **ectoderm** and the **entoderm.** The external and the middle ear **at no time communicate,** but are normally separated by the septum in question.

The **ear-ossicles** are developed in connection with the **primitive skeleton** of the **visceral arches** ; the **malleus** and the **incus** represent specialized parts of the **cartilaginous rod** of the **first arch.** The **stapes** is probably developed from the second visceral arch ; the peculiar form of the stapes results from the perforation of the original cartilaginous plate by a small artery which later disappears.

The development of the **external ear** results from the changes taking place within the **first outer visceral furrow,** or **gill-cleft,** and the **tissue immediately around** its external orifice. From the gill-cleft originates the **external auditory canal,** and from the margins of its orifice the **pinna** is formed.

CHAPTER XIX.

THE NASAL MUCOUS MEMBRANE.

THE mucous membrane lining the nasal fossæ consists of two principal divisions, that of the **respiratory** and that of the **olfactory region**; the latter alone is concerned in the sense of smell.

The **mucous membrane of the respiratory region** is distinguished from that of the olfactory area by its **thickness**, over the inferior turbinals it reaching 4 mm., and by the presence of **venous networks** of such size that the structure appears as if composed of cavernous tissue. The **epithelium** of this region is **stratified ciliated columnar** in type, within the superficial layer of which numerous **goblet-cells** are interspersed. The **tunica propria** of this region is composed of fibrous connective tissue containing clefts occupied by many **leucocytes**, the latter frequently invading the superimposed epithelium; occasional **nodules of lymphoid tissue** are also encountered in various parts of the mucosa. The surface of the tunica propria is smooth, since the usual subepithelial papillæ are here wanting.

FIG. 408.

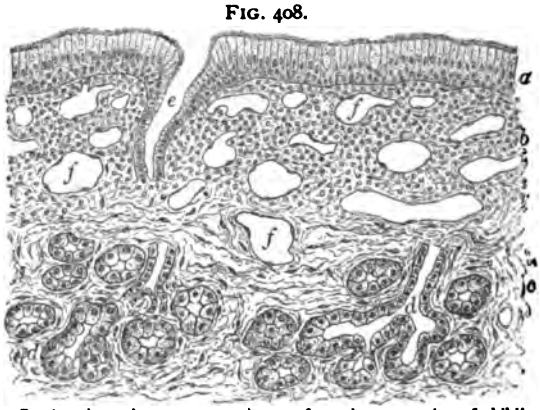

Section through mucous membrane of respiratory region of child's nose: *a*, ciliated epithelium; *b*, tunica propria; *c*, submucous connective tissue; *d*, mucous glands; *e*, duct of glands opening on free surface; *f*, blood-vessels.

The **mucous membrane** of the respiratory region is further distinguished by numerous **small racemose glands**, which open on the free surface by funnel-like pits, readily recognized by the unaided eye, and lined for some distance by epithelium corresponding to that of the adjacent surface. These **glands** are **mixed** in character, since some acini secrete **serous fluids**, while others elaborate **mucous products**. The glandular structures occur with especial frequence over the inferior turbinated bones, although on the lateral

walls and on the lower part of the nasal septum they are present in large numbers. As already mentioned, the **veins** of the mucosa are so wide and plentiful that the layer in which they lie appears like **cavernous tissue.**

The mucous membrane lining the **accessory spaces** of the nasal fossæ—the **sphenoidal,** the **frontal,** and the **maxillary sinuses** and the **ethmoidal cells**—closely resembles that of the respiratory region, being covered by a **stratified ciliated epithelium,** which rests upon a thin tunica propria closely united with the periosteum. These tracts are chiefly distinguished from the respiratory surface by the **marked reduction** in the thickness of the mucous membrane, which within these spaces is seldom more than .02 mm. The **meagre supply** of glands is another point of difference, the glandular structures within these spaces being represented by small and sparingly distributed groups often exhibiting peculiar modifications of the racemose type.

The **olfactory region** is distinguished macroscopically from the respiratory portions of the nasal fossæ by the **yellowish-brown tinge** of its mucous membrane as contrasted with the rosy hue of that covering the adjacent region; the more deeply colored tract indicates in only a general way the boundaries of the olfactory region, since the limits of the two do not closely correspond, the brownish area in man being usually somewhat less extensive than the entire surface possessing the structure of the olfactory mucous membrane. The latter is also distinguished by its greater thickness and by the absence of ciliated cells.

FIG. 409.

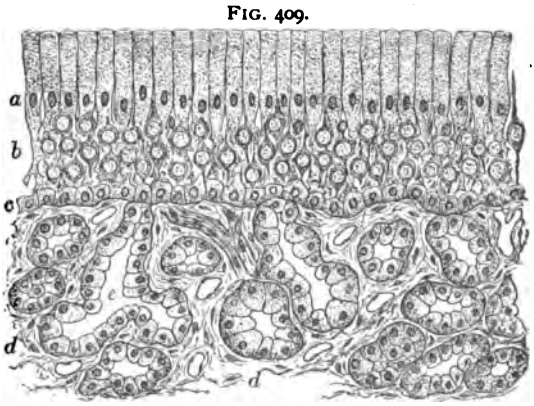

Section through olfactory mucous membrane from child's nose: *a*, zone of oval nuclei belonging to sustentacular cells; *b*, zone of spherical nuclei of olfactory elements; *c*, basilar cells; *d*, subepithelial tissue; *e*, glands of Bowman.

The **olfactory mucosa** consists of the epithelium and the tunica propria, the characteristic appearances of the tissue depending upon the peculiarities of the former, another example of neuro-epithelium. This **epithelium** consists of two kinds of cells, the **sustentacular** and the **olfactory elements.** The **sustentacular** or **support cells** present

an **outer** cylindrical division, containing an **oval nucleus,** situated always near the inner end of the more expanded part of the cell, and **yellowish pigment,** together with numerous granules arranged more or less markedly in **longitudinal** rows. The outer ends of the supporting cells are modified into a **cuticular zone,** the **membrana limitans olfactoria,** sometimes exhibiting vertical markings.

The **nuclei of the sustentacular cells** form a regular band, the **zone of oval nuclei,** which lies next the free surface, and strongly contrasts with the adjoining broad **zone of round nuclei** of the **olfactory** cells. The **inner portions** of the sustentacular elements are very narrow, irregular in outline, and terminate generally in **cleft** or **branched processes** in close relation with the underlying basal cells.

The **olfactory cells** lie among the supporting elements as inconspicuous, elongated, and attenuated bodies, whose variously-placed **spherical nuclei,** covered by a thin stratum of protoplasm, constitute the widest parts of the cells; in consequence these elements appear like spherules from the outer and inner poles of which thin **rod-like processes** extend towards the free surface and the basement-membrane. The **nuclei of the olfactory cells** lie at all levels, forming the broad **zone of round nuclei.**

The **deepest part** of the epithelial stratum is made up of a closely-set **zone of small nucleated cells,** resting upon the tunica propria on the one hand, and sending irregularly-branched processes among the overlying elements on the other. These **basilar cells** constitute a protoplasmic net-work, whose extensions and continuities are at present inadequately determined.

The **tunica propria** of the olfactory region consists of a moderately loose felt-work of bundles of fibrous connective tissue, intermingled with numerous delicate elastic fibres. The outermost zone of the tunica propria is condensed to form a very slightly developed **basement-membrane,** upon which rests the epithelium. Embedded within the mucosa **branched tubular glands,** or **Bowman's glands,** exist in great abundance; these structures possess a **duct** of sufficient length to extend through the epithelial layer, the remaining portions of the tube constituting the **body** and **fundus** of the gland. The **epithelial cells** lining the secreting part of the tube contain **brownish pigment,** which aids in producing the characteristic color of the olfactory mucous membrane. Although formerly regarded as serous in type, it is probable that Bowman's glands must be included within the **mucous group.** These glands, which in places constitute an almost **continuous layer** of secreting tissue, are much more generously distributed than those within the respiratory region.

The **blood-vessels** supplying the nasal mucous membrane are especially distinguished by the **size** and **profusion of the veins.**

The arterial stems lie in the deeper layers of the tunica propria, from which twigs are sent into the more superficial stratum, where, immediately beneath the epithelium, a **subepithelial capillary net-work** is formed; other twigs break up into capillaries which surround the glands. The **veins** are remarkable for their size and number, in many places, particularly over the posterior part of the inferior turbinated bone, giving to the entire tunica propria the **character of cavernous tissue.**

The **lymphatics** are represented by numerous vessels which constitute a net-work within the deeper parts of the tunica propria and around the lymphoid nodules; in addition to these, within the olfactory region wide-meshed net-works of **perineurial lymph-channels** extend throughout the **mucosa of the olfactory region.** The olfactory mucous membrane is further provided with a rich system of intercommunicating **lymph-spaces** within the groundwork of the tunica propria, which empty into the larger lymphatic net-works of the deeper layers.

The **nerves** of the nasal mucous membrane are of **two kinds,** those providing **common sensation** and those concerned in the **special sense** of smell; the relations of the latter with the neuro-epithelium are of much interest, but at the present time by no means definitely determined. The larger filaments of the **olfactory nerve** lie against the bony walls, partially embedded within corresponding grooves, and give off smaller arching bundles, which pass within the mucous membrane towards its epithelial surface. The twigs, even within the mucosa in many places, are enclosed by **perineurial sheaths** prolonged from the intercranial investment of the olfactory nerve. The fibres of the latter are **without the medullary substance,** being bundles of the axis-cylinder fibrillæ enclosed within the neurilemma; on reaching the epithelium the fibres break up into their component fibrillæ, which pass as naked, often varicose, **axis-cylinders** towards the elements of the neuro-epithelium. The olfactory nerve-fibres are connected peripherally with the olfactory cells within the nasal mucous membrane. After passing into the cranium they terminate in rich arborizations in relation to the peculiar glomeruli already noted in connection with the olfactory lobe. **Additional twigs** from the trifacial, composed of **medullated fibres,** are also distributed to the olfactory region, without, however, coming in relation with the olfactory cells.

The **development of the nasal mucous membranes** proceeds from the **ectoderm,** the earliest indication of these structures appearing as the **olfactory plates,** two areas of thickened ectoderm immediately above the primitive oral cavity and in contact with the wall of the fore-brain.

The **olfactory plates** are converted into the **nasal pits** by the growth and elevation of the surrounding parts on all sides except the under surface, along which the nasal pits for a time directly communicate with the primary mouth. In addition to the differentiation of the surrounding tissues into the structures of the external nose, the close relation of the primary nasal surface with the brain-vesicle disappears with the changes of position produced by the development of the fore-brain and growth of the tissues forming the cranial case, particularly the development of the olfactory ganglion from the olfactory plate.

The complicated surfaces of the nasal fossæ are due primarily to the appearance of the superior, middle, and inferior **turbinal folds** on the lateral wall of the nasal recess. Each fold comprises the **duplication of ectoderm** enclosing a **core of mesoderm**; the latter becomes the **turbinal cartilages** and finally the corresponding **osseous plates.** The **differentiation** of the olfactory region from the general lining of the nasal fossæ takes place coincidently with the growth of the olfactory nerve-fibres; the details of the histogenesis of these structures, however, are still but imperfectly determined.

The **special organs of taste** and **of touch,** including the **taste-buds** and the **tactile corpuscles,** have been already considered in connection respectively with the tongue and with the peripheral nerve-endings and the skin.

APPENDIX:

INCLUDING THE MOST USEFUL HISTOLOGICAL METHODS.

THE advances made during the last few years in the preparation of tissues for microscopical examination have been so important, that no one proposing to undertake practical histological investigations, normal or pathological, can afford to ignore methods of work which, although somewhat exacting, yield results far superior to the older processes. With the increased facilities for producing thoroughly good and accurate preparations the current standard of excellence has advanced, and results formerly viewed with complacency are now often regarded as incomplete and correspondingly unsatisfactory.

The activity of the last half-dozen years has resulted in greatly multiplying the details of histological technology, since each worker determines what new procedures or modifications of existing methods are advantageous for his own special purposes. Useful, and for the advanced worker indispensable, summaries of the ever-increasing methods of microscopical investigation are to be found in the volumes especially devoted to technology; of such works in English the excellent "Microtomist's Vade-Mecum," by Bolles Lee, may be recommended, supplemented by the notices of new methods presented in the current issues of the Journal of the Royal Microscopical Society.

In the present place, however, no attempt will be made to discuss even incompletely many of the methods finding use at the hands of various investigators; but, on the contrary, only a few processes will be described which extended use has proved to be thoroughly trustworthy and satisfactory. The student undertaking such work for the first time is strongly advised to persevere with the paraffin method, as here described, since, when properly employed, it may always be depended upon to yield the most gratifying results. Failures, sure to beset the beginner, should be carefully analyzed and be made to yield the experience which will guard against their repetition.

The manipulations necessary for the conversion of the fresh tissue into the finished preparation are:

1. Fixation of the tissue.
2. Preservation of the fixed tissue.

3. Staining of the tissue *in toto*.
4. Embedding in paraffin.
5. Sectioning.
6. Fixing sections to the slide.
7. Mounting.
8. Finishing, labelling, and storing.

1. **Fixation of the Tissue.** By "fixation" is understood the killing of the tissue so rapidly that its elements are retained exactly as they were while living when first met by the fixing reagent; thus, for example, extended cells should remain extended after death, or rapidly-effected changes, as those of karyokinesis, should be retained in the stage in which first encountered, and not be allowed to complete their cycle, and consequently disappear, as when the tissue slowly dies. It is evident that *absolutely fresh* and, for many investigations, still living tissues are essential for satisfactory results where the condition of the cells is a matter of importance, as in the study of the structure of the nucleus or of the protoplasm.

While so evidently desirable, the fulfilment of this condition in the case of human tissues is often a matter of impossibility, or, at best, of extreme difficulty, the restrictions imposed upon immediate autopsies rendering it usually almost impossible to secure the more delicate tissues while their cells are still alive. Fortunately, however, for the majority of investigations, the exact condition of the cell is a matter of less moment than its general form and its relations to the surrounding elements; for such purposes the slow death of the cells may work no serious detriment to the usefulness of the tissue, but it is to be accepted as a histological maxim, that *the fresher the tissue and the more accurate the fixation of its elements, the more valuable and satisfactory will be the preparation.*

When, then, really *fresh material* is to be prepared for subsequent histological examination, it is to be subjected, *without* previous washing in water, first to the action of some *fixation fluid;* the choice of the reagent to be employed must be determined by the purposes in view and the character of the tissue.

a. Müller's Fluid.

Potassium bichromate	2.5 gm.
Sodium sulphate	1.0 gm.
Water	100 c.c.

This fluid, when properly employed, is probably the most generally useful fixation reagent; for successful results, however, strict attention to the manner of its employment is imperative. The quantity of fluid must always be *largely in excess of the volume of the tissue*

treated, and the tissue should not be in pieces over 2 cm. in thickness; the fluid should be changed *as soon as it becomes turbid*, sometimes within the first hour, and subsequently renewed as often as may be necessary *to maintain perfect transparency*. Tissues are usually allowed to remain in Müller's fluid for a considerable time, two weeks being the minimum, while they may be permitted to lie much longer, usually, without disadvantage; it is advisable, however, to remove specimens after six weeks, and preserve them in spirit.

The tissue is transferred from the Müller's fluid to water, and thoroughly washed in the *running stream* from 4 to 6 hours, until all excess of the fluid has been removed; it is then placed in *70 per cent. alcohol* and *kept in the dark*, the spirit being renewed whenever strongly tinged by the removed fluid; as long as discoloration occurs an occasional change of alcohol is desirable.

Where the interstitial methods of embedding are followed, no great amount of *hardening* is necessary or even desirable, in which case the tissues are best stored in *80 per cent. spirit*, where they may lie until needed. Portions of the nervous system which are subsequently to be stained after the Weigert process may be fixed with advantage in *warm Müller's fluid*, being kept in an oven from 8 to 10 days at a temperature of 35° C.

b. Absolute Alcohol. For glands, skin, blood-vessels, etc., absolute alcohol affords a rapid and admirable means of fixation, and possesses the additional quality of simultaneously hardening the tissue, a matter sometimes of great convenience, since the specimen may be cut within 24 hours. Small pieces of tissue, so placed either by suspension or support on cotton that they *do not come in contact* with the bottom or the sides of the glass (to which they otherwise adhere), are treated from 12 to 24 hours, the alcohol being *invariably changed* at the end of the first three hours, whether cloudy or not. After fixation the tissue is preserved in 80 per cent. spirit. It is to be noted that the action of 95 per cent. alcohol is *entirely different* from that of the absolute, with the weaker spirit the shrinkage being great and the fixation imperfect; it cannot, therefore, be substituted.

c. Flemming's Solution.

Chromic acid (one-per-cent. solution)	7.25 c.c.
Osmic acid (two-per-cent. solution)	2.50 c.c.
Glacial acetic acid, at least	.25 c.c.

Where the structure of the protoplasm or the nucleus is to be investigated, or where for any purpose an accurate picture of the cells is desirable, Flemming's stronger solution (given above) will be found the most trustworthy reagent at our command. Two drawbacks limit

its use: its very limited power of penetration, which necessitates the tissue being cut in layers not over 2–3 mm. thick, and the considerable expense attending the use of large quantities of the fluid. The mixture should be made up each time *just before using*, and *cannot be employed a second time*. The *living tissue* is placed within the solution in a glass-stoppered bottle, and allowed to remain, *without changing*, 24 hours; then transferred to *running water* 1–2 hours, after which it is placed in 70 per cent. alcohol, and, after several changes, preserved in 80 per cent. spirit.

d. Picro-Sulphuric Acid (Kleinenberg's) Solution.

Picric acid, saturated watery solution	200 c.c.
Sulphuric acid, pure	4 c.c.

resulting in dense precipitate; after one hour filter, and dilute with three volumes (600 c.c.) of distilled water.

This solution is an admirable and trustworthy reagent *for embryos* and other *delicate structures*, its principal objection being the time required to remove the yellow tinge of the picric acid. The embryos are placed directly, without washing, into the fluid, where they remain 5 hours—if very large the time may be extended to 10–12 hours, with a renewal of the fluid; they are then transferred to 70 per cent. alcohol, which is repeatedly changed until discoloration no longer takes place; preserve in 80 per cent. alcohol.

2. **Preservation of Tissues.** In connection with fixation, the subsequent preservation of tissues in 70 per cent. spirit has been indicated; when, however, the condition of the specimen, as when obtained some time after death, or other considerations, render fixation useless, it becomes necessary to preserve the tissue from further change. To this end Müller's fluid may also be advantageously employed, observing the precautions already pointed out, followed after some weeks by alcohol. In many cases, however, when fixation is no longer possible, *alcohol* offers the most convenient method of preservation, possessing as it does the merits of simplicity and of rendering the tissue receptive to all forms of staining.

In the *employment of alcohol* for hardening, the tissue should be passed through a series of gradually-increasing strength; beginning with 60 per cent. spirit for 2–3 days, with renewals when turbid, the tissue is placed successively, at intervals of 3–4 days, into 70 per cent., 85 per cent., and 95 per cent. alcohol, finally, after sufficient hardening, to be preserved indefinitely in 80 per cent. spirit.

In those cases where *bone* or *calcareous matters* are present, fixation and hardening must be followed by *decalcification* and *softening;*

this is most conveniently and quickly accomplished by placing the *fixed and partially-hardened tissue* in a *large quantity* of *dilute nitric acid*, varying in strength from 3 to 9 per cent. The fluid should be changed *daily* for three days, subsequently every *second day*. The completion of the decalcification may usually be determined by judiciously passing a fine needle into the tissue. After suspending the acid solution, whose too prolonged action may result very disastrously for the softer parts, the tissue is *thoroughly washed* for some hours in running water, and then placed in alcohols of gradually-increasing strength to complete the hardening.

3. **Staining.** Since the introduction by Gerlach, now some forty years ago, of a means of differentially coloring tissues, the list of staining methods has gradually been extended, until their description at the present time would cover pages; notwithstanding the multiplication of formulæ and their claimed advantages for particular purposes, all ordinary investigations may be satisfactorily carried on with the aid of a very limited selection. Among the important stains, *carmine* and *hæmatoxylin* stand pre-eminent on account of their general applicability and their certainty. The relative merits of carmine and hæmatoxylin are well defined by their respective advantages.

Carmine is, as usually now employed, a *pure nuclear stain*, possessing great penetrating properties, and hence being well adapted for staining tissues and small animals *in toto*,—a matter of much importance in many lines of work requiring serial sections; further, carmine is permanent, remaining bright and unfaded after years of exposure, does not overstain, and produces preparations admirably adapted to the needs of the improved methods of **photomicrography.**

Hæmatoxylin, on the other hand, is more than a nuclear stain, yielding, when successfully employed, beautifully crisp pictures of cellular structure seldom, if ever, equalled by carmine; its applicability in its usual formulæ, however, is limited to staining sections, since its powers of penetration are feeble. This latter defect may be overcome by employing the stain in the form of *Delafield's hæmatoxylin*, given below, which answers admirably for bulk-staining. The liability to fade, the possibility of overstaining, and the necessity of using water for differentiation are among the disadvantages of hæmatoxylin as usually employed.

The student is strongly advised to *adopt carmine as his staple stain*, reserving hæmatoxylin as a valuable, and sometimes indispensable, supplementary means of bringing out parts of cells not satisfactorily displayed in carmine preparations.

In the order of procedure given above, staining follows the preser-

vation of the tissue and precedes the embedding and sectioning, this arrangement being based on the supposition that the tissue is to be stained in bulk and cut in paraffin: with this sequence in view, the specimen is removed from the 80 per cent. spirit and placed *directly* in the staining solution, which, for all the ordinary purposes for which carmine is employed, is best made up as:

a. Borax-Carmine (*Grenacher*).

Carmine, best	2.5 gm.
Borax	4.0 gm.
Water	100 c.c.
Alcohol (70 per cent.)	100 c.c.

The carmine and borax are thoroughly rubbed up in a mortar and dissolved as far as possible in the previously-heated water, the alcohol being subsequently added. The fluid may then be filtered, but it is preferable not to do so; the solution is set aside for at least two weeks, and then carefully decanted.

The exact length of time required to stain sufficiently a block of tissue throughout evidently depends upon the size and density of the specimen; it is, however, seldom safe to trust to an immersion of less than 24 hours' duration, and if the object be of large size and compact texture, say a piece of kidney 2 cm. in thickness, it should be allowed to remain in an ample quantity of the stain for at least three days. The vessel containing the fluid and tissue must be well stoppered, a wide-mouthed bottle or tightly-covered capsule being the most suitable receptacle.

From the carmine the tissue is directly transferred, *without the slightest washing in water*, into a large quantity of *acid alcohol*, made by adding strong hydrochloric acid to 70 per cent. alcohol in the proportion of *5 drops of acid to every 100 c.c. of spirit.* The object of the acid solution is to effect *differentiation* and *fixation* of the color; for this purpose the tissue should remain *at least 24 hours*, and, if of the size and character above supposed, twice as long—until the frequently-changed acid alcohol no longer becomes tinged. If the staining has been successful, the block of tissue now appears of a brilliant deep uniform red; if inspection shows inequality of tint or insufficient color in the central parts of the mass, the staining will not be satisfactory and should be repeated. Failure in bulk staining is due to an unfavorable condition of the tissue or to an improperly-prepared staining fluid, and not to the method, which extended experience shows is always capable of yielding the most gratifying results, whose brilliancy and differentiation compare favorably with those of any carmine staining of individual sections.

Where it is preferable to stain the sections *after cutting*, the same

carmine fluid may be employed, the sections, either loose or fixed to the slide, being immersed from 15 to 20 minutes, and then directly transferred to 10 per cent. acidulated 70 per cent. alcohol for about 5 minutes, followed by thorough washing in 70 per cent. spirit. Where the tissue is robust, the acid solution for differentiation and fixing may be made with water in place of the alcohol, water being also used for the subsequent washing; it is an advantage, however, for delicate structures to avoid transfers from alcohol to water, keeping as far as possible the sections in alcoholic solutions of about the same strength.

b. Delafield's Hæmatoxylin.

(1) Hæmatoxylin, crystals	4 gm.
(2) Alcohol, absolute	25 c.c.
(3) Ammonia-alum, crystals	52 gm.
(4) Water	400 c.c.
(5) Glycerin	100 c.c.
(6) Methyl-alcohol	100 c.c.

Dissolve 1 in 2, and 3 in 4; mix, when a slightly-colored fluid is produced; let stand for 4 days, protected from dust, but with free access to air and light, at the end of which time the fluid has turned to a deep bluish purple. Filter, and add 5 and 6; a part of the ammonia-alum falls out in small crystals. After several hours filter again, and then keep in a tightly-stoppered bottle at least four or five weeks before using.

This tediously-prepared stain possesses the great advantage of penetrating and staining well tissues in bulk, for many purposes being a valuable adjunct to carmine staining. The strong solution above given is diluted with distilled water, and the tissue allowed to remain until of a very dark blue color, when it is placed in distilled water for 24 hours to effect differentiation and remove excess of color; it is then transferred to 70 per cent. alcohol for subsequent treatment. The action of the stain must be watched, as overstaining may readily occur; should the coloring be too intense, this may be remedied by soaking in dilute hydrochloric acid, the action of the latter being arrested at the proper time by water, which at the same time restores the tissue to its former blue color, the acid having previously turned it reddish or brown. It is very important to *remove every trace of acid*, to prevent subsequent fading; to this end thorough washing after the use of acid is imperative. An avoidance of overstaining in the first place is much more desirable than any subsequent correction. In addition to the purposes of staining in bulk, this hæmatoxylin fluid works well after fixation in chromic acid or Flemming's solution, yielding excellent preparations of chromatin filaments in such tissues.

c. Alum-Hæmatoxylin (*Böhmer*).

(1) Hæmatoxylin, crystals	.35 gm.
(2) Alcohol, absolute	10 c.c.
(3) Potash-alum	.10 gm.
(4) Water, distilled	30 c.c.

Dissolve 1 in 2 = A ; dissolve 3 in 4 = B ; A is added to B, drop by drop, and allowed to stand in the light for several days before filtering.

For staining sections, dilute with *distilled* water, several drops of the stain to a watch-glass of water usually producing the requisite rich bluish-purple solution. The sections remain in the diluted stain until colored dark *blue*, this usually requiring 5–8 minutes, although the exact time depends upon the condition of the tissue and the strength of the staining fluid employed ; the sections are transferred to distilled water and allowed to soak from 5 to 10 minutes, by which time they have become a bright rich blue ; a too intense color and a light lilac tint are alike to be avoided.

The tissue having been stained in bulk with either borax-carmine or Delafield's hæmatoxylin, it is now ready for the important manipulation of embedding.

4. **Embedding.** This may be *simple* or *interstitial*, the former affording a general support to the tissue by grasping its surface without penetrating the tissue, the latter supporting not only the surface, but also, in consequence of the complete infiltration of the specimen, every part of the object. For the purposes of hasty examination, the simple embedding often answers perfectly, and is preferable on account of economy of time and labor ; where, however, really fine preparations are desirable, the additional labor involved by the more elaborate process is amply repaid by the character of the resulting preparations.

The most satisfactory *mass for simple embedding* consists of paraffin 2–3 parts + tallow 1 part ; the melted mass is poured around the piece of tissue, which has been previously fixed in position by a carefully-inserted pin within a paper mould. The mass should *cool slowly*, and the sections should be cut with both *knife and block flooded with strong spirit.*

Interstitial Embedding, by which every portion of the entire tissue-mass is held together and sustained, each isolated fragment being retained in its relative position and preserved in the mounted preparation, has given the histologist of to-day a command of his tissues incomparably superior to anything that his predecessors possessed, and enables him to secure complete series of objects whose minuteness and frailty precluded perfect preparations by the older methods.

The important processes of interstitial embedding are two, *paraffin* and *celloidin* being the substances respectively used to infiltrate the tissue; of these the paraffin method must be regarded as the most perfect, and, with few exceptions, to be preferred *whenever thin perfect sections* are of importance, especially where preservation of *sequence* is desirable.

Paraffin Method (*Klebs*).

The essential point of this process is *thorough and complete impregnation* of the tissue with the embedding mass; it is consequently necessary *to saturate the tissue* with some fluid with which the paraffin is perfectly miscible, the fluids usually employed to this end being chloroform or turpentine oil; in order, however, to insure the free entrance of these fluids within the tissue, it is first necessary to free the tissue of all traces of water still contained in the alcohols of 70 or 80 per cent. It is, therefore, necessary to place the tissue from the usual 80 per cent. preserving spirit as follows:*

a. Into *95 per cent. alcohol* from 12 to 24 hours.

b. Into *absolute alcohol* from 24 to 48 hours, until *complete dehydration* has been secured; this step is of the *utmost importance* for the success of all the subsequent manipulations, since if dehydration be imperfect infiltration will be unsuccessful, and the tissue will cut badly.

c. Into *pure chloroform* from 6 to 8 hours, or until the chloroform has replaced the absolute alcohol; an indication of the completion of this interchange is furnished by the position of the tissue, since as soon as the tissue continues to lie *beneath* the surface of the chloroform, or *sinks* towards the bottom of the bottle, it may be concluded that the alcohol has been completely replaced by the chloroform.

d. Into a saturated solution of *paraffin in chloroform* from 2 to 3 hours; the solution may be kept slightly warmed.

e. Into *pure melted paraffin*, which has a melting-point of about 50° C.; the paraffin is best contained in a small open porcelain capsule placed within a water-oven so regulated as to maintain a constant temperature of about 50° C.: while undesirable, congealment of the surface of the paraffin due to reduction in temperature is no great misfortune, the retarded evaporation of the chloroform being the principal evil; a rise of the temperature to which the tissue is subjected to a point beyond 55° C., on the contrary, is usually disastrous, the tissue being shrunken and distorted to a degree which renders it valueless. It is, therefore, desirable to keep the paraffin and the

* In the appended data it is still assumed that the tissue being treated is of the consistence and volume represented by a piece of kidney 2 cubic cm. in size.

tissues at a temperature whose variations are included within the limits of 50° to 52° C.

The tissue must remain in the melted paraffin until every portion of it has been *completely filled with the embedding mass* and all the chloroform has been driven off. This latter point is a matter of importance in insuring the proper consistence of the paraffin for satisfactory cutting, since when the paraffin contains traces of chloroform it is too soft and friable to yield the best results. In order to determine whether all the chloroform has been driven off, a clean thin iron rod is heated and plunged into the melted paraffin, care being taken that the rod is not too hot when immersed, lest the tissue be overheated. So long as traces of chloroform are present, bubbles follow the introduction of the heated rod; when *bubbles no longer appear*, all the chloroform has been driven off.

After the complete dissipation of the chloroform, the tissue is transferred for a few minutes to a second capsule containing fresh, unused, melted paraffin of such consistence as is best adapted to sectioning under the conditions of season and particular object in view; the quantity of melted paraffin should amply suffice to fill the mould which is to be employed in the next manipulation.

f. *Embedding the Tissue.* For this purpose some form of *mould* must be devised, which may be the simple paper box, made by folding over a block the sides and ends of a piece of sized paper some 4 cm. wide by 8 cm. long; more convenient are the adjustable metallic embedding frames furnished by dealers, those made by Jung, of Heidelberg, and sold by various firms in this country, being particularly serviceable. When the paper box is used, it should be fixed to a loaded cork before the paraffin is poured into it; when the metallic frame, it must closely rest upon a piece of polished glass. In either case, the mould is placed in a broad dish, whose depth somewhat exceeds the height of the sides of the mould when resting in position for use.

The mould and dish being ready, the capsule containing the fresh paraffin and specimen is removed from the oven, and the paraffin poured at once into the mould, which should be completely filled; after this has been done, the tissue is seized lightly with the *slightly-warmed forceps*, and rapidly transferred to the mould; a warm needle should be at hand with which to arrange the tissue, so that the proposed plane of section shall lie parallel to one of the smaller ends of the mould, while its principal axis corresponds with the bottom upon which the tissue rests.

As soon as the specimen is properly placed—and this is often a matter of great consequence—steps should be taken to harden the paraffin *as rapidly as possible.* To this end, the dish supporting the

mould and specimen should be filled with cold water until the latter is just *on the point of overflowing* the sides of the mould, great care being taken that this does not happen *before* the surface of the enclosed lake of melted paraffin has congealed, otherwise the paraffin becomes partially displaced by the water, which will be found later within large cavities in the block.

As soon as the film on the surface has completely formed, the water is allowed to cover the mould entirely; the dish may then be placed under the tap, and a *gentle* stream of water aid in cooling off the mass. No attempt should be made to remove the block from the mould until the entire mass has become *thoroughly hardened;* when this has occurred, and the embedded object with its surrounding mass has been freed, the paraffin should appear *almost transparent* and of a bluish tint, and *not* milk-white, as is usually the case when the paraffin is impure or when the block has been cooled slowly. After trimming off the superfluous embedding material and exposing the surface to be sectioned, the tissue is ready for cutting. Objects may be preserved within the paraffin indefinitely, the method affording an admirable and convenient means of keeping tissues for any length of time and always ready for immediate sectioning and mounting.

Celloidin Method (*Duval-Schiefferdecker*).

This method has but one point in common with the paraffin process —the tissue is infiltrated with the embedding mass; while paraffin is cut dry, celloidin must be cut under or flooded with spirit. Celloidin is particularly adapted for certain lines of work in the central nervous system and the special senses, and possesses the advantages over paraffin of requiring less attention and no heat for its successful manipulation. The retention of the supporting mass, the rather thicker sections, and the impossibility of cutting ribbon-series, on the other hand, are points of unfavorable comparison with the paraffin method.

The celloidin should be prepared as two solutions, a *thin* and a *thick:* the celloidin—either as chips or in cake—is dissolved in *equal parts of absolute alcohol and ether*, about 5 grammes, in small pieces, being placed in 100 c.c. of the mixed solvent; the resulting solution will be very thin, and may be labelled "A"; a second solution should be made containing enough celloidin to secure the consistence of a thick syrup; this is "B." The celloidin does not dissolve with great readiness, days often being required for the preparation of the solutions; these should be very carefully *guarded against evaporation*, and a small quantity of the absolute alcohol and ether added from time to time to maintain the proper degree of fluidity.

The tissue, previously *thoroughly dehydrated* by absolute alcohol, is soaked in a mixture of equal parts of absolute alcohol and ether

from 24 to 48 hours and then transferred to the "A" or thin celloidin solution, in which it remains for several days, until *entirely permeated* with the mass; the tissue is then placed in the thick "B" solution, where it stays until the thinner fluid has been replaced by the thicker. Meanwhile, corks of suitable size should be soaking in the mixture of equal parts of absolute alcohol and ether; one of these is selected, its end slightly roughened, and finally moistened with a few drops of the mixture just before the tissue with an envelope of the thick celloidin solution is placed in position for cutting on the cork, care being taken that the stratum (1–2 mm.) of celloidin lies between the tissue and the cork. After a few moments a fresh layer of celloidin is added, and this process is repeated until the tissue is *completely surrounded* with a stratum of the embedding mass; or the tissue may be completely embedded, after being attached to the surface of the cork, by fastening a piece of writing-paper to the sides of the cork and at once filling the resulting mould with the fluid celloidin. The mass of fresh celloidin should remain undisturbed until the surface has hardened sufficiently to prevent all possibility of shifting, when the cork with the tissue is transferred to a vessel containing *75 per cent. spirit* to harden, where it remains, *completely immersed*, from 1 to 3 days or longer; at the expiration of this time the block has gained a consistence suitable for sectioning. The cutting can be done either free-hand or by the microtome, but it must be done while both knife and tissue are flooded with 70 per cent. alcohol. The sections are transferred to 70 per cent. spirit for subsequent treatment; if already stained, they are passed into 95 per cent. for dehydration, cleared in xylol, bergamot oil, or cedar oil (but *not in clove oil*, as this dissolves the celloidin), and mounted in balsam; if, on the other hand, the tissue has not been stained in bulk, the sections are treated with the selected stain, alcoholic or aqueous, and subsequently dehydrated, cleared, and mounted.

5. **Sectioning.** While for the purposes of immediate examination or of temporary preparation free-hand sections often suffice, yet no one seriously undertaking histological investigation can afford to ignore the advantages possessed by the approved microtomes of the present day, without which accurate work is impossible. After an extended experience with many forms of these instruments, the writer unhesitatingly recommends the sliding microtome, as made by Schanze, of Leipsic, as the best all-round instrument to be had, the medium-sized "model B" of this maker supplying an ideal tool capable of executing all forms of cutting in the most satisfactory and convenient manner. The little sliding student's microtome made by the Bausch and Lomb Optical Company answers as a very satisfactory

substitute for the more convenient and accurate foreign instrument. A word of caution may be added against regarding all forms of sliding microtomes as equally efficient, since the satisfactory working of such tools is largely dependent upon details of their construction and workmanship. While theoretically more accurate, the beautifully-made Thoma microtomes with the "Naples" holder are much less convenient than the Schanze instruments, and are less desirable than the latter for general use. Where much ribbon-cutting is carried on, the Minot automatic microtome will be found a most valuable time- and labor-saving device; equally perfect ribbon-series can be produced on the Schanze, but with much less rapidity.

Assuming that some satisfactory form of sliding microtome is at command, and that the tissue has been embedded interstitially in paraffin, the method employed in cutting will depend on whether isolated sections or a series are desired. For very many purposes the separate sections are all that is needed, their relative position and sequence being preserved by systematic arrangement as they are cut. In making such individual sections, the *knife should be placed obliquely* to the tissue, the exact angle being such that the *entire length* of the blade is successively brought into use. It will be found necessary to adopt some means of preventing the rolling up of the sections as they are cut, this tendency being especially pronounced with the harder grades of paraffin; after this has occurred, the sections are usually useless. The simplest and most effective means of overcoming this difficulty is to hold a *small red sable brush* over the edge of the knife, and, as the latter enters the block, lightly hold the section as it is being cut from curling over and rolling up; the manipulation requires some little dexterity, but when once acquired supplies a simple "section smoother" equally as efficient as any of the more elaborate mechanical devices. In cutting paraffin sections, *no fluid* is needed, *both block and knife being kept perfectly dry*. The knife should be wiped occasionally with a clean cloth, to remove any particles of the embedding mass that may adhere; especial attention must be given to the edge and under surface of the blade, as sometimes a minute adherent fragment will cause cracks across the entire surface of the subsequent sections. The forceps or a brush serve to transfer the sections from the knife-blade to the adjacent tray lined with perfectly clean paper, upon which the sections may remain for a long time if properly guarded against high temperature and dust. The average thickness of satisfactory paraffin sections is about .01 mm.; large sections are usually somewhat thicker, small delicate objects, as embryos, readily yielding sections not much over half as thick (.005 to .008 mm.); it should not be forgotten that a keen blade and proper paraffin are essential to first-class results.

In cutting celloidin or other specimens requiring to be flooded while sectioned, the knife is likewise placed obliquely; the sections are removed with a soft wet brush and transferred to alcohol; rolling up of such sections does not occur.

Cutting ribbon-series is a modification of the usual procedure, and possesses great advantages where the possession of a complete series of sections arranged in their natural sequence is important; not only for embryological studies, where it has become a necessity, but for many other purposes, ribbon-cutting is to be preferred. The success of the manipulation depends largely upon the *proper consistence of the paraffin*, since the latter must be of just such hardness that while firm enough to enable the sections as cut to push before them those already in the chain, it must be sufficiently soft to enable the opposed edges of the sections to adhere together, and thus form the "ribbon." Preparatory to cutting the paraffin block is trimmed as accurately as possible into rectangular form, and so clamped in the microtome that the longer sides of the rectangle are *exactly parallel to the edge of the transversely-set knife*, the latter being placed at *right angles to its slide-ways*.

When the first section is cut it is *not removed*, but allowed to lie upon the blade; the knife being returned to its first position, the tissue is raised the proper distance (generally .01 mm.), and a second section is made, which, if the paraffin is of the proper character, will adhere to the first, while the latter is pushed ahead for a distance equal to the second section; in this manner each section in turn drives those previously cut before it, all adhering by their opposed edges and forming a ribbon whose length is often limited only by the wishes and the convenience of the worker. Care must be taken to keep the cutting edge, especially its under surface, free from particles of paraffin, since the presence of these will lead to furrows and cracks in the sections. The sides of the block corresponding to the knife-edge must also be kept *exactly parallel*, otherwise the ribbon will be curved instead of straight. In case the paraffin in which the tissue lies is too hard, the sections breaking apart instead of adhering, elevating the temperature of the workroom or judiciously holding the block in the vicinity of a flame for a short time will usually afford relief; or the entire block may be coated with softer paraffin, which is subsequently trimmed off from all but the two adhering sides. As the ribbons are completed they are placed in covered trays upon clean sized paper, protected from dust and high temperature.

6. **Fixing sections to the slide** constitutes the next step after cutting when tissues have been embedded in paraffin, whether pre-

viously stained or not; the object of the manipulation is to replace the support afforded by the paraffin by attaching the sections to the slide *before removing the embedding substance.* In this point paraffin is much more accurately and conveniently worked than celloidin, since the latter is removed from the sections with much less facility than paraffin. The ideal fixing solution is yet to be devised, those at present employed being all defective in some particular. The desiderata are *secure attachment* of the sections to the slide in all solutions necessary for the various manipulations of staining and mounting, and *complete expansion* of the sections before their final adhesion to the slide: this latter consideration is of great importance in large sections or in mounting ribbon-series, since it is practically impossible to cut these without some slight compression or wrinkling; if mounted without being *perfectly expanded*, the preparations are marred by distorting folds, which in lines of accurate work, where reconstructions are sometimes necessary, are serious defects. The most satisfactory fixing solutions are the **gum arabic** (*Flögel-Schultze*) and **collodion-clove oil** (*Schällibaum*) mixtures.

The **gum-arabic method** is carried out as follows: of a *saturated aqueous solution* of best gum arabic (a crystal of thymol being added to prevent the growth of fungi) about *12 drops are added to 30 c.c. of distilled water* and thoroughly shaken. The *slide is flooded* with the solution, care being taken that the fluid does not run over the edges, and the *sections are floated on the liquid*, every part of the sections being separated from the slide by the stratum of solution: when all the sections are arranged, the slide is transferred to a warming-plate and *very gently heated* to a temperature *never* as high as the melting-point of the paraffin, the object being to enable the sections *to expand while swimming on the gum solution;* this they do in a most satisfactory manner within a few minutes, the sections spreading out perfectly flat even when previously wrinkled.

After expansion the excess of the fluid is drained off, and, if necessary, the sections finally rearranged; the slides are then placed in a suitable place to dry, where evaporation is favored but protection from dust is afforded. It usually is best to allow the sections to lie overnight to insure complete drying, as if water be still present the sections will not properly clear up.

The disadvantages of the method are the long time required to insure complete evaporation of the fluid and the inability of sections so fastened to withstand watery solutions, which dissolve the gum and loosen the sections. These objections, however, are more theoretical than real, and are more than compensated by the superior preparations secured by this method; in the exceptional cases where it is necessary to apply aqueous solutions, advantage may be taken

of the modification introduced by Gray, who uses a weak gelatin solution in place of the gum arabic, and, after the sections have expanded and are fastened in their proper positions, soaks the slide in a very weak solution of potassium bichromate, which, in the presence of light, renders the gelatin film insoluble in water, and hence capable of resisting aqueous stains. To those desiring accurate preparations, these methods are strongly recommended as preferable to the more rapidly applied and generally used

Collodion and Clove-Oil Mixture. This is made by adding 1 part of collodion to 3 parts of clove oil; the mixture should be made up in small quantities, as it becomes less reliable with age. The slide is lightly painted over with the mixture and the paraffin sections placed in position; the sections cannot be moved after touching the mixture, hence care must be exercised in their placing. When the slide is full, it is *gently warmed until the fumes of the clove oil appear;* meanwhile the paraffin melts and the section sinks down into the film of the mixture, from which the clove oil is driven off, leaving the tissue attached to the slide by the film of collodion alone; this union is not attacked by any of the aqueous, alcoholic, or other solutions ordinarily used. The ability of resisting many fluids, together with its simplicity and rapidity, has long rendered the method a favorite, and, for very many cases, deservedly so, due care being exercised in heating the slide to avoid injury to the tissue. In spite, however, of these considerable advantages, the inability of securing perfect extension of the sections is a shortcoming which for accurate investigations is fatal; when, therefore, accurate preparations are desired, it should be discarded for the gum or the gelatin method. The sections being securely fixed to the slide by one of the foregoing methods, the paraffin on the slide must be removed, as preliminary to—

7. **Mounting** the sections for preservation. The paraffin is best removed by immersing the slide in benzole or xylol for a few moments and then transferring to turpentine for a short time. The sections having cleared up in these fluids are ready for the application of the mounting medium, the balsam. The slide is removed from the turpentine, drained, and hastily wiped on the back and edges, care being taken not to touch the sections; a drop of pure balsam is then placed on the centre of the slide and the latter held for a *few moments* over a spirit flame to liquefy more thoroughly the balsam, when the cleaned cover-glass, previously caught by the forceps and passed for a moment over the spirit flame, is lowered into position; this manipulation should be executed with steadiness and evenness, avoiding as far as possible the imprisonment of air-bubbles. Should these, however, appear after the cover is in place, they need

cause no concern, as they usually spontaneously disappear during the next twelve hours unless imprisoned within some enclosed recess of the tissue; rough treatment, by strongly and repeatedly pressing on the cover-glass in the attempt to displace air-bubbles, is disastrous to thin sections, and should never be practised; *gentle pressure*, however, should be made after the cover is down, to press out superfluous balsam, but this must be done with care and judgment. The balsam should entirely fill up the space beneath the cover and form a slight border outside; this edging of balsam is useful, as it dries much sooner than the medium beneath the cover and adds very materially to the strength of the preparation.

The freshly-mounted slides should be placed in the horizontal position and allowed to dry some days before being much handled, although if necessary a preliminary study of them can be made at once. No attempt should be made to clean them until the balsam has well hardened and all danger of moving the cover-glass disappeared; the excess of the mounting medium is then removed with a sharp knife and the slide finally cleaned by a cloth moistened with benzole.

8. **Finishing, labelling, and storing** the slides depend largely upon the individual taste and wishes of the worker; while the earnest investigator has little time for useless ornamentation, the small amount of labor involved in having slides clean, neat, and properly labelled is well compensated by the convenience and satisfaction of handling such preparations. Labels should always be attached as soon as practicable, and should indicate *all* data likely to be of interest; when labels are placed on both ends of the slide, one should be reserved for noting points of especial interest shown by the preparation. In preparing slides on which an entire series is mounted, marking each with a diamond saves much vexatious delay, which otherwise is often experienced in determining the proper sequence. Finished preparations are best preserved in some form of cabinet or case, the exact character of which is of little consequence so long as the slides are protected from dust and light and lie flat; cabinets with well-made drawers are attractive and convenient, but usually expensive.

In recapitulation of the foregoing manipulations, already considered in detail, the steps necessary to convert the fresh tissue into the finished preparation may be presented as

AN OUTLINE OF THE STANDARD METHOD.

1. Fixation of fresh tissue in large quantity of Müller's fluid; renewal when turbid; tissue remains 2–3 weeks.
2. Thorough washing in running water—2–5 hours.

3. Transfer to 70 per cent. alcohol; keep in dark; change alcohol whenever it becomes deeply tinged, until it remains colorless.

4. Stain in excess of borax-carmine—24–48 hours.

5. Transfer directly, without washing, from stain to acid alcohol —24–48 hours.

6. Wash well in 70 per cent. alcohol, several times renewed—24 hours.

7. Transfer to 80 per cent. alcohol—24 hours.

8. Transfer to 95 per cent. alcohol—24–48 hours.

9. Dehydrate in absolute alcohol—24–48 hours.

10. Transfer to pure chloroform until tissue sinks—6–8 hours.

11. Transfer to saturated solution of paraffin in chloroform—6 hours.

12. Transfer to pure melted paraffin, kept at constant temperature of about 50° C., until all chloroform is driven off—6–8 hours.

13. Transfer to fresh melted pure paraffin of consistence for embedding—10–15 minutes.

14. Embed tissue in mould; cool rapidly.

15. Section in microtome, first suitably trimming block for cutting.

16. Fix sections to slides by gum or collodion-clove oil.

17. Remove paraffin by benzole, succeeded by turpentine.

18. Drain off excess of turpentine, apply balsam, and cover.

19. Place freshly-mounted slides in horizontal position.

20. Clean up and permanently label when thoroughly dry; store in suitable cabinet.

While the duration of the several manipulations as indicated in the above summary represents the time usually required by ordinary objects, yet the individual character of the tissue must be considered in each case, as density exerts much influence on the rapidity with which the fluids penetrate.

When it is desirable to stain the tissue *after* sections have been cut, the above manipulations must be modified; steps 4, 5, and 6 in such case are omitted and the tissue is at once dehydrated. Removal of the paraffin from the fixed sections on the slides (17) by benzole is at once succeeded by the following manipulations:

a. Transfer to 95 per cent. to remove the benzole—5–10 minutes.

b. Transfer to clean 95 per cent. alcohol to insure complete absence of benzole—5 minutes.

c. Transfer to 80 per cent. alcohol—5 minutes.

d. Transfer to 70 per cent. alcohol—5 minutes.

e. Stain in borax-carmine solution—10–15 minutes.

f. Differentiate in acid alcohol (10 per cent.)—6–10 minutes.

g. Wash in 70 per cent. alcohol, renewed—10–15 minutes.

h. Transfer to 80 per cent. alcohol—15 minutes.

i. Transfer to 95 per cent. alcohol—15 minutes.

j. Dehydrate thoroughly in absolute alcohol—15 minutes.

k. Clear sections in oil of turpentine—5 minutes.

l. Mount in balsam as indicated above in 18.

When *hæmatoxylin* is used as the stain, the steps **e, f,** and **g** are omitted and replaced by—

ee. Transfer to distilled water—5 minutes.

ff. Stain in properly-diluted hæmatoxylin fluid until sufficiently dark—8–10 minutes.

gg. Wash well in distilled water to remove excess of stain and to differentiate—10 minutes; then dehydrate by the ascending series of alcohols included by **h** to **j** as above.

The foregoing methods are those to be employed as the standard processes, since for the great majority of specimens they yield results perfectly satisfactory and trustworthy; sometimes, however, special lines of investigation demand other treatment in order to bring out particular features. Several of those most important for the study of the nervous system are here given.

Weigert's hæmatoxylin method is of great value in exhibiting the presence and course of *medullated* nerve-fibres on account of the peculiar staining of the medullary substance; the method takes advantage of the tenacity with which this part of the nerve-fibre retains the color, appearing slate-blue or black, while the other parts of the nervous tissues become pale; the tissue is first overstained and then decolored.

The fresh spinal cord or the brain is hardened in a large excess of potassium bichromate (5 per cent. solution), repeatedly renewed, for several weeks, and then directly transferred to 80 per cent. alcohol, kept in the dark, and frequently changed until the fluid is no longer discolored; as the tissue is usually cut in celloidin, the next step is the dehydration by 95 per cent. and absolute alcohol, followed by the usual process of the celloidin embedding. After this has been accomplished, and the tissue is on the cork ready for cutting, the entire block is transferred to—

a. Saturated solution neutral cupric acetate . . . . . 1 part;
Solution of Rochelle salt (10 per cent.) . . . . . 1 part,

for 24 hours in oven at 40° C.

b. Transfer to—

Saturated solution neutral cupric acetate . . . . . 1 part;
Distilled water . . . . . 1 part,

for 24 hours.

c. Transfer to 80 per cent. alcohol—½–1 hour.

d. Cut sections; knife and tissue wet with 80 per cent. alcohol.

The later method of Weigert directs the preparation of the following staining solutions:

A	Lithium carbonate (1.2 gm. : 100 c.c. H_2O)	7 c.c.
	Distilled water	100 c.c.
B	Hæmatoxylin, crystals	1 gm.
	Absolute alcohol	10 c.c.

e. Stain sections for 12 to 24 hours in mixture composed of 9 volumes of A + 1 volume of B.

f. Wash thoroughly in distilled water.

g. Transfer to 90 per cent.—15 minutes.

h. Transfer to 95 per cent.—15 minutes.

i. Transfer to anilin oil-xylol (anilin oil 2 vol. + xylol 1 vol.)—5 minutes.

j. Transfer to pure xylol—5 minutes.

k. Mount in balsam.

The exact degree of color must be determined by experience and the individual taste of the worker; the Weigert method in any of its forms is a stain particularly for the *medullated nerve-fibres*, the cellular elements being better displayed by carmine or other hæmatoxylin dyes.

Cox-Golgi method for displaying the nerve-cells of the central nervous system possesses the advantages of simplicity and relative certainty over the older silver impregnation methods of Golgi. Small pieces of nervous tissue, not over from two to three centimetres cube, are placed in a mixture composed of—

Solution of potassium bichromate (5 per cent.)	20 c.c.
Solution of corrosive sublimate (5 per cent.)	20 c.c.
Solution of potassium chromate (5 per cent.)	16 c.c.
Distilled water	44 c.c.

and allowed to remain until ready for cutting, the fluid being changed after the first, third, and seventh days, and subsequently each week for a month, if necessary. When ready for sectioning, the tissue is transferred directly to 95 per cent. alcohol for two hours and then embedded in celloidin by successive treatment with alcohol-ether, thin and thick celloidin solutions. After cutting, the sections are cleared in a mixture of—

Xylol	3 parts,
Phenol	1 part,

and mounted in balsam; cover with cover-glass.

Even in successful preparations only a limited number of cells will be well shown; this, however, is rather an advantage than otherwise, since diagrammatic pictures are obtained of the various elements in turn. The method is an impregnation, not a true stain, defining outline, but not histological structure. The method is also applicable to the demonstration of minute canals, as the bile capillaries and glandular ducts.

Golgi's gold method is useful for displaying naked axis-cylinders and ultimate nerve-fibrillæ, as well as special nerve-endings: the method possesses the advantage of being relatively certain and rapid in its action, especially if the reduction be facilitated by heat.

Soak the *fresh* tissue in—

a.

Arsenious acid	.5 gm.
Water, distilled	100 c.c.

until it becomes *translucent*—usually 15–25 minutes.

b. Transfer to—

Gold chloride	.5 gm.
Water, distilled	100 c.c.

for 25 to 45 minutes; rinse off in distilled water.

c. Transfer to *1 per cent. arsenious acid solution* and expose to sunlight until reduction follows and the tissue appears of a deep purple or red color; this reduction may be hastened by gently heating over water-bath for some 10 to 15 minutes, until the tissue becomes deeply colored.

d. Wash thoroughly in water.

e. Transfer to alcohol for dehydration, or to 50 per cent. glycerin, as the case may demand respectively for balsam or glycerin mounting.

Silver staining is an important means of bringing to view the boundaries of epithelial and endothelial cells by the deposit of reduced silver particles within the intercellular cement-substance; in the typical silver staining only the cell boundaries are shown as dark brown or black lines, the protoplasm being almost colorless. In intensely stained specimens of very fresh still living tissue the protoplasm and nuclei are sometimes colored. The silver method also tinges the interfibrillar ground-substance of dense connective tissue, bringing to view the cell-spaces as clear areas within a colored field.

The *absolutely fresh tissue* is carefully rinsed in *distilled water*, without rubbing the surfaces, and then transferred to .5–1 per cent. solution of silver nitrate from 2 to 10 minutes, depending on the thickness of the object; the then milky tissue is washed and exposed

in *distilled water* to sunlight in a porcelain dish until it becomes dark brown; the reduction is arrested, when sufficiently advanced, by thorough washing in water to which a few grains of sodium chloride have been added. The stained tissue may be mounted either in glycerin or in balsam, soaking in dilute and later strong glycerin, or dehydration and clearing, being the subsequent respective manipulations.

Staining chromatin filaments for the display of karyokinetic figures and other studies of cell-structure can be successfully carried out only after *accurate fixation* of the cells, for which purpose the stronger Flemming's solution will be found most trustworthy.

The tissue after such treatment is embedded in paraffin and cut, the fixed sections on the slide being subsequently stained by saffranin or by Delafield's hæmatoxylin. When karyomitosis is the especial object of study, preparations made by stripping off the epidermis of suitable animals (*very young* larval newts being excellent) are more favorable than sections, as the cells are preserved intact and contain the entire chromatin figures, and not merely the parts included within the planes of the section. Place small pieces of such tissues in—

a. Saffranin . . . . . 2 gm.
Alcohol, 50 per cent. . . . . 60 c.c.

24–48 hours.

b. Wash off in water for a few moments.

c. Transfer to *acidulated absolute alcohol* (10 drops of pure hydrochloric acid to 100 c.c. of absolute alcohol) for a few moments (½–1 minute) until the clouds of color cease to be copiously given off; then—

d. Transfer to fresh absolute alcohol for 1 to 2 minutes.

e. Clear in clove oil and mount.

Care must be taken not to remove too much color by prolonged action of either the acidulated or the plain absolute alcohol, since the preparation can be almost entirely bleached by inattention to this point. In a successful preparation the chromatin figures are brilliantly stained of a bright red, while the other parts of the cells are almost uncolored.

Injection of capillary blood-vessels requires considerable experience, and at best an element of uncertainty enters into every attempt, since the condition of the tissues, particularly of the vessels, largely influences the manner in which the fluid runs. While *carmine-gelatin* injections make very attractive pictures, a successful *blue* mass possesses many advantages when used in connection with

carmine solutions. One of the most convenient and efficient injecting fluids is—

Soluble Berlin blue (*Grübler*)	3 gm.
Distilled water	600 c.c.

This fluid runs well, does not extravasate, and may be *used cold;* perfectly fresh animals, immediately after killing, are the most favorable subjects for the manipulation. A smoothly-working *hand-syringe* (200–300 c.c. capacity), with appropriate stop-cock and canulæ, is the best instrument, since the educated hand of the operator forms the best judge of the amount of pressure that may safely be applied. When the injection is completed the vessels should be ligated and the tissue placed in 70 per cent. alcohol or Müller's fluid for fixation and subsequent hardening. In the case of the lungs, after injecting the blood-vessels, the tissue should be moderately distended by forcing the preserving fluid into the organ through the air-tubes.

In conclusion, it may be repeated that the object in appending these pages treating of microscopic technology is to present in detail a few methods which will be found satisfactory and thoroughly trustworthy for the great majority of histological investigations. The student is urged to persevere with those here given until he has repeatedly carried the manipulations to a successful issue by producing the really beautiful results of which these methods are capable.

INDEX.

A.

Absolute alcohol, use of, 409.
Accessory digestive glands, 182.
  development of, 189.
Acervulus cerebri, 330.
Achromatin, 13.
Adenoid tissue, 118.
Adipose tissue, 43.
Agminated glands, 173.
Alum-hæmatoxylin (Böhmer), 414.
Amœboid movement, 12
Amphiuma, red blood-cells of, 108.
Aqueduct of Sylvius, nuclei of floor of, 304.
Arachnoid, 283.
  villi of, 283.
Areolar tissue, 40.
Arrector pili, 272.
Arterial glands, 114.
Arteries, 94.
  adventitia of, 96.
  intima of, 95.
  media of, 95.
  small, 97.
  structure of, 94.
Association fibres of cerebrum, 327.
Attraction-spheres, 14.
Auerbach, plexus of, 73.
Axis-cylinder, 73.
  processes, 70.

B.

Baillarger's stripes, 311.
Bartholin's glands, 237.
Basement-membranes, 137.
Berlin-blue injecting, 429.
Blastoderm, 23.
Blastodermic layers, 24, 25.
Blood, 105.
  elementary particles, 111.
  fibrin, 111.
  granules of Max Schultze, 111.
  hæmatoblasts, 111
Blood-cells, colored, 106.
  colored, human, 107.
  colorless, 105.
  division of, 112.
  effect of reagents upon, 108.
  origin of colored, 112.
  origin of colorless, 112.
  primary embryonal, 113.
  reproduction of colorless, 106.
  size of, 108.
Blood-crystals, 111.
  -islands of Pander, 103.
Blood-platelets, 110.
Blood-vessels, 94.
  capillary, 99.
  development of, 103.
  lymphatics of, 100
  nerves of, 100.
  perilymphatic clefts, 100.
Bone, 47.
  circumferential lamellæ, 48
  compact, 47.
  development of, 51.
  endochondral formation of, 52.
  ground lamellæ, 48.
  Haversian canals, 48.
  Haversian spaces, 54.
  Howship's lacunæ, 56.
  interstitial lamellæ, 48.
  marrow, 50.
  marrow-cavity, 48.
  osteoblasts, 55.
  osteoclasts, 56.
  perforating fibres of Sharpey, 50
  periosteal formation of, 54.
  periosteum, 49.
  red marrow, 50.
  spongy, 47.
  summary of development of, 56.
  varieties of, 47.
Borax-carmine (Grenacher), 412.
Brain-sand, 283, 330.
Bronchial tubes, 250.
Brunner's glands, 171.

C.

Canal of Schlemm, 351.
Capillary blood-vessels, 99.
Carmine staining, advantages of, 411.
Carotid gland, 114.
Cartilage, 44.
  cells, 45.
  development of, 47.
  elastic, 46.
  fibrous, 47.
  hyaline, 44.
  of bronchial tubes, 250.
  of Santorini, 248.
  of trachea, 249.
  of Wrisberg, 248.
  perichondrium of, 46.
  varieties of, 44.
Cells, embryonal, 11.
  goblet, 31.
  granule, 37

Cells, irritability of, 21.
motion of, 21.
pigment, 37.
plasma, 36.
typical, 12.
wandering, 36.
Cell-division, direct, 15.
indirect, 16.
Cell-wall, 12.
Celloidin method, 417.
Central nervous system, 282.
Centrosome, 14, 19.
Cerebellum, 304.
cells of Purkinje, 308.
granule layer, 305.
molecular layer, 309.
nuclei of the roof, 310.
white matter of, 310.
Cerebral cortex, blood-vessels of, 319.
pyramidal cells of, 312, 313.
stratification of, 311.
Cerebrum, 311.
association fibres of, 327.
claustrum, 320.
commissural fibres of, 327.
cornu Ammonis, 312.
corpus striatum, 319.
fascia dentata, 318.
fibre-tracts of, 326.
fifth ventricle, 319.
fimbria, 318.
hippocampus major, 315.
nerve-fibres of, 314.
nucleus caudatus, 319.
nucleus lenticularis, 320.
optic thalamus, 320.
peduncles of, 303.
projection fibres of, 327.
septum lucidum, 319.
white matter of, 326.
Ceruminous glands, 275.
Charcot's prostatic crystals, 222.
Choroidal fissure of eye, 373.
Chromatin, 13.
figures, staining of, 428.
Ciliary motion, 30.
effects of reagents upon, 31.
Claustrum, 320.
Clitoris, 237.
Coccygeal gland, 114.
Cœlom, 133.
Colostrum, 242.
Conarium, 329.
Connective tissue, 35.
arrangement of cells of, 38.
cellular elements of, 36.
development of, 42.
ground-substance of, 40.
juice-canals of, 39.
migratory cells of, 36.
mucoid, 40.
spaces of, 39.
varieties of, 35.
wandering cells of, 36.
white fibrous, 39.
Connective tissue, yellow elastic, 39.
Conus medullaris, 284.
Cornea, 336.
Corneal corpuscles, 338.
Corpora amylacea of brain, 330.
geniculata, 322.
mammillaria, 323.
quadrigemina, 321.
Corpus callosum, 327.
striatum, 319.
subthalamicum, 321.
Cowper's glands, 222.
Crescents of Gianuzzi, 141.
Crura cerebri, 303.
crusta of, 303, 304.
fibres of crusta, 327.
substantia nigra, 304.
tegmentum of, 303, 304.
Cutis anserina 272.

D.

Debove's endothelium of intestine, 169
Decidua, uterine, 233.
Delafield's hæmatoxylin, 413.
Demilunes of Heidenhain, 141.
Dentine, 51.
Derivatives of blastodermic layers, 25.
Direct cell-division, 15.
Duct, endolymphatic, 396.
galactophorous, 240.
Gartner's, 230, 245.
Müller's, 242.
of thyroid body, 257.
Wolffian, 204, 242.
Dura mater, 282.
nerves of, 283.
perivascular lymphatics of, 282.
venous sinus of, 282.

E.

Ear, 377.
accessory spiral ligament, 390.
ampullæ of semicircular canals, 387
auditory pit, 398.
auditory teeth, 391.
basilar membrane, 391.
canalis reuniens, 383.
cells of Claudius, 394, 395.
cells of Deiters, 394, 395.
cells of Hensen, 394, 395.
ceruminous glands of, 377.
cochlea, 388.
cochlea, blood-vessels of, 397.
cochlea, nerves of, 395.
cochlea, perilymph-spaces of, 396.
Corti's organ, 392.
crista basilaris, 389.
cristæ acusticæ of semicircular canals, 386.
development of, 397.
ductus cochlearis, 388, 389.
ductus endolymphaticus, 383, 396.
Eustachian tube, 382.
external auditory canal, 377.
external cartilage of, 377.
fenestra ovalis, 382.

Ear, hair-cells, 394.
hair-cells of maculæ acusticæ, 385.
internal, 383.
ligamentum spirale, 389.
maculæ acusticæ of, 384.
mastoid cells, epithelium of, 380.
membrana tectoria, 395.
membrane of Reissner, 389.
middle, epithelium of, 380
middle, glands of, 380.
ossicles, 381, 382.
otic vesicle, 398.
otolith-membrane, 385.
otoliths, 385.
pillars of Corti, 392.
prominentia spiralis, 390.
saccule, 383.
saccus endolymphaticus, 396.
secondary tympanic membrane, 381.
semicircular canals, 386.
spaces of Nuel, 395.
spiral lamina, 388.
stria vascularis, 390.
sulcus spiralis, 391.
tympanic cavity, 380.
tympanic membrane, 378.
tympanum, lymphatics of, 379.
tympanum, nerves of, 379.
utricle, 383.
Ear-stones, 385.
Ectoderm, 24.
derivatives of, 25.
Elastic tissue, 42.
Elastin, 40.
Eleidin, 272.
Elementary tissues, 11.
Embedding, interstitial, 414.
simple, 414.
Embryonal cell, 11.
Endochondral formation of bone, 52.
Endogenous cell-division, 20.
Endothelium, 33.
development of, 34.
stomata of, 33.
Entoderm, 24.
derivatives of, 25.
Epididymis, 213.
development of, 243.
globus major of, 208, 212.
tube of, 213.
Epidural spaces, 282.
Epiglottis, 248.
glands of, 248.
Epiphysis, 329.
Episcleral space, 372.
Epithelium, 26.
ciliated, 30.
classification of, 26.
columnar, 29
development of, 27, 34.
distribution of, 27.
germinal, of ovary, 224.
glandular, 31.
modified, 30.
of mucous membranes, 136.
Epithelium of sense-organs, 32.
pigmented, 31.
prickle-cells, 29.
rod, 32.
squamous, 27.
transitional, 29.
varieties of, 26.
Eponychium, 278.
Epoöphoron, 230.
Equatorial plate, 17.
Erythroblasts, 113.
Eustachian tube, 382.
Eye, 336.
anterior chamber of, 366.
blood-vessels of, 365.
canal of Petit, 366.
canal of Schlemm, 351.
capsule of Tenon, 366, 372.
choriocapillaris, 343.
choroid, 342.
choroidal fissure, 373.
ciliary body, 344.
ciliary muscle, 345.
ciliary processes, 344.
color of iris, 349.
conjunctiva, 369.
cornea, 336.
crystalline lens, 361.
development of, 372.
fovea centralis, 356.
hyaloid canal, 365.
hyaloid membrane, 364.
irido-corneal angle, 349.
iris, 346.
iris, color of, 349.
lachrymal canals, 371.
lachrymal caruncle, 370.
lachrymal gland, 371.
lamina cribrosa, 360.
lamina fusca, 341.
lamina suprachoroidea, 341.
ligamentum pectinatum iridis, 350
lymphatics of, 366.
macula lutea, 356.
membrana nictitans, 370.
naso-lachrymal duct, 371.
nerves of, 367.
optic nerve, 358.
optic nerve, excavation of, 360.
optic nerve, sheaths of, 359.
optic vesicle, 372.
ora serrata, 357.
perichoroidal space, 366.
plica semilunaris, 370.
retina, 351.
retina, morphology of, 351.
retina, pigment-layer of, 356.
retina, visual cells of, 354.
sclera, 341.
spaces of Fontana, 350
suspensory ligament of lens, 363.
tapetum cellulosum, 343.
tapetum fibrosum, 343.
Tenon's space, 366.
venæ vorticosæ, 343, 366.

Eye, vitreous body, 364.
vitreous lamina, 344.
zone of Zinn, 363.
Eyelids, 367.
blood-vessels of, 370.
development of, 376.
glands of Moll, 370.
lymphatics, 370.
Meibomian glands, 369.
nerves of, 371.
tarsus, 368.

F.

Fallopian tube, 230.
Fat, 43.
Fat-cells, 43.
Female pronucleus, 22.
Fenestrated membrane of Henle, 95.
Finishing and storing preparations, 423.
Fixation of tissues, 408.
Fixing sections to the slide, 420.
Flemming's solution, 409.
Foramen cæcum, 257.

G.

Galactophorous ducts, 240.
Gall-bladder, 182.
Ganglia, structure of, 80.
Gartner's duct, 230.
Genitalia, female, 236.
Germ-cells of neural tube, 333.
Germinal epithelium, 224.
spot, 227.
vesicle, 227.
Giraldès's organ, 214.
Glands, 137.
arterial, 114.
Bartholin's, 237.
blood-vessels of, 141.
Brunner's, 171.
carotid, 114.
coccygeal, 114.
compound saccular, 138.
compound tubular, 137.
Cowper's, 222.
development of, 142.
epithelium of, 32.
hemolymph, 122.
lachrymal, 371.
Lieberkühn's, 170.
Littré's, 203.
lymphatics of, 142.
Moll's, 370.
Montgomery's, 240.
mucous, 140.
Naboth's, 233.
nerves of, 142.
racemose, 138.
secreting cells of, 141.
serous, 140.
simple saccular, 138.
simple tubular, 137.
solitary, 172.
structure of, 138.
Tyson's, 219.
unicellular, 137.
Glands, varieties of, 137.
Golgi's gold method, 427.
silver method, 426.
Graafian follicles, 226.
number of, 228.
Grandry's tactile corpuscles, 84.
Granule-cells, 37.
Growth, 15.

H.

Hæmatoxylin staining, advantages of, 411
Weigert s method, 425.
Hair, 268.
color of, 269.
development of, 279.
lanugo, 280.
race peculiarities of, 267.
renewal of, 280.
structure of, 268
Hair-follicles, 269.
root-sheaths of, 270.
structure of, 271.
Hassall's corpuscles of thymus, 128.
Haversian canals, 48.
Heart, 100.
annuli fibrosi, 101.
blood-vessels of, 102.
chordæ tendineæ, 101.
corpus Arantii, 101.
development of, 104.
endocardium, 100.
fibres of Purkinje, 101.
lymphatics of, 103.
muscular tissue of, 102.
nerves of, 103.
pericardium, 102.
structure of, 100.
Hemolymph glands, 122.
Howship's lacunæ, 56.
Hyaloplasm, 13.
Hydatid, sessile, 244
stalked, of Morgagni, 230.
Hypophysis cerebri, 328.

I.

Indirect cell-division, 16.
Injecting capillary blood-vessels, 429.
Internal capsule, 327.
Intestines, 168.
agminated glands, 173.
blood-vessels of, 175.
Brunner's glands of, 171.
chyle vessels of, 169.
duodenal glands of, 171.
glands of, 170.
goblet-cells of, 169.
Lieberkühn's follicles of, 170.
lymphatics of, 175.
mucosa of large, 169.
mucosa of small, 168.
muscular coat of, 174.
muscular coat of large, 174.
muscularis mucosæ of, 174.
nerves of, 176.
Peyer's patches, 173.
solitary glands of, 172.

Intestines, submucosa of, 174.
valvulæ conniventes, 168.
villi of, 168, 169.

K.

Karyokinesis, 15.
Kidney, 191.
blood-vessels of, 199.
Bowman's capsule, 193.
capsule of, 193.
columns of Bertini, 192.
connective tissue of, 193.
development of, 204.
divisions of, 191.
glomeruli of, 193.
Henle's loops, 195.
labyrinth of, 192.
lobules of, 191.
lymphatics of, 200.
Malpighian bodies, 193.
Malpighian pyramids, 192.
Malpighian tuft, 193.
medulla of, 192.
medullary rays, 192.
nerves of, 200.
papillæ of, 191.
pelvis of, 201.
sinus of, 201.
tubes of Bellini, 195.
uriniferous tubules of, 195, 196.
Kleinenberg's solution, 410.
Krause's views regarding muscle, 63.

L.

Labia majora, 236.
minora, 236.
Lachrymal canals, 371.
gland, 371.
Lanugo, 280.
Larynx, 246.
blood-vessels of, 248.
cartilages of, 248.
lymphatics of, 248.
nerves of, 248.
vocal cords of, 246.
Leucocytes, 105.
Lieberkühn's follicles, 170.
Ligamentum nuchæ, 42.
Liver, 176.
bile-capillaries of, 178, 179.
bile-ducts of, 180.
blood-vessels of, 181.
cells of, 178.
development of, 189.
fibrous tissue of, 176.
glands of bile-ducts, 181.
Glisson's capsule, 176.
interlobular vessels of, 177.
intralobular capillary net-work, 177.
lymphatics of, 181.
multinucleated cells of, 189.
nerves of, 182.
perivascular lymphatics of, 179.
Lung, 252.
air-sacs, 252.
Lung, alveolar passages, 251.
blood-vessels of, 254.
connective tissue of, 254.
development, 259.
infundibula, 251.
lobules of, 252.
lymphatics of, 255.
nerves of, 255.
pigment within, 254.
terminal bronchus, 251.
Lunula of nail, 265.
Luschka's gland, 114.
Lymph, 117.
capillaries, 116.
corpuscles, 117.
corpuscles, sources of, 118.
perineurial channels, 117.
perivascular sheaths, 117.
Lymphatic glands, 119.
blood-vessels of, 120.
compound, 120.
simple, 119.
spaces, 115.
system, 115.
system, development of, 133.
tissues, 118.
tissues, diffuse, 119.
tissues, elements of, 118.
vessels, 117.

M.

Male pronucleus, 23.
Mammary glands, 238.
ampullæ, 240.
areola, 240.
blood-vessels, 241.
during lactation, 230.
galactophorous ducts, 240.
lymphatics, 241.
nerves, 241.
nipple, 240.
rudimentary, 241.
Maturation of ovum, 22.
Medulla, 295.
anterior pyramid, 300.
arcuate fibres, 298, 299.
clavus, 296.
corpus dentatum of olive, 299.
cuneate tubercle, 296.
decussation of anterior pyramids, 297.
external cuneate nucleus, 297.
fibre-tracts of, 300.
formatio reticularis, 298.
funiculus Rolandi, 296.
funiculus teres, 297.
hypoglossal nucleus, 297.
lateral tract, 300.
nucleus cuneatus, 296.
nucleus gracilis, 296.
nucleus lateralis, 297.
posterior pyramid, 301.
restiform body, 300.
spinalis, 284.
Meissner's tactile corpuscles, 85.
Melanin, 38.

Membrana nictitans, 370.
propria of mucous membranes, 137.
Membrane of Descemet, 339.
Merkel's tactile corpuscles, 84.
Mesoderm, 24.
derivatives of, 25.
Mesogastrium, 190.
Mesothelium, 133.
Metabolism, 15.
Metakinesis, 18.
Microcytes of blood, 111.
Milk, 241.
colostrum corpuscles, 242.
secretion of, 239.
Mitotic cell-division, 16.
Mounting sections, 422.
Mouth, 144.
blood-vessels of, 145
lymphatics of, 145.
mucous membrane of, 144.
nerves of, 145.
Mucous membranes, structure of, 136.
Muscle, 58.
blood-vessels of, 67.
cardiac, 66.
development of, 67.
involuntary, 59.
nerves of, 67.
non-striped, distribution of, 58
striped, 61.
voluntary, 61.
Müllerian duct, 242.
Müller's fibres of retina, 352.
Müller's fluid, 408.
Myeloplaxes of Robin, 51.

N.

Nails, 265.
development of, 278.
growth of, 278.
lunula, 279.
regeneration of, 279.
structure of, 266.
Nasal mucous membrane, 402.
blood-vessels of, 404.
Bowman's glands, 404.
development of, 405.
glands of, 402.
lymphatics of, 405.
nerves of, 405.
olfactory division of, 403.
olfactory epithelium, 404.
respiratory division of, 402.
Nasmyth's membrane, 148.
Naso-lachrymal duct, 371.
Nebenkern, 14.
Nephrostomata, 197.
Nerve-cells, 69.
of first type, 70.
of second type, 71.
processes of, 70.
Nerve-endings, 83.
classification of, 88.
cylindrical end-bulbs, 86.
in blood-vessels, 92.
Nerve-endings in glands, 92.
in non-striated muscle, 89.
in striated muscle, 90.
muscle-spindles, 91.
of Langerhans, 84.
sensory, 83.
spherical end-bulbs, 85.
tactile cells, 84.
tendon spindles, 92.
Nerve-fibres, 72.
medullated, 73.
non-medullated, 74.
of spinal cord, 288.
Nerve-trunks, 77.
blood-vessels of, 78.
endoneurium, 77.
epineurium, 78.
funiculus, 77.
Henle's sheath of, 78.
lymphatics of, 78.
nerves of, 78.
perineurium, 77.
Nervi nervorum, 78.
Nervous system, 282.
Nervous tissues, 69.
development of, 81.
supporting framework of, 99.
Neuroblasts, 81, 333.
Neuro-epithelium, 93.
Neuroglia, 79.
cells, 79.
Nipple, 240.
Nucleolus, 14.
Nucleus, 13.
caudatus, 319.
fibrils of, 13.
lenticularis, 320.
membrane of, 13.
segmentation, 23.
structure of, 13.
Nymphæ, 236.

O

Œsophagus, 160.
muscular tissue of, 161.
Olfactory bulb, 324.
glomeruli, 325.
lobe, 323.
tract, 323.
Optic thalamus, 320.
Organ of Rosenmüller, 230.
Ovary, 224.
blood-vessels, 229.
corpus luteum of pregnancy, 229.
development of, 244.
germinal epithelium, 224.
interstitial cells, 228.
lymphatics of, 229.
nerves of, 229.
primary egg-tubes, 244.
primordial ova, 244.
stroma, 225.
tunica albuginea, 225.
Oviduct, 230.
Ovula Nabothi, 233.

Ovum, 227.
escape of, 228.
germinal spot, 227.
germinal vesicle, 227.
maturation, 22.
segmentation of, 23.

P.

Pacchionian bodies, 283.
Pacinian corpuscles, 86.
Pancreas, 185.
development of, 189.
Panniculus adiposus, 265.
Paradidymis, 214.
development of, 243.
Paranucleus, 14.
Parasinoidal spaces, 282.
Paroöphoron, 245.
development of, 245.
Parovarium, 230.
development of, 244.
Peduncular fibres, 327.
Penis, 216.
arteries of, 218.
cavernous venous channels of, 217.
corpora cavernosa, 216.
corpus spongiosum, 218.
erectile tissue of, 218.
glands of Tyson, 219.
helicine arteries of, 218.
lymphatics of, 219.
nerves of, 219.
Perichondrium, 45.
Peronyx, 278.
Periosteal bone, 54.
Peripheral nerve-endings, 83.
Peyer's patches, 173.
Phagocytes, 106.
Pharynx, 159.
glands of, 159.
mucous membrane of, 159.
Pia mater, 283.
pigment-cells of, 284.
Picro-sulphuric acid solution, 410.
Pigment-cells, 37.
Pigment of hair, 269.
of skin, 263.
Pineal body, 329.
eye, 329.
Pituitary body, 328.
Plasma-cells of Waldeyer, 36.
Plastin, 13.
Pleura, 256.
blood-vessels of, 256.
nerves of, 256.
Plexus of Auerbach, 167.
of Meissner, 167.
Polar bodies, 22.
field, 16.
Pole-corpuscle, 14.
Pons, 301.
locus cœruleus, 302.
nuclei of, 301.
posterior longitudinal bundle, 302.
substantia ferruginea, 302.
Preparation of tissues, order of manipulations, 407.
Preservation of tissues, 410.
Primary body-cavity, 133.
neural tube, 332.
Primordial ova, 244.
sexual cells, 243.
Projection fibres, 327.
Pronucleus, female, 22
male, 23.
Prostate gland, 219.
acini of, 220.
amyloid concretions of, 216.
blood-vessels of, 222.
concretions of, 222.
involuntary muscle of, 220.
lymphatics of, 222.
nerves of, 222.
secretion of, 222.
Prostatic crystals, 216.
sinus, 221.
Protoplasm, reticulation of, 17
structure of, 12.
Purkinje's ganglion-cells, 308.
basket-works of, 310.

R.

Reissner's membrane, 389.
Reproduction of the cell, 15.
Reproductive organs, table of homologies of, 245
Respiratory organs, 246.
Rete Malpighii, 262.
Ribbon sections, 420.
Rollett's views regarding muscle, 63.
Root-sheaths of hair-follicle, 271

S.

Saffranin staining, 428.
Salivary corpuscles, 156.
Sebaceous glands, 273.
Sebum, 273.
Section-cutting, 418.
Segmentation nucleus, 23.
Segmentation of ovum, 23.
Semen, 273.
Serous membranes, 128.
blood-vessels of, 130.
classification of, 128.
development of, 133.
ground-substance of, 130.
nerves of, 131.
structure of, 129.
Sexual cords, 243.
glands, indifferent, 243.
Sharpey's fibres of bone, 50.
Silver staining, 427
Sinus pocularis, 221, 244.
Skin, 261.
arrector pili, 272.
blood-vessels of, 276.
corium, 264.
development of, 277.
eleidin granules, 263.
epidermis, 262.
epitrichial layer, 263.

Skin, hair-follicles, 269.
hair-papillæ, 272.
lymphatics of, 276.
muscles of, 272.
nerves of, 277.
panniculus adiposus, 265.
papillæ of, 264.
pigment of, 263.
sebaceous glands, 273.
stratum corneum, 263.
stratum granulosum, 263.
stratum lucidum, 263.
stratum Malpighii, 263.
structure of hairs. 268.
sweat-glands, 273.
Somatopleure, 133.
Spaces of Fontana, 350.
Spermatic crystals, 216.
duct, 213.
Spermatozoa, 215.
vibrations of, 215.
Spinal cord, 284.
anterior column, 285.
anterior gray commissure, 290.
anterior ground-bundle, 286.
anterior median fissure, 285.
anterior radicular zone, 286.
ascending antero-lateral, 286.
blood-vessels of, 294.
Burdach's column, 286.
central canal of, 293.
Clarke's column, 290.
connective tissue, framework of, 287.
crossed pyramidal tract, 286.
descending antero-lateral, 286.
direct cerebellar tract, 286.
direct pyramidal tract, 286.
ependyma of, 293.
filum terminale, 285.
ganglion-cells, 290.
Goll's column, 286.
Gowers's tract, 286.
gray commissure, 285.
gray matter, arrangement of, 288.
lateral column, 286.
mixed lateral tract, 286.
neuroglia of, 287.
outlying ganglion-cells, 291.
posterior column, 285.
posterior median fissure, 285.
structure of gray matter, 290, 291.
substantia gelatinosa, 293.
substantia gelatinosa Rolandi, 293.
substantia spongiosa of, 291.
Türck's column, 286.
ventriculus terminalis, 294.
white commissure, 288.
white matter of, 287.
Spirem, 16.
Splanchnopleure, 133.
Spleen, 122.
blood-vessels of, 125.
development of, 134.
lymphatics of, 126.
Malpighian corpuscles of, 124.
Spleen, nerves of, 126.
pulp-tissue of, 124.
Spongioblasts, 81, 333.
Spongioplasm, 12.
Staining, 411.
chromatin figures, 428.
Standard technique, outline of, 423.
Stomach, 162.
acid cells of, 163.
blood-vessels of, 166.
development of, 187.
lymphatics of, 167.
mucous membrane of, 162.
muscular coat of, 166
nerves of, 167,
peptic glands, 162.
pyloric glands of, 164.
serous coat of, 166.
submucosa of, 165.
Stratum Malpighii, 263.
Subarachnoidean space, 283.
Substantia gelatinosa of spinal cord, 293.
Substantia spongiosa of spinal cord, 291.
Suprarenal body, 330.
Sweat-glands, 273.
muscle of, 275.
number of, 275.
secretion of, 275.
Synovial membranes, 131.
blood-vessels of, 132.
Haversian fringes of, 132.
nerves of, 132.
structure of, 131.

T.

Tapetum cellulosum of choroid, 343.
Tapetum fibrosum of choroid, 343.
Taste-buds, 155.
Teeth, 145.
cementum, 148.
crusta petrosa, 148.
dental papilla, 150.
dentinal fibres, 147.
dentinal tubules, 146.
dentine, 146.
development of, 149.
enamel, 147.
enamel organ, 150.
incremental lines of Salter, 147.
interglobular spaces, 146.
membrane of Nasmyth, 148.
odontoblasts, 152.
pulp, 148.
Schrager's lines, 147.
stripes of Retzius, 148.
Tegmentum of cerebral peduncles, 328.
Tendon, structure of, 41.
Tendon-cells, 41.
Tenon's capsule, 372.
Testicle, 207.
blood-vessels of, 214.
coni vasculosi, 208, 213.
development of, 243.
hydatids of, 214.
interstitial cells, 212.

Testicle, lymphatics of, 214.
mediastinum of, 207.
nerves of, 214.
seminiferous tubules, 208.
Sertoli's columns, 209.
spermatoblasts, 209.
spermatogenesis, 210.
straight tubules, 212.
tunica albuginea, 207.
tunica vaginalis, 207.
vasa efferentia, 208, 213.
Thymus body, 126.
blood-vessels of, 128.
corpuscles of Hassall, 128.
development of, 134.
lymphatics of, 128.
nerves of, 128.
Thyro-glossal duct, 257.
Thyroid body, 257.
colloid secretion of, 258.
development of, 260.
Tissues, constituents of, 11.
elements of, 23.
Tongue, 153.
blood-vessels of, 156.
glands of, 156.
lymphatics of, 156.
mucous membrane of, 152.
nerves of, 156.
papillæ of, 153.
Tonsils, 158.
Trachea, 249.
blood-vessels of, 250.
cartilages of, 249.
glands of, 249.
lymphatics of, 250.
nerves of, 250.
Tunica propria of mucous membranes, 136.

U.

Ureter, 201.
development of, 204.
Urethra, 203.
development of, 206.
female, 203, 237.
glands of, 203, 238.
male, 203.
Urinary bladder, 202.
development of, 206.
Uterus, 232.
blood-vessels of, 234.
cervix, 232.
development of, 244.
menstrual changes, 233.
muscular coat of, 234.
Uterus masculinus, 221, 244.

V.

Vagina, 235.
development of, 244.
Vas deferens, 213.
ampullæ of, 213.
Vasa vasorum, 99.
Veins, 97.
adventitia of, 98.
intima of, 97.
media of, 98.
valves of, 98.
variations in coats of, 98.
Vital manifestations of the cell, 15.
Vitelline membrane, 227.
Vitellus, 227.
Vocal cords, 246.

W.

Wandering cells of connective tissue, 36.
Weigert's staining method, 425.
White fibrous tissue, 39.
Wolffian body, 204, 242.
Wolffian duct, 204, 242.
Wolffian tubules, 242.

Y.

Yellow elastic tissue, 39.

THE END.

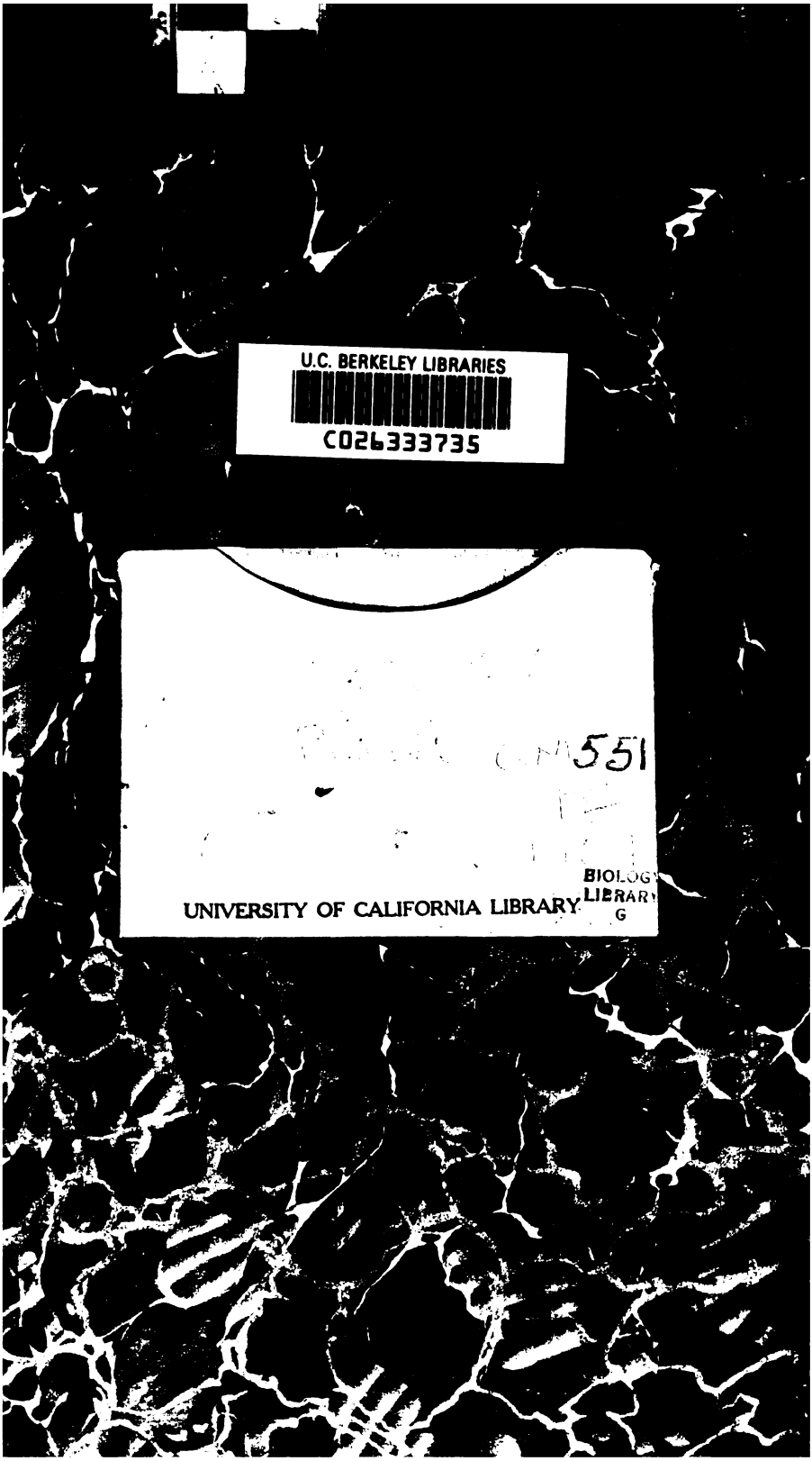
U.C. BERKELEY LIBRARIES
C026333735
551
UNIVERSITY OF CALIFORNIA LIBRARY
BIOLOG
LIBRARY
G